

CASE REPORT

Nagoya J. Med. Sci. 79, 91 ~ 95, 2017
doi:10.18999/nagjms.79.1.91

Cervical chyloma after neck dissection: a case report

Masashi Kimura, Hiroyuki Ohto, Akio Shibata, Hiroki Yamada, Shusuke Nishiwaki
and Masahiro Umemura

Department of Oral and Maxillofacial Surgery, Ogaki Municipal Hospital, Ogaki, Japan

ABSTRACT

Cervical chylomas are rare pseudocystic collections that lack an epithelial lining and arise from the thoracic duct or its tributaries; although they typically develop after neck surgery or trauma, they can arise from unknown causes. Treatment options include not only conservative therapy, such as dietary modification, repeated aspirations, and sclerotherapy, but also include surgical excision. We describe a case of a chyloma in a 64-year-old Japanese woman with squamous cell carcinoma of the gingiva. The chyloma developed following left segmental mandibulectomy with radical neck dissection and reconstruction, using a titanium plate and a pectoralis major myocutaneous flap. One month after surgery, a left supraclavicular swelling was noted, so ultrasound-guided fine-needle aspiration and cytology were performed to exclude a recurrence of neck metastasis. The aspiration yielded a milky fluid without atypical or malignant cells on cytology, confirming the diagnosis of chyloma. Although we performed continuous compressive dressing and started the patient on a low-fat diet, the mass persisted. When the patient died of bone, lung, and liver metastases five months after the second surgery, the mass had not changed in size. Awareness of this complication is important to ensure timely diagnosis and appropriate treatment.

Key Words: cervical chyloma, lymphocele, conservative therapy, thoracic duct

This is an Open Access article distributed under the Creative Commons Attribution-NonCommercial-NoDerivatives 4.0 International License. To view the details of this license, please visit (<http://creativecommons.org/licenses/by-nc-nd/4.0/>).

INTRODUCTION

Although postoperative leaks of the thoracic duct are a well-known complication of neck dissection, the development of postoperative chyloma is extremely rare. To the best of our knowledge, only nine cases of a cervical chyloma following neck dissection have been previously reported (Table 1).¹⁻⁵⁾ Chylomas are pseudocystic collections arising from the thoracic duct or its tributaries and are defined as a circumscribed collection of protein-rich lymphatic fluid without an endothelial lining; although they typically occur following surgery or trauma, they are also reported to arise from unknown causes.¹⁾⁻⁹⁾ A recent report showed that management options included dietary modification, repeated aspirations, sclerotherapy, and surgical excision.⁶⁾ Here, we report a case of chyloma following neck dissection.

Received: December 22, 2016; accepted: January 5, 2017

Corresponding author: Masashi Kimura, DDS, PhD

Department of Oral and Maxillofacial Surgery, Ogaki Municipal Hospital, 4-86 Minaminokawa, Ogaki, Gifu 503-8502, Japan

Tel: +81-584-81-3341, Fax: +81-584-75-5715, E-mail address: masashi9@dpc.agu.ac.jp

Table 1 Summary of patients with cervical chyloma after neck dissection

Author	Year	Age	Sex	Primary tumor	Type of neck dissection	Onset	Side	Size	Treatment	Duration of therapy	Results
Chantarasak <i>et al.</i> ⁽¹⁾	1989	78	F	Squamous cell carcinoma overlying the angle of the left mandible	RND	3 months	Left	6 cm	Surgical exploration	3 days	Cured
Nouwen <i>et al.</i> ⁽²⁾	2004	24	F	Papillary carcinoma of the thyroid gland	MRND	6 days	Left	8 cm	Surgical exploration	6 days	Cured
Roh and Park ⁽³⁾	2008	58	M	Esophageal cancer	MRND	3 weeks	Left	50 mL*	OK-432 sclerotherapy	2 weeks	Cured
	2008	59	F	Thyroid cancer	MRND, CND	3 weeks	Left	45 mL*	OK-432 sclerotherapy	2 weeks	Cured
	2008	65	M	Hypopharyngeal cancer	RND	12 months	Right	30 mL*	OK-432 sclerotherapy	2 months	Cured
	2008	70	M	Unknown	MRND	9 months	Right	10 mL*	OK-432 sclerotherapy	2 weeks	Cured
Al-Suqri and Dutton ⁽⁴⁾	2012	37	F	Papillary carcinoma of the thyroid gland	Unknown	a few days	Left	Unknown	Surgical exploration	Unknown	Cured
Thiagarajan <i>et al.</i> ⁽⁵⁾	2012	65	M	Papillary carcinoma of the thyroid gland	MRND	8 days	Left	6 × 7 cm	Surgical exploration	Unknown	Cured
	2012	62	M	Papillary carcinoma of the thyroid gland	MRND	4 days	Left	Unknown	Surgical exploration	Unknown	Chyle leak persisted
Present case	2016	64	F	Squamous cell carcinoma of the gingiva	RND	1 month	Left	3 × 3 cm	Conservative therapy	–	No change

F = female; M = male; RND = radical neck dissection; MRND = modified radical neck dissection; CND = central neck dissection. *Volume of aspirated fluid

CASE REPORT

A 64-year-old Japanese woman consulted our hospital because of a swelling in the left mandibular gum. Intraoral examination revealed a reddish ulcerative lesion around the buccal area of the lower first and second molars. Her medical history was positive for hyperthyroidism and dilated cardiomyopathy. The lesion was provisionally diagnosed as a non-healing ulcer but with a differential diagnosis that included squamous cell carcinoma (SCC). Thus, a biopsy was performed under local anesthesia on the same day. The biopsy specimen revealed moderately differentiated SCC. Subsequently, 18F-fluorodeoxyglucose positron emission tomography (FDG-PET) computed tomography (CT) and contrast-enhanced CT scans were performed, and the lesion was classified as T3N0M0 (stage III), according to the oral cancer TNM classification criteria of the UICC/AJC (American Joint Committee for Cancer Staging).

Marginal mandibulectomy was performed with curative intent under general anesthesia. However, two months after surgery, there was local recurrence with multiple neck metastases. The patient was then treated with induction chemotherapy by docetaxel (60 mg/m², Day 1), cisplatin (60 mg/m², Day 1), and 5-fluorouracil (750 mg, days 1–4). After three cycles of chemotherapy,

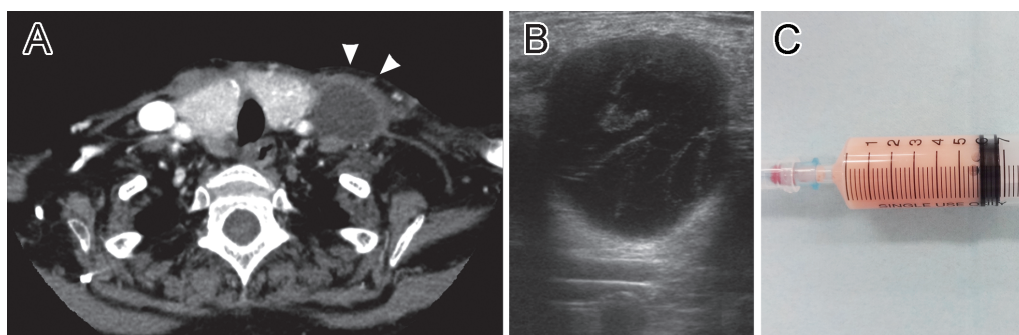


Fig. 1 (A) Computed tomography with contrast enhancement showing a 3 × 3 cm solitary mass in the left supraclavicular region (arrowheads). (B) Ultrasonography of the lesion showing a round, circumscribed, and anechoic fluid collection with thin septations. (C) The aspiration yielded 6 mL of milky fluid.

we performed segmental mandibulectomy with radical neck dissection and reconstruction using a titanium plate and a pectoralis major myocutaneous flap. Histopathological examination of the resected specimen showed a moderately differentiated SCC with multiple nodal metastases (level IA, IB, IIA, III, IV, VA, and VB). Further examination indicated that 21 of these nodal metastases had extracapsular spread. Thus, postoperative treatment was planned with cetuximab and radiation.

By one month after surgery, a left supraclavicular swelling was noted. Contrast-enhanced CT of the neck revealed a 3 × 3 cm solitary mass (Figure 1A), so we performed ultrasound-guided fine-needle aspiration and cytological examination to exclude recurrence of neck metastasis. Ultrasonography (US) of the lesion showed a round, circumscribed, and anechoic fluid-filled collection with thin septations (Figure 1B). Aspiration of the mass yielded 6 mL of milky fluid (Figure 1C), and cytological examination revealed no atypical or malignant cells. Based on these findings, it was thought that the origin was chylous, and a diagnosis of cervical chyloma was established. In the first instance, we provided treatment with continuous compressive dressings using an elastic tape and a low-fat diet, but soon resumed cetuximab-based chemoradiotherapy. Unfortunately, our efforts to treat the mass were unsuccessful. We thought that the elastic tape used with the compressive dressing has the potential to worsen the radiation dermatitis at the site. For this reason, we stopped applying the compressive dressings.

The patient eventually died of bone, lung, and liver metastases five months after second surgery, but there was no change in the size of the mass during that time.

DISCUSSION

The thoracic duct drains lymph from most of the body, as well as chyle from the gut, but the duct's termination in the venous system is extremely variable. A recent cadaveric study showed that the termination of the thoracic duct was at the confluence of the left internal jugular and left subclavian veins in 60% of cases, directly at the left internal jugular vein in 36% of cases, and at the left vertebral vein in 4% of cases.¹⁰ Furthermore, its thin transparent walls can make it difficult to recognize the thoracic ductal system.¹¹

In 1%–6% of cases, injury to the thoracic duct can occur while dissecting the lower part of the internal jugular vein, with most injuries being on the left side.¹² Thoracic duct injury can result in chyle leaks, which can manifest as chylous fistulae, chylothoraces, or rarely, cervical chylomas. Although thoracic duct injury is uncommon after neck dissection, it is a significant

complication. Indeed, the accumulation of lymph in a wound can lead to electrolyte imbalance and protein loss, as well as to problems with local wound healing.³⁾ As a result, it can prolong the hospitalization.

To prevent chylous fistulae, chylothoraces, and cervical chylomas, the operator is required to have a thorough knowledge of the normal anatomy of the thoracic duct and surrounding structures as well as their multiple variants. The thoracic duct should be meticulously identified, carefully dissected, divided, and ligated.¹³⁾ However, we could not identify the thoracic duct in the vicinity of the jugular vein. Consequently, all lymphatic vessels together with all fatty tissues located in this area were ligated without identifying the thoracic duct. We thought that the cause of a cervical chyloma is these procedures. If thoracic duct injury is suspected during an operation, it requires lowering the patient's head and performing the Valsalva maneuver with direct inspection to check for chyle leak.^{14, 15)} Once the site of the leak has been identified, the duct should be ligated or the adjacent fascia plicated over the duct.¹⁵⁾

Establishing the diagnosis of a cervical chyloma requires determining that the cyst fluid is chylous as no specific diagnostic criteria have been established to date.^{6, 8)} Imaging methods, including contrast-enhanced CT and magnetic resonance imaging, are useful in distinguishing cystic masses from solid masses.⁶⁾ In addition, such imaging methods are useful to help identify the extension of the mass in relation to the surrounding structures.⁶⁾ However, fine-needle aspiration is the key for making a precise diagnosis as it reveals the pathognomonic hallmark of milky fluid with a high fat content.²⁾

The treatment of cervical chylomas has been adapted from knowledge on the management of chylous fistulae and other cystic lesions in the neck and elsewhere. The current algorithm for the management of such lesions indicates that conservative approaches should be initially attempted. These include commencing patients on a medium-chain triglyceride diet, ensuring head elevation, applying external compression, and repeating fine-needle aspiration as needed.⁶⁾ In patients who do not respond to simple conservative therapies, the instillation of sclerosing agents, such as OK-432,³⁾ doxycycline,¹⁶⁾ talc,¹⁷⁾ or a diluted solution of povidone-iodine,¹⁴⁾ can be considered. When these measures fail, surgical intervention, which has been reported to be effective and reliable, can be used as an alternative to sclerotherapy.⁶⁾

In our case, none of the conservative measures was effective. Moreover, we had to resume postoperative chemoradiotherapy early in an attempt to prevent tumor progression. Although we stopped the application of continuous compressive dressings for these reasons, it is noteworthy that no complications appeared in the five months after the surgery. These findings suggest that treatment should be selected according to the condition of the patient and the specific characteristics of the lesion. Furthermore, we thought that postoperative treatment such as chemotherapy and radiotherapy should be prior to the treatment of a chyloma, if the chyloma showed any other complications. In particular, surgical intervention should be avoided in these cases. There can be a significant risk to vascular, neurological, and pulmonary structures. Furthermore, it may delay the start of postoperative therapy. For these reasons, we recommend to selecting conservative therapy for such cases.

CONCLUSION

In this report, we described a rare case of cervical chyloma following radical neck dissection. Although several options are available for the management of such lesions, treatment should be selected based on the condition of the patient and the characteristics of the specific lesion.

CONFLICT OF INTEREST

The authors have no conflict of interest to declare.

REFERENCES

- 1) Chantarasak DN, Green MF. Delayed lymphocele following neck dissection. *Br J Plast Surg*, 1989; 42: 339–340.
- 2) Nouwen J, Hans S, Halimi P, Laccourreye O. Lymphocele after neck dissection. *Ann Otol Rhinol Laryngol*, 2004; 113: 39–42.
- 3) Roh JL, Park CI. OK-432 sclerotherapy of cervical chylous lymphocele after neck dissection. *Laryngoscope*, 2008; 118: 999–1002.
- 4) Al-Suqri B, Dutton J. Iatrogenic chyloma in the neck: lymphoscintigraphic findings. *Clin Nucl Med*, 2012; 37: 1126–1128.
- 5) Thiagarajan S, Shenoy AM, Veerabadraiah P, Chavan P, Halkud R. Massive Chylorrhea following Total Thyroidectomy and Neck Dissection. *Int J Head Neck Surg*, 2012; 3: 45–48.
- 6) Abdul-Aziz D, Tierney HT, Deschler DG. Surgical management of cervical chyloma following parathyroidectomy. *Auris Nasus Larynx*, 2011; 38: 528–531.
- 7) Sinclair D, Woods E, Saibil EA, Taylor GA. 'Chyloma': a persistent post-traumatic collection in the left supraclavicular region. *J Trauma*, 1987; 27: 567–569.
- 8) Madnani D, Myssiorek D. Left cervical chyloma following right thyroidectomy. *Ear Nose Throat J*, 2003; 82: 522–524.
- 9) Hekiert A, Newman J, Sargent R, Weinstein G. Spontaneous cervical lymphocele. *Head Neck*, 2007; 29: 77–80.
- 10) Louzada AC, Lim SJ, Pallazzo JF, Silva VP, de Oliveira RV, Yoshio AM, et al. Biometric measurements involving the terminal portion of the thoracic duct on left cervical level IV: an anatomic study. *Anat Sci Int*, 2016; 91: 274–279.
- 11) de Gier HH, Balm AJ, Bruning PF, Gregor RT, Hilgers FJ. Systematic approach to the treatment of chylous leakage after neck dissection. *Head Neck*, 1996; 18: 347–351.
- 12) Gregor RT. Management of chyle fistulization in association with neck dissection. *Otolaryngol Head Neck Surg*, 2000; 122: 434–439.
- 13) Shah JP. Head and neck surgery and oncology. Third ed. pp. 384, 2003, Elsevier, Philadelphia.
- 14) Seelig MH, Klingler PJ, Oldenburg WA. Treatment of a postoperative cervical chylous lymphocele by percutaneous sclerosing with povidone-iodine. *J Vasc Surg*, 1998; 27: 1148–1151.
- 15) Cherian A. Management of Chyle Leak in the Neck Following Thyroid Cancer Surgery: A Single Center Experience. *World*, 2015; 7: 6–9.
- 16) Kirse DJ, Stern SJ, Suen JY, Rudnicki S, Roberson PK, Schaefer RF. Neurotoxic effects of doxycycline sclerotherapy. *Otolaryngol Head Neck Surg*, 1998; 118: 356–362.
- 17) Qureishi A, Silva P, Lamyman A, Cox G. Cervical lymphocele: a simple solution for a complicated problem. *Ann R Coll Surg Engl*, 2012; 94: e79–80.