

A CASE OF UNILATERAL GIANT HYDRONEPHROSIS WITH RENAL INSUFFICIENCY

MASANORI YAMAMOTO, HATSUKI HIBI and KOJI MIYAKE

Department of Urology, Nagoya University School of Medicine, Nagoya, Japan

ABSTRACT

Giant hydronephrosis, which is a symptomless enlargement of the abdomen, is an extremely rare condition in adults, with most cases being discovered in young-to-middle-aged people. We report a case of adult giant hydronephrosis accompanied by renal insufficiency, in which surgical repair was not performed because of the patient's poor cardiac function. Nephrostomy was performed and was followed with replacement of the nephrostomy tube every 2 weeks. For diagnostic purposes, ultrasonography and computerized tomography were preferable. A supplementary antegrade and retrograde pyelography was valuable in locating the stenosis.

Key words: Giant hydronephrosis, Renal insufficiency

INTRODUCTION

Giant hydronephrosis in adults is an extremely rare clinical condition with few reported cases in the literature.¹⁾ The term giant hydronephrosis in adults is applied when the pelvis contains more than 1000 ml of fluid.²⁾ Crooks et al. proposed that giant hydronephrosis should be defined as a kidney occupying half the abdomen, which meets or crosses the midline and is at least 5 vertebrae in length.³⁾ We report on a 52-year-old man with unilateral giant hydronephrosis and concomitant renal insufficiency.

CASE REPORT

A 52-year-old man was referred and admitted to our hospital for evaluation of a large mass in the abdomen along with nausea, vomiting and abdominal pain, which had been occurring intermittently for 1 year. His blood urea nitrogen (BUN) and creatinine were 34 mg/dl and 2.4 mg/dl, respectively, indicating renal insufficiency. The urine volume per day was 2400 ml, and the creatinine clearance in urine collected over 24 h showed 14.9 ml/min. The patient's past history was unremarkable. He had been taking an antihypertensive drug for 3 years. The results of the ultrasound cardiography in the follow-up showed that the hypokinetic left ventricular wall motion and ejection fraction was 40%. We diagnosed him as having dilated cardiomyopathy. Although the patient complained of intermittent abdominal pain, the cardiologist did not perform an image study of the abdomen. Therefore, a diagnosis of hydronephrosis was delayed.

On physical examination, his blood pressure was 150/84 mmHg and his pulse was 70 regular beats/min. The abdomen was distended and a large tender mass could be palpated over the abdomen. It extended beyond the midline and to the iliac crest inferiorly. Laboratory studies

Correspondence: Masanori Yamamoto, M.D., Department of Urology, Nagoya University School of Medicine, 65 Tsurumai-cho, Showa-ku, Nagoya, Japan

disclosed the following: hematocrit at 36.7%; RBC: 398×10^4 ; WBC: 6800; platelets: 270,000; normal prothrombin, partial thromboplastin, and bleeding times; Na: 140 mEq/l; K: 4.1 mEq/l; Cl: 103 mEq/l; and Ca: 9.1 mg/dl. Results of the liver function tests were normal. Urinalysis showed RBC: plenty/HPF; and WBC: 2–3/HPF. An abdomen radiography showed displacement of the stomach and intestine to the right side. Abdominal ultrasonography revealed a giant cystic mass. A computerized tomography scan disclosed a huge left hydronephrosis occupying most of the abdominal cavity (Fig. 1); the size and contour of the right kidney were normal. An intravenous pyelography was not performed because of the elevated creatinine. Thereafter, an ultrasound-guided left percutaneous nephrostomy was performed; approximately 3500 ml of clear urine was obtained. The nephrostogram suggested the possibility of hydronephrosis due to an obstruction of the ureteropelvic junction (Fig. 2). The patient did not, however agree to undergo a retrograde pyelography. The total renal function as evidenced by stable elevated serum creatinine did not improve 1 month after the nephrostomy. Daily urine output from the nephrostomy was almost 500 ml, but the creatinine clearance in urine from the left kidney was less than 10 ml/min. On the basis of least recoverability of the left renal function, we proposed a left nephrectomy. However, as the patient refused this procedure because of his poor cardiac function (ejection fraction: 40%), a course of replacement of the nephrostomy tube every 2 weeks at an outpatient clinic was chosen.

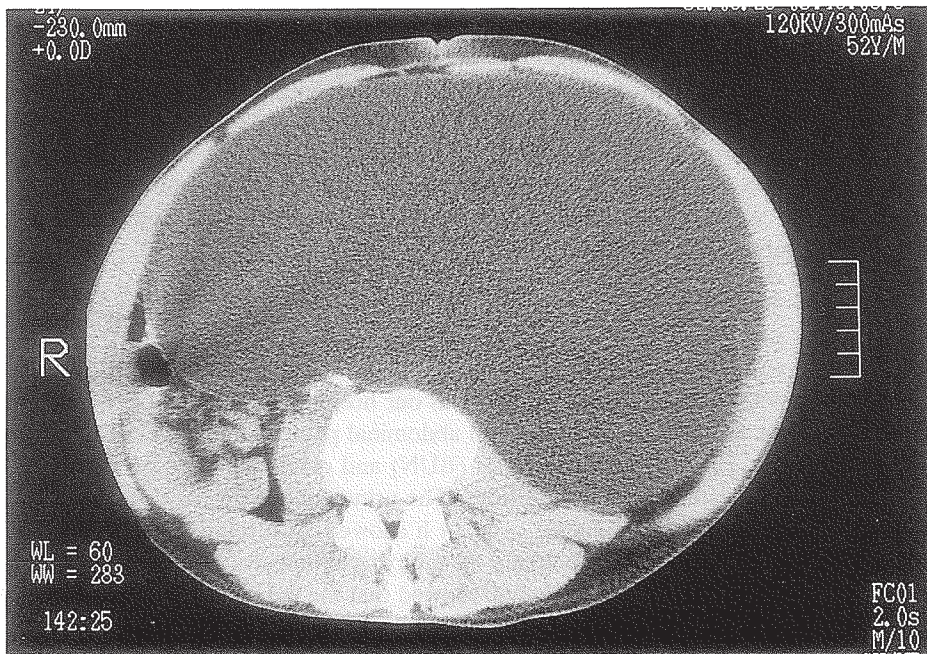


Fig. 1. CT scan shows giant hydronephrosis with the left hydronephrotic sac occupying the entire abdomen. Size and contour of the right kidney are normal.

GIANT HYDRONEPHROSIS

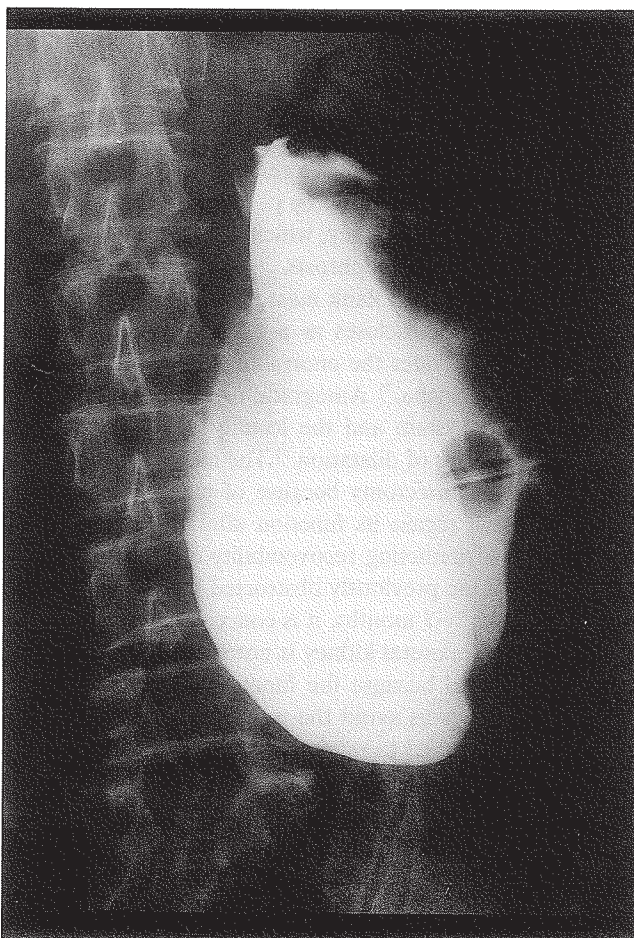


Fig. 2. Nephrostogram after decompression of giant hydronephrosis reveals complete obstruction of the ureteropelvic junction.

DISCUSSION

The true incidence of giant hydronephrosis is difficult to estimate since incorrect diagnosis is often made. There have been approximately 100 cases reported in the medical literature since Heitz-Boyer's first report;⁴⁾ most of them have been found in children. However, giant hydronephrosis in adult cases is seldom reported. It is found more often in males than in females and more often on the left side than on the right side.¹⁾

Giant hydronephrosis usually has a capacity of 2 to 9 liters of urine. The most serious case of hydronephrosis (115 liters) was reported by Dennehy in 1953,⁶⁾ and in recent years, Tombari et al. in 1968,⁵⁾ reported a case with a capacity of 52 liters. Both of them were found in children. Hydronephrosis is usually congenital in nature, often caused by stenosis of the ureteropelvic junction, ureter atresia, or aberrant vessels.¹⁾ The cause of hydronephrosis in our present case was considered to be congenital obstruction of the ureteropelvic junction.

The symptoms manifest most frequently as long-standing abdominal enlargement, diffuse abdominal pain and secondary respiratory difficulties.⁷⁾ By clinical examination, a steady mass in either flank is usually found without an alteration in its position. Urine examinations most often disclose hematuria, whereas the blood chemistry is usually normal with respect to serum-creatinine and liver-parameters.⁷⁾ In our case, serum creatinine was increased due to concomitant renal insufficiency. Although we did not perform a renal scintigraphy to assess renal blood flow, there may have been right renal ischemia caused by poor cardiac function. This diagnosis would be in line with the etiology of renal insufficiency, which is thought to be right renal ischemia and poor left renal function due to giant hydronephrosis.

A plain x-ray of the abdomen reveals a flank mass displacing the intestinum to the contralateral side. An intravenous pyelogram discloses as a rule a non-visualized kidney, and a supplementary ultrasonography demonstrates the enormous dilatation of the collecting system and the diminished rim of renal parenchyma.⁷⁾ Antegrade or retrograde pyelography may be used for visualization of the collecting system and the locality of obstruction or stenosis. Computerized tomography reveals the degree of dilatation.⁷⁾ The choice treatment for cases with unilateral affection in adults is often nephrectomy because of extremely poor kidney functioning.⁷⁾ However, whether the kidney will regain its function after the obstruction is released is controversial. The simple method of predicting recoverability of the kidney is the placement of a temporary nephrostomy tube.⁸⁾ If the previously obstructed kidney has not regained at least a 10 ml/minute creatinine clearance by 2–3 months, it is conceivable that the hydronephrotic kidney should not be preserved if the contralateral kidney is normal.⁸⁾ In our present case, nephrectomy for the left kidney was controversial because the function of the contralateral kidney was impaired. We proposed a nephrectomy to avoid the necessity of permanent nephrostomy. However, the left kidney should be preserved to retain as much total renal function as possible, even if its function is extremely poor.

In conclusion, we reported on a case of unilateral giant hydronephrosis accompanied by renal insufficiency in a fifty-two-year-old male, whose hydronephrotic sac contained about 3500 ml of urine. Although nephrectomy was indicated because of poor kidney functioning, the patient refused this procedure, and opted for a nephrostomy replacement every 2 weeks at an outpatient clinic.

REFERENCES

1. Chiang, P.H., Chen, M.T. and Chou, Y.H.: Giant hydronephrosis: Report of 4 cases with review of the literature. *J. Formosan. Med. Assoc.*, 89, 811–817 (1990).
2. Usos, A.C., Lewitt, S.B. and Lattimer, J.K.: Giant hydronephrosis in children. *Pediatrics.*, 44, 209–216 (1969).
3. Crooks, K.K., Hendren, W.H. and Pfister, R.C.: Giant hydronephrosis in children. *J. Pediatr. Surg.*, 14, 844–847 (1979).
4. Howze, C.P.: Giant hydronephrosis. *Trans. Am. Assoc. Genito-Urin. Surg.*, 28, 1–7 (1935).
5. Tombari, A.A., Power, R.F. and Harper, J.M.: Giant hydronephrosis: a case report with review of literature. *J. Urol.*, 100, 120–125 (1968).
6. Dennehy, P.J.: Giant hydronephrosis in a double kidney. *Br. J. Urol.*, 25, 247–252 (1953).
7. Madsen, H.T., Larsen, F. and Hauge, P.: Bilateral giant hydroureteronephrosis: A case report with a review of the literature. *Rontgenblatter.*, 42, 432–434 (1989).
8. Gillenwater, J.Y.: Hydronephrosis. In *adult and pediatric urology*, edited by Gillenwater, J.Y., Grayhack, J.T., Howards, S.S. and Duckett, J.W., pp. 691–714 (1987), Year Book Medical Publishers, Chicago.