

# THERMOCHEMOTHERAPY FOR CANCER OF THE TONGUE USING MAGNETIC INDUCTION HYPERTHERMIA (IMPLANT HEATING SYSTEM: IHS)

IWAI TOHNAI, YASUSHI HAYASHI, KENJI MITSUDO, TATSUYA KOBAYASHI\*,  
MASAAKI MATSUI\*\* and MINORU UEDA

*Department of Oral Surgery, Nagoya University School of Medicine, Nagoya, Japan*

*\*Department of Neurosurgery, Komaki City Hospital, Komaki, Japan*

*\*\*Department of Material Science and Engineering, Faculty of Engineering,  
Nagoya University, Nagoya, Japan*

## ABSTRACT

A 55-year-old patient with cancer of the tongue (T2N0M0) was treated by thermochemotherapy using interstitial magnetic induction hyperthermia (Implant Heating System: IHS). The patient received 2 courses of hyperthermia, each of which was 45 minutes long. At the same time, the patient received 2 courses of chemotherapy, which included intra-arterial infusion of 100 mg of cisplatin (CDDP) and 25 mg of peplo-mycin (PEP). The patient showed complete response (CR) to this therapy. To date, 1.5 years after completion of treatment, the patient has shown no recurrence. This therapy, which makes surgery and radiotherapy unnecessary, is promising, because it is expected to improve the quality of life (QOL) of cancer patients.

Key Words: Hyperthermia, Thermochemotherapy, Cancer of the tongue, Implant heating system, Interstitial hyperthermia

## INTRODUCTION

Radiotherapy and surgery have been the primary treatments for oral cancer. The effectiveness of these therapies on oral cancer has been excellent. However, when these therapies are used in the oral cavity, they can induce radiation stomatitis, radiation osteomyelitis and masticatory disturbances, which markedly reduce the patient's QOL.

We have recently developed an IHS, which is a heat-producing ferromagnetic implant for interstitial magnetic induction hyperthermia.<sup>1,2)</sup> This system has yielded good clinical results when used for to treat brain tumors<sup>3)</sup> and oral cancer.<sup>4)</sup> We previously reported that when this system was used for preoperative thermochemotherapy for oral cancer, subsequent surgery yielded good histopathological results.<sup>4)</sup> We recently encountered a case of cancer of the tongue, which responded well to a combination of hyperthermia using IHS and chemotherapy, removing the necessity for radiotherapy and surgery. A discussion of this case follows.

---

Correspondence: Iwai Tohnai, Department of Oral Surgery, Nagoya University School of Medicine, 65 Tsuruma-cho, Showa-ku, Nagoya 466, Japan

Tel: 81 (52)741-2111 (ext. 2293) Fax: 81 (52)741-3021

## CASE REPORT

The patient was a 55-year-old female. She had no noteworthy disease history or family history. In April 1993, she noted pain on the left side of her tongue, but she did not seek medical attention. In August 1993, she visited our hospital. At the initial examination, her general condition was normal. No lymph nodes were palpable in the cervical region. When her oral cavity was observed, an induration, accompanied by an ulcer (31×23 mm), was detected in the left margin of the tongue. She was clinically diagnosed as having cancer of the tongue (T2N0M0). Histopathological examination of a biopsy specimen confirmed a diagnosis of squamous cell carcinoma.

The patient was admitted to our department on September 2, 1993. On September 14, she underwent intra-arterial catheterization via the superficial temporal artery. After informed consent was obtained from the patient and her family, thermochemotherapy using IHS was performed.

The IHS consists of a ferromagnetic implant, an induction coil and a generator to produce a high frequency magnetic field as reported previously (Fig. 1).<sup>1)</sup> The ferromagnetic implant is composed of an Fe-Pt alloy in which the ratio of iron and platinum is 73% and 27% respectively, with a Curie temperature of 68°C.<sup>2)</sup> Three different sizes of implant needles are available for use with IHS. All needles are 1.8 mm in diameter and have lengths of 15, 20 and 25 mm, which allows IHS treatment to be tailored to different size tumors. A thread attached to the hole of the needle is used to prevent migration of the implants (Fig. 2-1). The generator has a maximum power of 2.5 kw and yields a maximum magnetic power of 16 Gauss at the center of the coil with a frequency of 250 kHz (Fig. 2-2). The needle-shaped implants are inserted into the tumor so that the whole tumor is covered, and, the long axis of the implants is parallel to the direction of the magnetic field. The rationale of this system is that the implants are heated by eddy

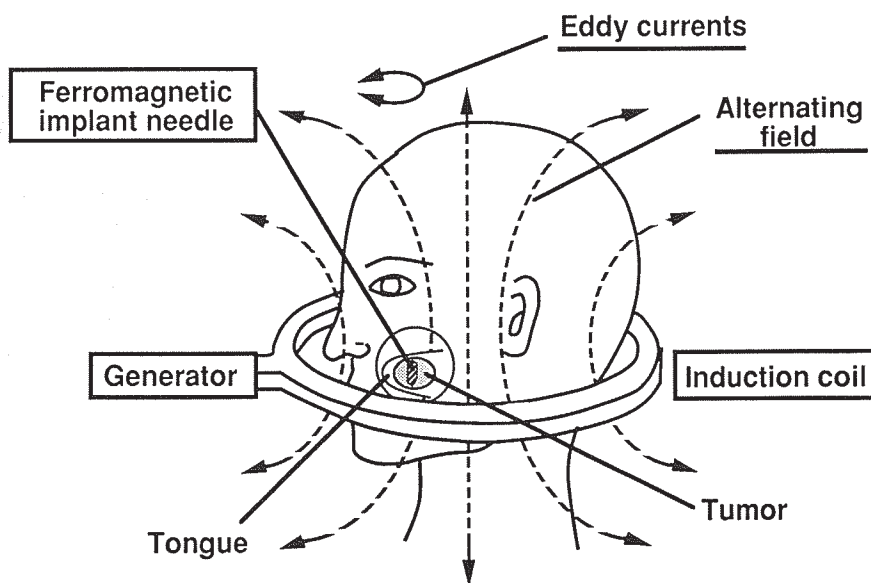


Fig. 1. Schema of Implant Heating System (IHS) for oral cancer. IHS consists of 3 parts: a ferromagnetic implant needle, an induction coil and a generator.

## THERMOCHEMOTHERAPY FOR CANCER OF THE TONGUE

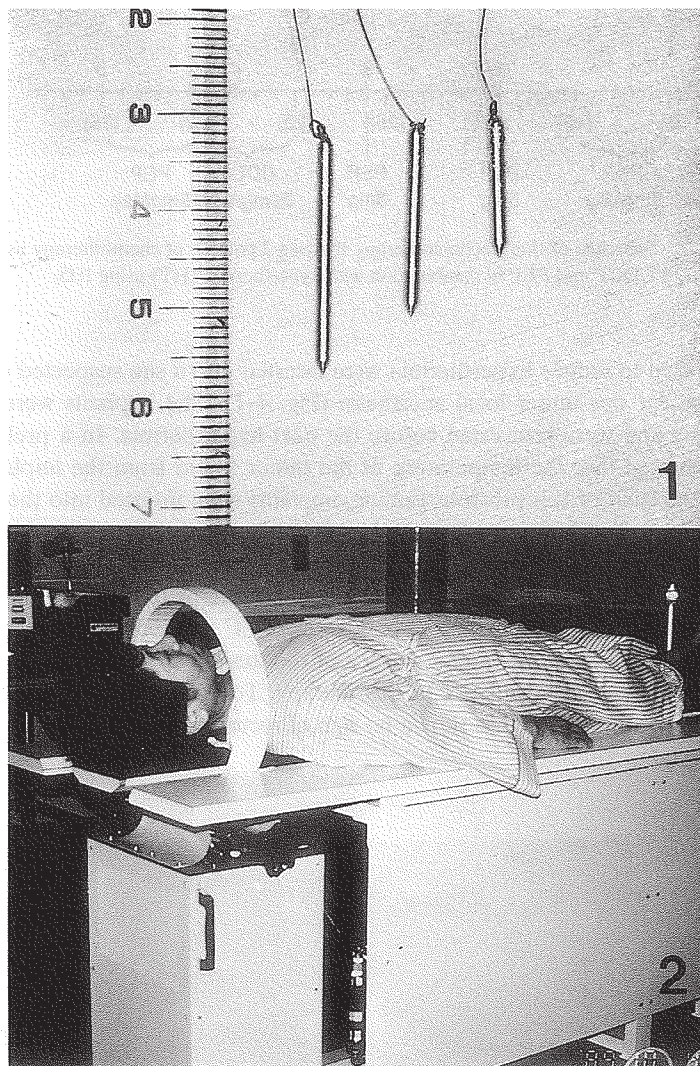


Fig. 2. Ferromagnetic implant and IHS.

- 2-1: Three different sizes of implants are available for different tumor sizes.
- 2-2: IHS in clinical use, consisting of a sliding table with an induction coil (30 cm in diameter) and a generator to produce a high frequency magnetic field.

current provided by the high frequency magnetic field and the whole tumor is heated by heat conduction from the implants.

The patient received 2 courses of chemotherapy which consisted of intra-arterial infusion of 100 mg of CDDP in 5 continuous days followed by 25 mg of PEP for 5 days via the superficial temporal artery. The patient also received 2 courses of the hyperthermia for 45 minutes each, each course of which occurred in tandem with a chemotherapy course as shown in Fig. 3. This treatment was initiated after obtaining informed consent from the patient and her family.

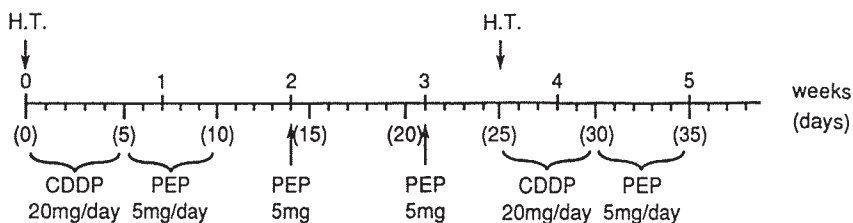


Fig. 3. Schedule of thermochemotherapy showing 2 courses of chemotherapy using CDDP and PEP in combination with hyperthermia (HT) using IHS.

The implants used to induce hyperthermia were inserted into a site suspected of being tumorous which the patient was under local anesthesia (Fig. 4-1). The implants were removed after each hyperthermia and were reinserted before the next hyperthermia. In a preliminary experiment, it was confirmed that the temperature of the tumor 5 mm from the implant had risen to about 43°C. On the basis of this previous finding, implants were inserted into the tumor at intervals of 10 mm (Fig. 4-2). The temperatures of each implant and the tumor were measured during hyperthermia using thermocouples (copper-constantan; Bailey Inc.). The temperature of the implants remained constant at 60–61°C, and the temperature of the tumor 5 mm from the implants remained constant between 42.5°C and about 43°C (Fig. 5). On macroscopic examination, necrosis was found on the lateral surface of the tongue 2 days after the first hyperthermia (Fig. 4-3). The patient showed CR to this therapy. To date, 1.5 years after completion of thermochemotherapy, the patient has shown no sign of recurrence (Fig. 4-4).

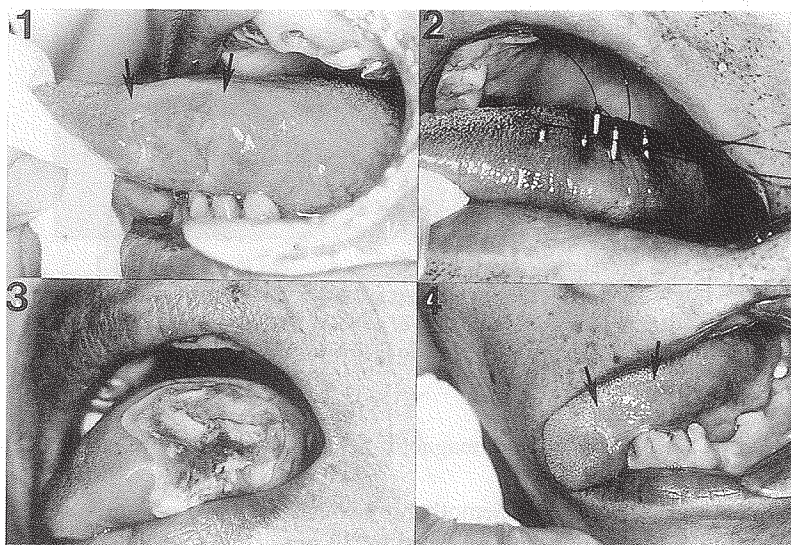


Fig. 4. Macroscopic changes in this patient.

- 4-1: Cancer of the tongue (T2N0M0) before treatment.
- 4-2: Position of implants in the tumor (5 implants were inserted into the tumor).
- 4-3: Necrosis is found at the surface of the tongue 2 days after the first hyperthermia.
- 4-4: 1.5 years after treatment (no signs of recurrence).

## THERMOCHEMOTHERAPY FOR CANCER OF THE TONGUE

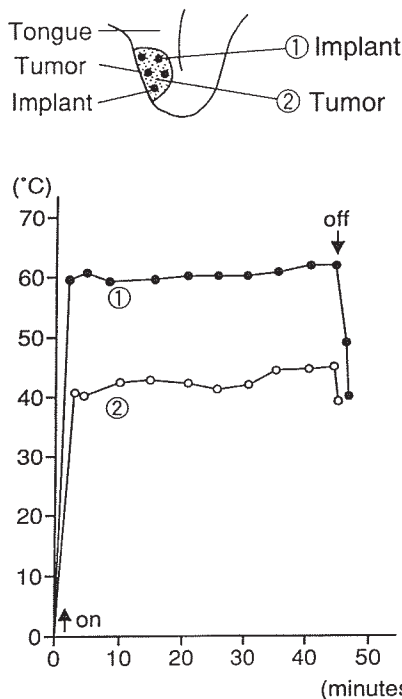


Fig. 5. Thermal distribution around the implant.

## DISCUSSION

Hyperthermia, induced by microwave or radiofrequency induction heating, has been used to treat malignant tumors of the head and neck.<sup>5-7</sup> However reports of such treatment deal mostly with metastases of lymph nodes and not with primary lesions because of the difficulty of heating oral tumors; due to high mobility and air containing organs.<sup>8</sup>

Interstitial magnetic induction hyperthermia by IHS used in our study makes possible selective heating of the tumor. Kobayashi et al.<sup>1,3</sup> initially reported favorable IHS therapeutic results with experimental and clinical brain tumors. It has also been found that IHS therapy brought about favorable anti-tumor effects in an experiment involving a VX-7 tongue tumor in a rabbit.<sup>9</sup> In 8 patients with oral cancer (T1 and T2), where surgery was carried out after thermochemotherapy using IHS, postoperative pathological examination revealed the complete disappearance of tumor cells.<sup>4</sup> On the basis of these findings, we anticipated that this therapy would be effective for T1 and T2 cancers of the oral cavity, even when used without surgery and radiotherapy.

Our IHS uses a ferromagnetic implant made of a Fe-Pt alloy (Fe: 73%, Pt: 27%) with a low Curie temperature (68°C).<sup>2</sup> Curie temperature is defined as the temperature at which magnetic material becomes para-magnetic i.e. where there is no eddy current and where no heat is produced. Maintaining an implant temperature less than the Curie temperature prevents excessive heating of the implant during hyperthermia, thus enhancing safety in clinical use.

The actual maximum temperature of the implant itself in the tumor was about 60°C, although the Curie temperature was 68°C. This result might be due to the cooling effect of abundant blood flow in the tongue, and or the cooling provided by saliva. It has, however, been confirmed that the temperature of the tumor at 5.0 mm from the implant consistently rose over 43°C in this case. Hence, a therapeutically favorable temperature distribution was observed in the tumor.

Hyperthermia in combination with radiotherapy is generally known to yield good results. There have been very few reports on the treatment of cancer of the oral cavity involving hyperthermia in combination with chemotherapy, but without radiotherapy. Hahn<sup>10</sup> showed that CDDP exerts a synergistic effect even at a relatively low temperature (39–41°C) in *in-vitro* Chinese Hamster Ovary (CHO) cells, resulting in a marked increase in cytotoxicity at 43°C. The anti-tumor effect of bleomycin (BLM) or its derivative PEP is markedly enhanced at 43°C, although BLM exerts almost no synergistic effect at 41°C.<sup>11,12</sup> Thus a temperature of at least 43°C seems to be required for successful clinical application. In this regard, interstitial hyperthermia using IHS was found useful in combination with chemotherapy using CDDP or PEP since temperatures of 43°C or higher were achieved during hyperthermia.

Thermochemotherapy using IHS is promising as a new therapy for oral cancer, because it does not necessitate surgery or radiotherapy and hence improves the QOL of oral cancer patients.

## REFERENCES

- 1) Kobayashi, T., Kida, Y., Tanaka, T., Kageyama, N., Kobayashi, H. and Amemiya, Y.: Magnetic induction hyperthermia for brain tumor using ferromagnetic implant with low Curie point: Experimental study. *J. Neuro-Oncol.*, 4, 175–181 (1986).
- 2) Matsui, M., Shimizu, T. and Kobayashi, T.: Research on hyperthermia implant material from a point of view of material science. In *Hyperthermic Oncology 1986 in Japan*, edited by Onoyama, Y., pp.63–64 (1987), Mag Bros Inc., Tokyo.
- 3) Kobayashi, T., Kida, Y., Tanaka, T., Hattori, K., Matsui, M. and Amemiya, Y.: Interstitial hyperthermia of malignant brain tumors by implant heating system: Clinical experience. *J. Neuro-Oncology*, 10, 153–163 (1991).
- 4) Tohnai, I., Goto, Y., Hayashi, Y., Ueda, M., Kobayashi, T. and Matsui, M.: Preoperative thermochemotherapy of oral cancer using magnetic induction hyperthermia (Implant Heating System: IHS). *Int. J. Hyperthermia*, 12, 37–48 (1996).
- 5) Perez, C.A., Nussbaum, G., Emami, B. and VON Gerichten, D.: Clinical results of irradiation combined with local hyperthermia. *Cancer*, 52, 1597–1603 (1983).
- 6) Griffin, T.W., Davis, R., Laramore, G.E., Hussey, D.H., Hendrickson, F.R. and Rodrigues-Antunez, A.: Fast neutron irradiation of metastatic cervical adenopathy; The results of a randomized RTOG study. *Int. J. Radi. Oncol. Biol. Physics*, 9, 1267–1270 (1983).
- 7) Abe, M. and Hiraoka, M.: Review: Localized hyperthermia and radiation in cancer therapy. *Int. J. Radi. Biol.*, 47, 347–359 (1985).
- 8) Ozeki, S., Ohbe, K. and Tashiro, H.: Application of hyperthermia for oral cancer by 2450 MHz microwaves. *Jpn. J. Oral and Maxillofac. Surg.*, 33, 627–634 (1983).
- 9) Goto, Y., Tohnai, I., Hayashi, Y., Kaneda, T. and Kobayashi, T.: The study of anticancerous effects of interstitial hyperthermia using implant heating system on VX-7 carcinoma of rabbit. *Jpn. J. Hyperthermic Oncol.*, 6, 443–454 (1990).
- 10) Hahn, G.M.: Potential for therapy of drugs and hyperthermia. *Cancer Res.*, 39, 2264–2268 (1979).
- 11) Hahn, G.M., Braun, J. and Har-Kedar, I.: Thermochemotherapy: Synergism between hyperthermia (42–43°C) and adriamycin (or bleomycin) in mammalian cell inactivation. *Proce. Natl. Academy Scie. USA*, 72, 937–940 (1975).
- 12) Shin, M.H., Anthony, C., Fogh, J. and Fortner, J.G.: Sensitivity of xenografts of pancreatic adenocarcinoma in nude mice to heat and heat combined with chemotherapy. *Cancer Res.*, 43, 4014–4018 (1983).