

SURGERY FOR RENAL HYPERPARATHYROIDISM — EXPERIENCE OF 640 CASES —

HIROSHI TAKAGI,* YOSHIHIRO TOMINAGA,**
YUJI TANAKA,* and KAZUHARU UCHIDA**

*Department of Surgery II, Nagoya University School of Medicine
**Department of Transplant Surgery, Nagoya 2nd Red Cross Hospital, Nagoya, Japan

ABSTRACT

Our experience in the field of surgery for renal hyperparathyroidism, gained from 640 cases, the largest number in the world, was reviewed. Additional comments were made on the relation between renal transplantation and renal hyperparathyroidism.

Key Words: Hyperparathyroidism, Parathyroidectomy, Image diagnosis, Renal transplantation

INTRODUCTION

The number of patients on long-term hemodialysis due to chronic renal failure has been steadily increasing in Japan. In spite of improved management many patients with renal hyperparathyroidism resistant to conservative treatment have been referred to us for surgical parathyroidectomy. Our series of surgical treatment dates back to July of 1973, which is quite possibly the first case thus treated for renal hyperparathyroidism in Japan. Since then over the past 25 years 640 patients have been operated on, which is the largest number in the world.

The purpose of this article is to review our experience in this field through this series of 640 cases.

Non-invasive image diagnosis¹⁻⁵⁾

The pathogenesis of renal osteodystrophy is complicated by a number of factors, and accurate diagnosis of renal hyperparathyroidism is not always easy. We have introduced three non-invasive image-diagnosing methods, computed tomography (CT), scintigraphy with $^{201}\text{TlCl}$ and $^{99\text{m}}\text{TcO}_4^-$, and ultrasonography (US) (Figs. 1, 2, 3). The demonstration of hypertrophic parathyroid glands in itself provides undeniable evidence of renal hyperparathyroidism. Thus, it has been our approach to look for other causes of disease when image diagnosis fails to reveal enlarged parathyroid glands. Because of occasional difficulties in the intraoperative search for parathyroid glands, preoperative localization of the gland is a great aid to surgeons.

Our first report on this issue was published in the Journal of Computer Assisted Tomography in June of 1982 with a special editorial comment¹⁾. This paper drew considerable attention, as

evidenced by more than 80 reprint requests from around the world, and led to our second report in the *Annals of Surgery* the following year²⁾.

*Subtotal versus total parathyroidectomy with forearm autograft*⁶⁻¹⁷⁾

We performed subtotal parathyroidectomy in our first 19 patients. However, since recurrent hyperparathyroidism was encountered and treated with reexploration of the neck in March of 1981, total parathyroidectomy with forearm autograft has been our choice of surgical procedure to date (Fig. 4). The postoperative clinical improvement has been remarkable with both procedures. The grafted parathyroid tissue in all cases has functioned well, and reimplantation of the cryopreserved parathyroid tissues has been unnecessary. As long as patients with chronic renal failure remain under dialysis treatment, it is naturally presumed that residual and transplanted parathyroid tissues ought to receive continuous stimulation to grow. The rationale for total parathyroidectomy with forearm autograft is that a second neck exploration, with all its attendant risks, can be avoided, and that excessive parathyroid tissue can easily be removed from the forearm under local anesthesia if renal hyperparathyroidism recurs.

*No postoperative calcium administration until serum calcium concentration drops close to 7 mg/100 ml*⁶⁻¹⁷⁾

After surgery serum calcium levels are monitored three times per day during the first 2–4 days and then daily until stabilized. As soon as the serum calcium concentration drops close to 7 mg/100 ml, constant intravenous infusion of calcium is started to maintain the serum calcium level at more than 8 mg/100 ml. Intravenous calcium is gradually reduced with the addition of oral calcium and vitamin D until the serum calcium is maintained between 8 and 10 mg/100 ml.

Most patients experience a rapid decrease in serum calcium and parathyroid hormone (PTH) during the first postoperative day. Hypocalcemia is generally evident between the first and the fifth day after surgery. The patients whose X-rays show severe bone changes tend require more supplemental calcium administration, although some patients could have been compensated by hemodialysis, which is performed with a calcium content of 3.6 mEq/L (Fig. 5).

The patients whose serum calcium does not drop to 7 mg/100 ml within 14 postoperative days may have supernumerary glands in the neck or in the uppermediastinum. With close postoperative observation the supernumerary gland tends to grow and can be visualized by image diagnosis in six months to two years.

Patients with severe ectopic calcification preoperatively do not show a sharp drop of serum calcium level. Serum PTH measurement is also helpful to make a decision in these cases.

*Polymorphic hyperplastic patterns of excised glands in secondary hyperparathyroidism*¹⁸⁻³⁰⁾

The parathyroid glands are very small but unique endocrine organs, which typically include four glands, which consist of parenchyma containing chief and oxyphil cells and a stroma composed primarily of adipocytes. The enlargement of the parathyroid glands is supposed to be secondary from the standpoint of end-stage renal failure. However, the four glands excised from a given patient do not necessarily show similarities either in weight or the histopathologic pattern of hyperplasia, which are easily divided into two distinctly different patterns, diffuse and nodular.

Figure 6 illustrates the relationship between glandular weight and hyperplastic pattern in our

SURGERY FOR RENAL HYPERPARATHYROIDISM

series. It is obvious that as the gland becomes heavier, the hyperplastic pattern changes from initial diffuse hyperplasia to early nodularity, then to nodular hyperplasia, and ultimately to a single nodule.

We performed clonal analysis of nodules from nodular hyperplasia, diffuse hyperplasia and autografted parathyroid tissue removed at recurrence by a method based on (1) restriction fragment length polymorphism of the X-chromosome-linked phosphoglycerokinase gene, and (2) random inactivation of the gene by methylation. This clonal analysis demonstrated that all four specimens of diffuse hyperplasia were polyclonal, whereas all seven specimens from nodules of nodular hyperplasia and all three samples representing autografted parathyroid material proved to be monoclonal. Based on histopathological studies, and both proliferative and clonal analysis, it is suggested that in renal hyperparathyroidism the parathyroid cells grow initially diffusely and polyclonally, whereas the cells in the nodules are transformed monoclonally, possibly due to some kind of genetic abnormality, and proliferate aggressively (Fig. 7).

Renal transplantation and renal hyperparathyroidism^{31,32)}

Our group has also performed renal transplantation in 597 cases (405 cases from living related donor and 192 cases from cadaveric donor) since June of 1972, the second largest number in Japan. Renal transplantation eradicates the basic disease of renal hyperparathyroidism with the reduction of calcium abnormalities and improvement of the phosphate metabolism. It has almost the same beneficial effects on the parameters of renal hyperparathyroidism; a decrease of serum PTH, calcium, alkaline phosphatase etc. and bone changes on X-ray film. However, markedly longer improvement periods are needed compared with those following parathyroidectomy. Image diagnosis of the parathyroid glands performed before transplantation to confirm enlargement of the glands in some cases fails to show the size reduction of the parathyroid glands in spite of improvements of clinical symptoms. Renal allografts during a long post-transplant course are at risk of damage by a number of factors, including rejection, drug-induced nephrotoxic nephropathy (especially by cyclosporine or tacrolimus) and recurrence of post-transplant glomerulonephritis. So together with renal graft functions the parathyroid parameters should be observed carefully. Sometimes the recurrence of hyperparathyroidism can be dramatically abrupt.

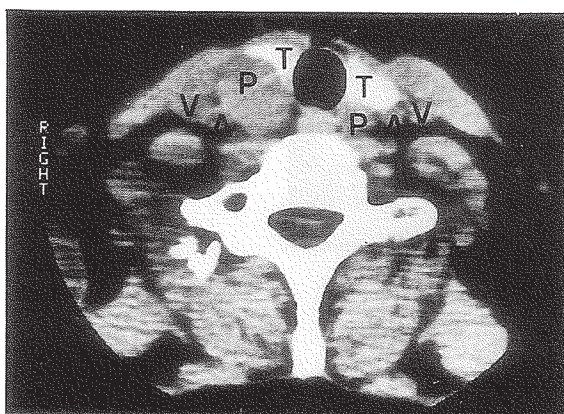


Fig. 1 Computed tomographic scan of patient No. 19 with enlarged parathyroid glands.
T: thyroid; P: parathyroid; A: carotid artery; and V: jugular vein

Scintigram PT24 (F.K.)

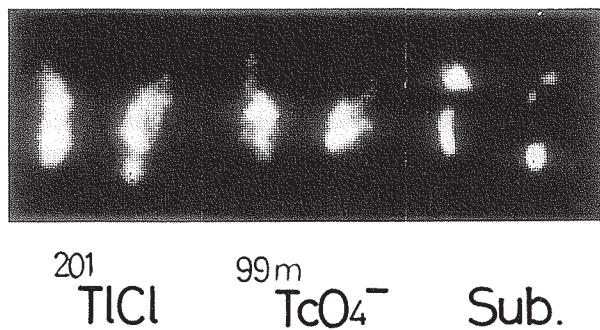


Fig. 2 Scintigraphy of parathyroid glands (patient No. 24). Left: $^{201}\text{TlCl}$ (parathyroid and thyroid; center: $^{99\text{m}}\text{TcO}_4^-$ (thyroid); and right: subtraction

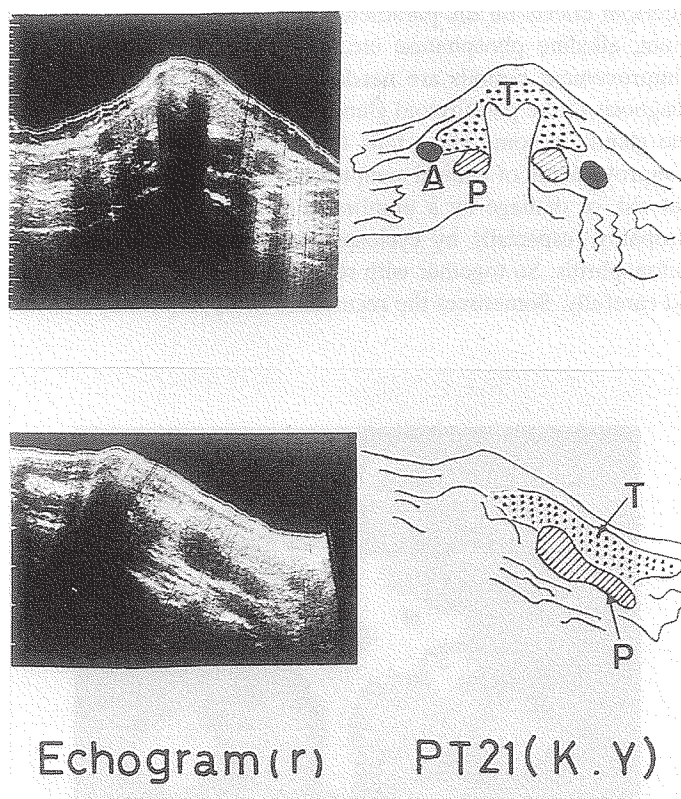


Fig. 3 Ultrasonography of patient No. 21 with enlarged parathyroid glands. Upper: transverse scan; lower: longitudinal scan; T: thyroid; P: parathyroid; and A: carotid artery

SURGERY FOR RENAL HYPERPARATHYROIDISM

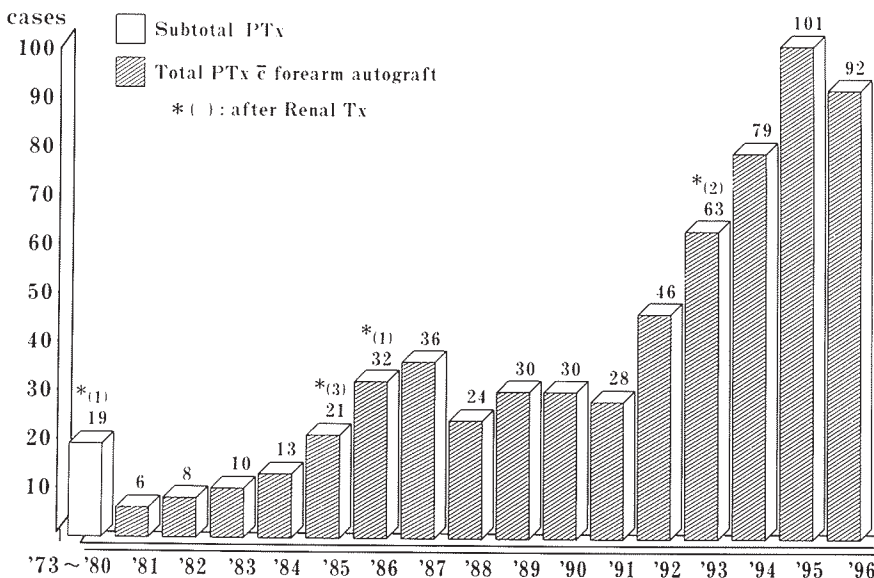


Fig. 4 Annual number of parathyroidectomies for renal hyperparathyroidism in our department. Altogether 640 patients underwent parathyroidectomy between July 1973 and December 1996. In the initial 19 cases subtotal parathyroidectomy was performed; as of April 1981, total parathyroidectomy with forearm autograft has been done.

Dose & Duration of Intravenous Ca-Gluconate Replacement after PTx (n=76)

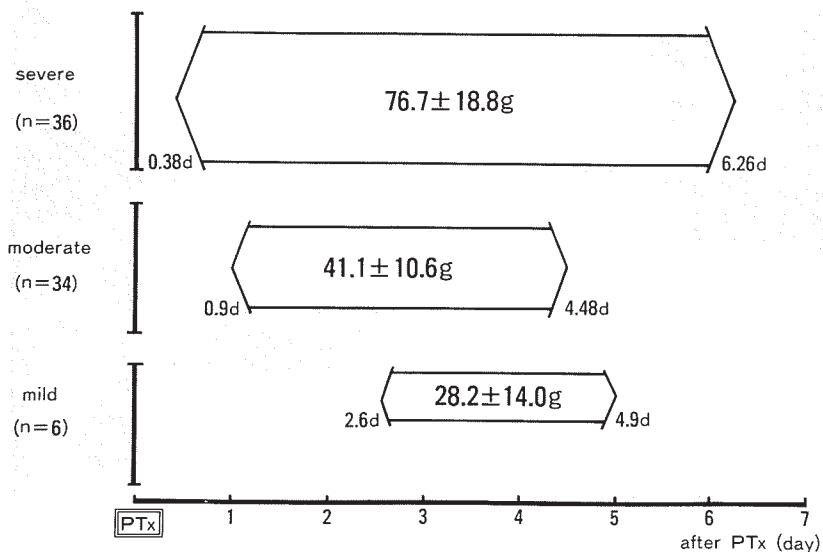


Fig. 5 Dose and duration of intravenous calcium gluconate replacement after parathyroidectomy (PTx) (n=76).

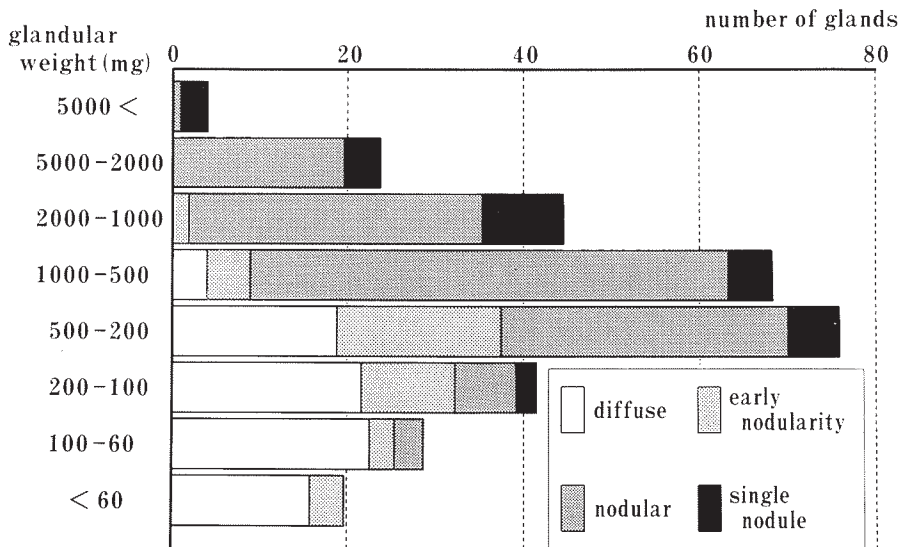


Fig. 6 Relationship between the pattern of parathyroid hyperplasia and glandular weight in renal hyperparathyroidism.

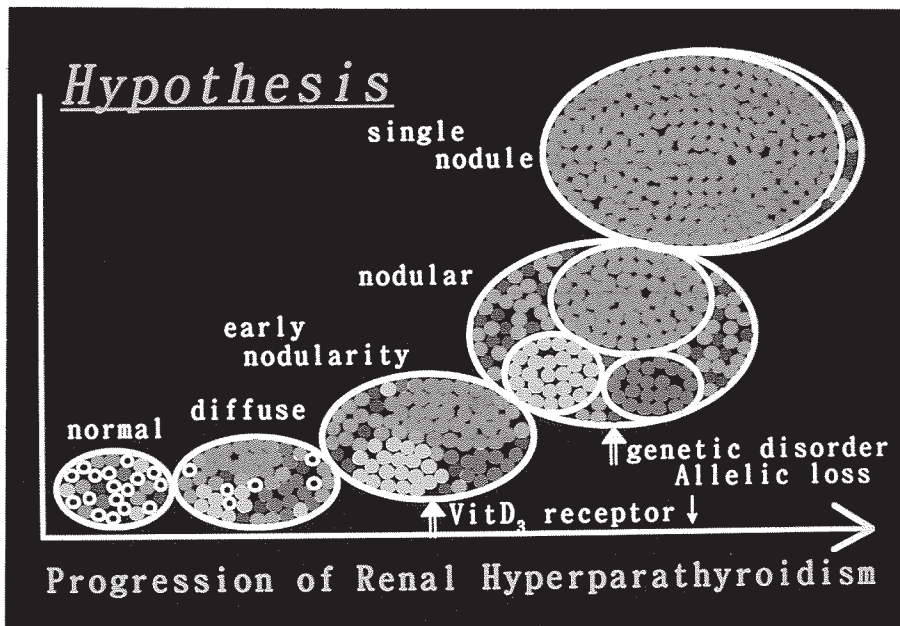


Fig. 7 Our hypothesis concerning the proliferative process of parathyroid hyperplasia in renal hyperparathyroidism. In chronic renal failure the parathyroid glands initially grow diffusely and polyclonally, and then cells in nodules are subsequently transformed monoclally, possibly due to some kind of genetic abnormality. Finally, one nodule with aggressive proliferative potential becomes markedly enlarged.

REFERENCES

- 1) Takagi, H., Tominaga, Y., Uchida, K., Yamada, N., Ishii, T., Morimoto, T. and Yasue, M.: Preoperative diagnosis of secondary hyperparathyroidism using computed tomography. *J. Comput. Assist. Tomogr.*, 6, 527–528 (1982).
- 2) Takagi, H., Tominaga, Y., Uchida, K., Yamada, N., Morimoto, T. and Yasue, M.: Image diagnosis of parathyroid glands in chronic renal failure. *Ann. Surg.*, 198, 74–79 (1983).
- 3) Takagi, H., Tominaga, Y., Uchida, K., Yamada, N., Kano, T., Kawai, M. and Morimoto, T.: Comparison of imaging methods for diagnosing enlarged parathyroid glands in chronic renal failure. *J. Comput. Assist. Tomogr.*, 9, 733–737 (1985).
- 4) Takagi, H., Tominaga, Y., Uchida, K., Yamada, N., Kawai, M., Kano, T., Funahashi, H. and Mizuno, S.: Evaluation of image-diagnosing methods of enlarged parathyroid glands in chronic renal failure. *World J. Surg.*, 10, 605–611 (1986).
- 5) Tanaka, Y., Tominaga, Y., Funahashi, H., Sato, K., Numano, M. and Takagi, H.: Preoperative localization studies in secondary hyperplasia. *Acta Chir. Austriaca*, 128, 14–16 (1996).
- 6) Takagi, H., Tominaga, Y., Uchida, K., Yamada, N., Kawai, M., Kano, T. and Morimoto, T.: Subtotal versus total parathyroidectomy with forearm autograft for secondary hyperparathyroidism in chronic renal failure. *Ann. Surg.*, 200, 18–23 (1984).
- 7) Takagi, H., Tominaga, Y., Tanaka, Y., Uchida, K., Orihara, A., Yamada, N., Kawai, M., Hayashi, S., Taira N. and Kano, T.: Total parathyroidectomy with forearm autograft for secondary hyperparathyroidism in chronic renal failure. *Ann. Surg.*, 208, 639–644 (1988).
- 8) Tominaga, Y., Tanaka, Y., Uchida, K., Kano, T., Yamada, N., Orihara, A., Kawai, M., Taira, N. and Takagi, H.: Surgical treatment of renal hyperparathyroidism: The results in 160 patients. *Endocrine Surg.*, 6, 59–64 (1989).
- 9) Tominaga, Y., Tanaka, Y., Sato, K., Numano, M., Uchida, K. and Takagi, H.: Surgical treatment of secondary hyperparathyroidism. *J. Bone Min. Met.*, 9, 294–300 (1991).
- 10) Tominaga, Y., Takagi, H.: Invited Commentary, Role of measurement of serum (1-84) intact parathyroid hormone level in patients with renal hyperparathyroidism. *Endocrine Surg.*, 9, 374–375 (1992).
- 11) Tominaga, Y., Numano, M., Uchida, K., Katayama, A., Haba, T., Asano, H., Sato, K., Tanaka, Y. and Takagi, H.: Parathyroidectomy for patients with renal hyperparathyroidism refractory to calcitriol pulse therapy. *J. Bone Min. Met.*, 12, 99–104 (1994).
- 12) Tominaga, Y., Sato, K., Numano, M., Tanaka, Y. and Takagi, H.: Surgical treatment of renal hyperparathyroidism. *Asian J. Surg.*, 17, 121–126 (1994).
- 13) Takagi, H., Tominaga, Y., Tanaka, Y., Sato, K., Numano, M. and Uchida, K.: Experiences of total parathyroidectomy with forearm autografts for 254 patients with renal hyperparathyroidism. *Acta Chir. Austriaca*, 28, 28–32 (1996).
- 14) Tominaga, Y., Tanaka, Y., Sato, K., Numano, M., Uchida, K., Asano, H., Haba, T., Kawai, M., Yokoyama, I. and Takagi, H.: Super numerary parathyroid glands in surgery for renal hyperparathyroidism. *Acta Chir. Austriaca*, 28, 16–19 (1996).
- 15) Tominaga, Y., Sato, K., Numano, M., Tanaka, Y., Uchida, K., Asano, H., Haba, T., Katayama, A. and Takagi, H.: Indications for parathyroidectomy in renal hyperparathyroidism. *Acta Chir. Austriaca*, 28, 10–13 (1996).
- 16) Tominaga, Y., Numano, M., Sato, K., Tanaka, Y., Uchida, K., Haba, T., Ichimori, T., Otsuka, S., Yamada, K., Katayama, A., Namii, Y., Nagasaka, T., Hachisuka, T., Asano, H. and Takagi, H.: Surgical treatment of renal hyperparathyroidism. *Semin. Surg. Oncol.* (in press).
- 17) Tanaka, Y., Funahashi, H., Imai, T., Tominaga, Y. and Takagi, H.: Parathyroid function and bone metabolic markers in primary and secondary hyperparathyroidism. *Semin. Surg. Oncol.* (in press).
- 18) Takagi, H., Tominaga, Y., Uchida, K., Yamada, N., Kano, T., Kawahara, K. and Suzuki, H.: Polymorphism of parathyroid glands in patients with chronic renal failure and secondary hyperparathyroidism. *Endocrinol. Jpn.*, 30, 463–468 (1983).
- 19) Takagi, H.: Foreword as a guest editor in the issue of “parathyroid hyperplasia and tumor”. *Semin. Surg. Oncol.* (in press).
- 20) Tominaga, Y., Tanaka, Y., Sato, K., Numano, M., Uchida, K., Falkmer, U., Grimelius, L., Johansson, H. and Takagi, H.: Recurrent renal hyperparathyroidism and DNA analysis of autografted parathyroid tissue. *World J. Surg.*, 16, 598–603 (1992).
- 21) Tanaka, Y., Seo, H., Tominaga, Y., Funahashi, H., Matsui, N. and Takagi, H.: Factors related to the recurrent hyperfunction of autografts after total parathyroidectomy in patients with severe secondary hyperparathyroidism. *Surg. Today*, 23, 220–227 (1993).

- 22) Tanaka, Y., Funahashi, H., Imai, T., Tobinaga, J., Murase, H., Andoh, H., Wada, M., Matsuyama, T., Tominaga, Y. and Takagi, H.: Heterotransplantation of human parathyroid glands into nude mice. *Endocrine J.*, 42, 9–14 (1995).
- 23) Tominaga, Y., Numano, M., Uchida, K., Sato, K., Asano, H., Haba, T., Katayama, A., Mukoyama, A., Suzuki, K., Tanaka, Y. and Takagi, H.: Lung metastasis from parathyroid carcinoma causing recurrent renal hyperparathyroidism in a hemodialysis patient: Report of a case. *Surg. Today*, 25, 984–986 (1995).
- 24) Tominaga, Y., Sato, K., Tanaka, Y., Numano, M., Uchida, K. and Takagi, H.: Histopathology and pathophysiology of secondary hyperparathyroidism due to chronic renal failure. *Clin. Nephrol.*, 44, 42–47 (1995).
- 25) Tominaga, Y., Takagi, H.: Molecular genetics of hyperparathyroid disease. *Curr. Opin. Nephrol. Hypertens.*, 5, 336–341 (1996).
- 26) Tanaka, Y., Funahashi, H., Imai, T., Seo, H., Tominaga, Y. and Takagi, H.: Oxyphil cell function in secondary parathyroid hyperplasia. *Nephron*, 73, 580–586 (1996).
- 27) Tominaga, Y., Tanaka, Y., Sato, K., Numano, M., Uchida, K., Asano, H., Haba, T., Falkmer, U., Grimelius, L., Johansson, H. and Takagi, H.: DNA studies in graft-dependent hyperparathyroidism. *Acta Chir. Austriaca*, 128, 65–68 (1996).
- 28) Tanaka, Y., Funahashi, H., Imai, T., Wada, M., Tominaga, Y., Mishra, S.K. and Takagi H.: Functional and morphometric study of cryopreserved human parathyroid tissue transplanted into nude mice. *World J. Surg.*, 20, 692–699 (1996).
- 29) Tominaga, Y., Kohara, S., Namii, Y., Nagasaka, T., Haba, T., Uchida, K., Numano, M., Tanaka, Y. and Takagi, H.: Clonal analysis of nodular parathyroid hyperplasia in renal hyperparathyroidism. *World J. Surg.*, 20, 744–752 (1996).
- 30) Tominaga, Y., Tanaka, Y., Sato, K., Nagasaka, T. and Takagi, H.: Histopathology, pathophysiology and indications for surgical treatment of renal hyperparathyroidism. *Semin. Surg. Oncol.* (in press).
- 31) Tominaga, Y., Uchida, K., Sato, K., Numano, M., Tanaka, Y. and Takagi, H.: Parathyroidectomy before and after renal transplantation. *Transpl. Proc.*, 24, 1861–1862 (1992).
- 32) Uchida, K., Tominaga, Y., Tanaka, Y. and Takagi, H.: Renal transplantation and secondary hyperparathyroidism. *Semin. Surg. Oncol.* (in press).