

A LIVE BIRTH FROM INTRACYTOPLASMIC INJECTION OF A TESTICULAR SPERMATOZOON

MASANORI YAMAMOTO,¹ ATSUO ITAKURA,² YUTAKA TOMODA,²
YOSHIMASA ASADA³ and NOBUHIKO SUGANUMA³

¹Department of Urology and ²Department of Obstetrics and Gynecology,
Nagoya University School of Medicine, and ³Department of Obstetrics and Gynecology,
Branch Hospital, Nagoya University School of Medicine

ABSTRACT

Testicular sperm was retrieved from a man with complete epididymal obstruction, and intracytoplasmic sperm injection was performed on his wife's oocytes. In four mature oocytes treated, two fertilized eggs were obtained, and a clinical pregnancy was established with embryo transfers. One healthy girl (2715 g) was delivered by cesarean section at 38 weeks' gestation. Our case shows that the use of testicular sperm can result in a normal live birth.

Key Words: Live birth, Pregnancy, Intracytoplasmic sperm injection, Testicular sperm

INTRODUCTION

In men with critically poor sperm quality, conventional in vitro fertilization (IVF) may be inadequate to allow fertilization. For these patients, oocyte micromanipulation techniques may result in fertilizations and pregnancies. Poor sperm quality (poor motility and abnormal sperm morphology) is also characteristic of spermatozoa microsurgically retrieved from the epididymis, and oocyte-micromanipulation-techniques have proven successful in improving the results of IVF with such sperm.¹⁾ Improved techniques for sperm preparation and microdroplet, and other enhanced approaches to insemination with standard IVF have also resulted in improved fertilization and pregnancy rates.²⁾ Nevertheless, the sensational results obtained with intracytoplasmic (single) sperm injection (ICSI) into the egg have remarkably changed the opportunity to achieve pregnancy in the worst cases of male factor infertility.³⁾ Because ICSI requires the injection of only 1 spermatozoon into the cytoplasm of the egg, we wondered if sperm from testicular parenchyma could be successfully retrieved and then used to initiate fertilization and pregnancy with ICSI. Recently, we reported the first case of successful pregnancy following ICSI into a human oocyte in the Japanese literature.⁴⁾ Herein, we report that this couple has the first normal healthy baby from ICSI in the Honshu area of Japan.

CASE REPORT

A 44-year-old man presented with azoospermia, normal testicular biopsies (Johnsen's score: 8–9) and normal serum levels of follicle-stimulating hormone (FSH), luteinizing hormone and testosterone. He had been married for three years. Ejaculate volume was normal and contained adequate fructose. On physical examination, his testicular size was bilaterally normal, and both vas deferens were palpable. He had no previous history of urogenital infection and had not undergone surgery. He had no palpable varicocele. A vasography showed normal patency. Based on these clinical findings, tentative diagnosis was epididymal obstruction with unknown etiology.

His wife (27-year-old) showed an obstruction of the left fallopian tube in hysterosalpingography, but normal patency of the right tube and normal shape of the uterine cavity. Her endocrine profiles were normal, and no antisperm blocking antibody was detected. Spontaneous ovulations and regular menstrual cycles (28- to 32-day cycle) were observed from her basal body temperature records and ultrasound examinations. Thus, the couple was indicated for IVF as male-factor infertility.

Ovarian stimulation with daily injections of pure FSH (Fertinom-P, 1 ampoule=75 IU, Serono Japan Co., Tokyo, Japan) and gonadotropin-releasing hormone analog (Suprecur, Hoechst Japan Co., Tokyo, Japan) was performed as previously described.⁴⁾ Ovarian follicular development was monitored by daily vaginal ultrasound examinations and serum estradiol measurements. A dose of 5000 IU of hCG (Teikokuzoki Pharmaceutical Co., Tokyo, Japan) was injected on the day when serum estradiol level was 1365 pg/ml and 5 preovulatory follicles (their mean diameter > 15 mm) were detected. Thirty-six hours after the hCG injection, follicular aspiration to retrieve oocyte was performed transvaginally, subsequently 8 oocytes were collected. After the pretreatment of the oocytes for ICSI as previously described,⁴⁾ 4 morphologically mature oocytes were obtained for ICSI.

Epididymal sperm retrieval by a micropuncture technique for microinsemination was attempted as previously described¹⁾ on the same day when oocytes were retrieved from his wife. Unfortunately no epididymal fluid was obtained through the procedures. Therefore, a testicular biopsy was performed in which a sample of 4 × 4 mm was collected. The testicular tissue was treated to retrieve testicular spermatozoon for ICSI as previously described.⁴⁾ The time lapse between the testicular sperm retrieval and ICSI procedure was within 4 hours. Prior to microinjection, the sperm were suspended in a-MEM containing 10% polyvinylpyrrolidone (PVP, MW=360,000, Sigma Co., St. Louis, U.S.A.). Our ICSI procedures were performed as previously described.⁴⁾ Figure 1 shows the instruments for microinsemination (Fig. 1). Of four ICSI procedures performed, the fertilization that was confirmed by the presence of two pronuclei was observed in one egg on the next day. The oocyte was transferred to the uterine cavity immediately as previously described.⁵⁾ Because one more cleaved oocyte was found on the next day, another embryo transfer was performed on that day. All IVF procedures were performed after the couple had provided informed consent, and were conducted in accordance with the guidelines and permission issued by the Japan Society of Obstetrics and Gynecology and the Ethics Committee at the Nagoya University School of Medicine. Luteal support with progesterone was performed as previously described,⁵⁾ and a positive pregnancy test (urinary hCG > 200 IU/L) was obtained 15 days after ICSI. Clinical pregnancy was confirmed by the detection of fetal cardiac movement with ultrasound imaging at 6 weeks and 5 days of gestation. Following amniocentesis to analyze the fetal chromosomes at 16 weeks of gestation, a normal female chromosomal pattern (46,XX) was observed and no chromosomal abnormality was detected. Because breech presentation had continued from 23 weeks until 37 weeks of pregnancy, we decided to perform

LIVE BIRTH FROM INJECTION OF TESTICULAR SPERM

an elective Cesarean section with informed consent provided by the couple. One healthy girl (2715 g) was delivered at 38 weeks and 0 days of gestation. The appgar score of this neonate was 9 at 1 minute and 10 at 5 minutes after birth, and no identifiable congenital anomalies were found. Figure 2 shows a photograph of a female newborn (seven days after birth).

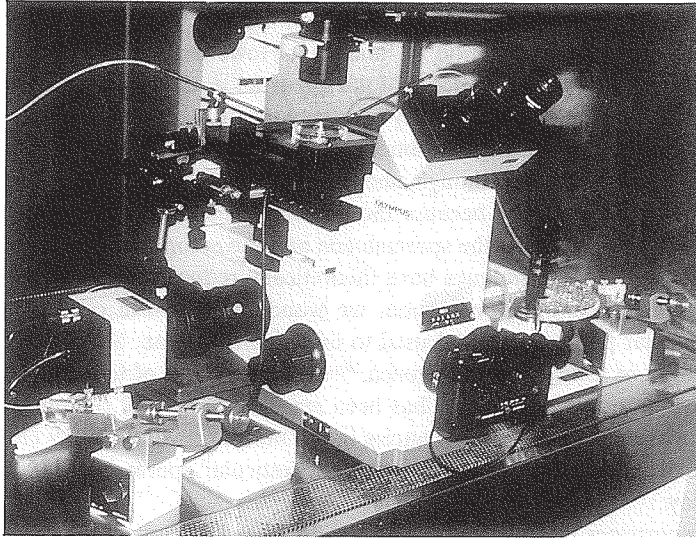


Fig. 1: Instruments for micromanipulation. Oocytes were treated under microscopic observation.

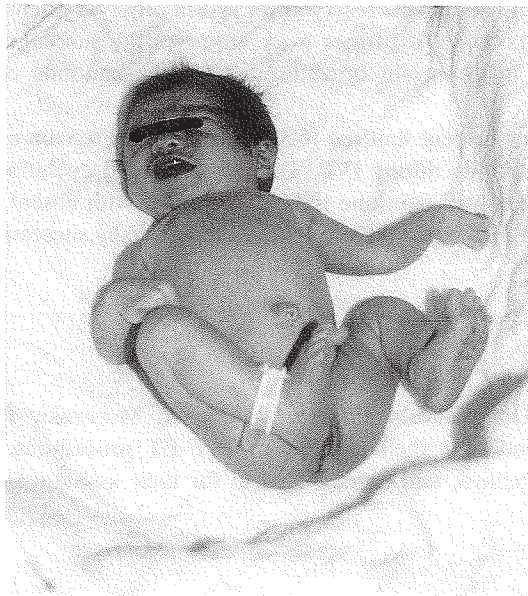

Fig. 2: Photograph of a female newborn (seven days after birth) originating from an oocyte treated by intracytoplasmic sperm injection with a testicular sperm.

DISCUSSION

Epididymal physiology has been the target of a considerable amount of experimental work concerning the role of this organ in sperm maturation.^{6,7)} Cases of epididymal obstruction have offered an apparent degree of flexibility in the need for epididymal sperm maturation during sperm transit through the entire epididymis. This flexibility became apparent during the analysis of results of vasoepididymostomies because such operations were performed at different levels of the epididymis (caput, corpus, or cauda)⁸⁾ and, in a sense, were experiments demonstrating the importance of epididymal function in humans.⁹⁾ However, such approaches are clearly in contradiction with the established concept of the importance of epididymal sperm transit and its influence on motility and fertilizing capacity of spermatozoa.

The use of testicular spermatozoa in obtaining fertilization is one more challenge to the concepts of epididymal physiology, although one must be careful in speaking about the fertilizing capacity of testicular spermatozoa because the microinsemination procedure bypasses all of the steps preceding the penetration of the spermatozoa into the cytoplasm of the oocyte.

Since micromanipulative techniques have theoretically reduced the minimum sperm requirement for fertilization to one spermatozoon, we wondered if sperm could be successfully retrieved from testicular parenchyma and used to initiate fertilization. Since Craft *et al.* suggested the fertilizing ability of testicular spermatozoa,¹⁰⁾ the observation of fertilization of oocytes with testicular sperm followed by pregnancy has been reported in several reproductive centers.¹¹⁻¹⁴⁾ Silber *et al.* reported five ongoing pregnancies in the most recent articles.¹⁴⁾ However, the exact number of normal deliveries after pregnancy with testicular sperm by ICSI has not been reported as of today.

Our case demonstrates that testicular sperm can be used in conjunction with ICSI to initiate fertilization, implantation, gestation and a live birth, which is significant because there are actually many situations in which the epididymis does not contain spermatozoa although spermatogenesis is normal, both in congenital or postinfectious obstructions. Thus, testicular parenchyma can now serve as an additional reservoir for sperm retrieval when microscopic epididymal sperm aspiration is not possible. If further work improves the success rate of fertilization with testicular spermatozoa, an important breakthrough for the handling of these cases could be achieved.

In conclusion, it is now evident that the ICSI procedure will remain a mainstay for treatment of severe male factor infertility during IVF. The ongoing rapid evolution of microinsemination techniques has enabled and will continue to enable couples with absent epididymis or epididymal obstruction in the entire length of the tubules to have a baby successfully when previously, it was deemed impossible.

ACKNOWLEDGMENTS

We are grateful to Drs. Takeshi Kitagawa, Takayuki Moriwaki, Tomoko Ando, Yutaka Ishihara, and Ikuyo Kondo for their support on IVF-ET procedures. We also acknowledge Itsuko Suzuki, Kumi Tsuchiya, and Satoko Eguchi for their assistance in medium preparation for IVF.

LIVE BIRTH FROM INJECTION OF TESTICULAR SPERM

REFERENCES

- 1) Yamamoto, M., Hibi, H., Miyake, K., Fukugaki, H., Suganuma, N. and Tomoda, Y.: Bulk sperm collection by epididymal micropuncture and stimulation of spermatic nerve: a novel sperm retrieval for IVF for surgically irreparable vasal obstruction. *Int. J. Androl.*, 18, 97–102 (1995).
- 2) Cohen, J., Malter, H. and Wright, G.: Partial zona dissection of human oocytes when failure of zona pellucida penetration is anticipated. *Hum. Reprod.*, 4, 435–442 (1989).
- 3) Van Steirteghem, A.C., Nagy, Z. and Joris, H.: High fertilization and implantation rates after intracytoplasmic sperm injection. *Hum. Reprod.*, 8, 1061–1066 (1993).
- 4) Suganuma, N., Asada, Y., Yamamoto, M., Moriwaki, T., Kitagawa, T., Tomoda, Y., Mishima, A. and Miyake, K.: Successful pregnancy after intracytoplasmic injection of single testicular spermatozoon into human oocyte. *J. Obstet. Gynec.* (in press).
- 5) Nakamura, K., Oosawa, M., Kondo, I., Inagaki, S., Shibata, H., Narita, O., Suganuma, N. and Tomoda, Y.: Menotropin stimulation after prolonged gonadotropin releasing hormone agonist pretreatment for in vitro fertilization in patients with endometriosis. *J. Assist. Reprod. Genet.*, 9, 113–117 (1992).
- 6) Bedford, J.M., Calvin, H.I. and Cooper, G.W.: The maturation of spermatozoa in the human epididymis. *J. Reprod. Fertil.*, 18 (supple), 199–213 (1973).
- 7) Brooks, D.E.: Metabolic activity in the epididymis and its regulation by androgens. *Physiol. Rev.*, 61, 515–555 (1981).
- 8) Yamamoto, M., Katsuno, S., Hibi, H. and Miyake, K.: Microscopic vasoepididymostomy for epididymal obstruction of unknown etiology: Experiences of ten cases. *Jpn. J. Fertil. Steril.*, 40, 458–462 (1995).
- 9) Schoysman, R. and Bedford, M.: The role of the human epididymis in sperm maturation and sperm storage as reflected in the consequences of epididymovasostomy. *Fertil. Steril.*, 46, 293–299 (1986).
- 10) Craft, I., Bennett, V. and Nicholson, N.: Fertilising ability of testicular spermatozoa. *Lancet*, 342, 864 (1993).
- 11) Devroey, P., Tournaye, H. and Liu J.: Normal fertilization of human oocytes after testicular sperm extraction and intracytoplasmic sperm injection. *Fertil. Steril.*, 62, 639–641 (1994).
- 12) Schoysman, R., Vanderzwalmen, P. and Nijs, M.: Pregnancy obtained with human testicular spermatozoa in an in vitro fertilization program. *J. Androl.*, 15, 10s–13s (1994).
- 13) Schoysman, R., Vandenwalmen, P., Nijs, M., et al.: Pregnancy after fertilization with human testicular spermatozoa. *Lancet*, 342, 1236–1237 (1993).
- 14) Silber, S.J., Van Steirteghem, A.C., Liu, J., Nagy, Z., Tournaye, H. and Devroey, P.: High fertilization and pregnancy rate after intracytoplasmic sperm injection with spermatozoa obtained from testicle biopsy. *Hum. Reprod.*, 10, 148–152 (1995).