

# REMARKABLE HEPATIC VEIN-TO-VEIN ANASTOMOSES IN GIANT CAVERNOUS HEMANGIOMA OF THE LIVER: A CASE REPORT

HIROHIKO KOJIMA

*Department of Surgery, Nagoya Tokushukai Hospital, Kasugai 486, Japan*

## ABSTRACT

Intrahepatic venous collaterals develop in Budd-Chiari syndrome, hepatomas, and other tumors if the hepatic veins are obstructed. In portal hypertension hepatic vein-to-vein anastomoses develop without obstruction of the hepatic veins. In a 53-year-old woman with giant cavernous hemangioma of the liver, hepatic venography demonstrated remarkable hepatic vein-to-vein anastomoses in the periphery of the hepatic veins without venous obstruction, accompanied with low wedged hepatic vein pressure. The hemodynamic change of the liver may cause this abnormality because of the large blood space of the hemangioma. Pathological examination of the resected liver apart from the tumor confirmed numerous deformations and dilatations of the central veins not found in the normal liver, in the area of hepatic vein-to-vein anastomoses shown by venography. Clinically, atypical hepatic resection is possible by maintaining a drainage vein to preserve as much of the normal liver as possible. Hepatic venography, as well as hepatic angiography, gives important information about the liver.

Key Words: Hepatic vein-to-vein anastomoses, Liver, Hemangioma, Hepatic venography.

## INTRODUCTION

Benign tumors of the liver are rare, and the most common benign tumor of the liver is the cavernous hemangioma<sup>1,2)</sup>. The small hemangioma of the liver is asymptomatic; symptoms occur when large hemangiomas compromise the function of adjacent organs. In recent years with the common use of sophisticated imaging techniques, hemangiomas of the liver are being observed more often<sup>3,4)</sup>. Among the imaging techniques, selective hepatic angiography is the most useful to diagnose hemangiomas, although it is invasive<sup>2,5)</sup>. Hepatic venography, though rarely performed except for Budd-Chiari syndrome<sup>6)</sup> and portal hypertension<sup>7,8)</sup>, may image hepatic vein-to-vein anastomoses in the liver. In the literature hepatic vein-to-vein anastomoses accompanying cavernous hemangioma of the liver have not been reported, though other types of tumors are known occasionally to present venous anastomoses.

This paper documents a female patient with a giant cavernous hemangioma whose preoperative hepatic venograms showed remarkable hepatic vein-to-vein anastomoses without obstruction of the hepatic veins, and the pathological findings demonstrated abnormality of the central veins.

---

Correspondence: Dr. Hirohiko Kojima, ORIENTAL CLINIC, 1-8-5, Imaike, Chikusa-ku, Nagoya 464, Japan

Received for Publication in October 30, 1991

## CASE REPORT

A 53-year-old housewife (height: 155 cm; weight: 52 Kg) came to the emergency room complaining of vertigo, nausea and vomiting on October 25, 1986. She was admitted because of anemia and hepatic enlargement. She had a history of a surgical operation for lumbar disk herniation and blood transfusion. On physical examination she appeared well. The chest was normal. The abdomen was flat and soft, the liver was palpated three finger-breadths below the right costal margin, and the spleen and kidneys were not palpable. In the laboratory findings, complete blood counts were normal except for a 9.0 g/dl hemoglobin level, and blood liver function tests including indocyanine green (ICG) test were normal. HBs antigen and antibody were negative; alphafetoprotein (AFP), carcinoembryonic antigen (CEA), CA19-9 and elastase I were also negative.

Ultrasonography revealed a low echoic area of eight cm in diameter in the right lobe of the liver. Computed tomography (CT) also demonstrated a massive low density area with partial lower density areas in the tumor. With enhancement there were condensed areas with contrast medium within the perimeter of the tumor, and the compressed inferior vena cava (IVC) could be seen clearly. (Fig. 1).

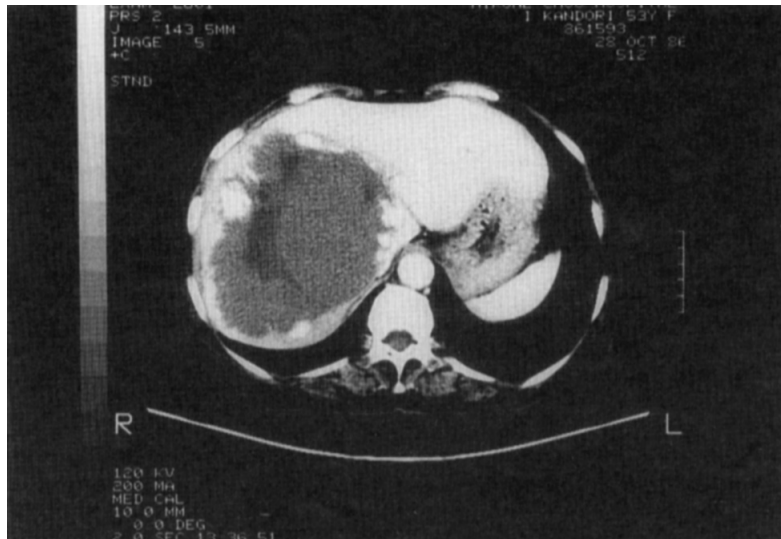


Fig. 1 A postcontrast CT scan reveals a low density area of 8 cm in diameter with strongly enhanced parts, and contrast "pudding" is typical of a cavernous hemangioma.

Celiac angiography demonstrated a large, mottled appearance in the right lobe of the liver with the right hepatic artery compressed but not dilatated or encased (Fig. 2). In the venous phase the right portal branch was merely compressed but without other abnormality.

## HEPATIC VEIN-TO-VEIN ANASTOMOSES IN CAVERNOUS HEMANGIOMA

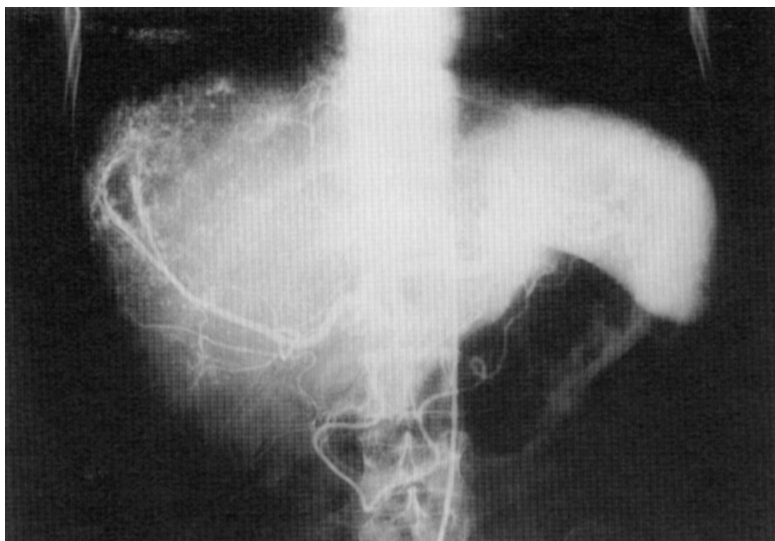


Fig. 2 Celiac angiography demonstrates a large mottled appearance, and the right hepatic artery is displaced.

Before surgery free venography of the right hepatic veins was performed simultaneously with inferior vena cavography because of the compressed IVC and the huge hemangioma. Peripheral branches of the right hepatic veins presented remarkable hepatic vein-to-vein anastomoses but without obliteration of the veins (Fig. 3). The wedged hepatic vein pressure actually measured  $-10$  mm saline in comparison with the free hepatic vein pressure.

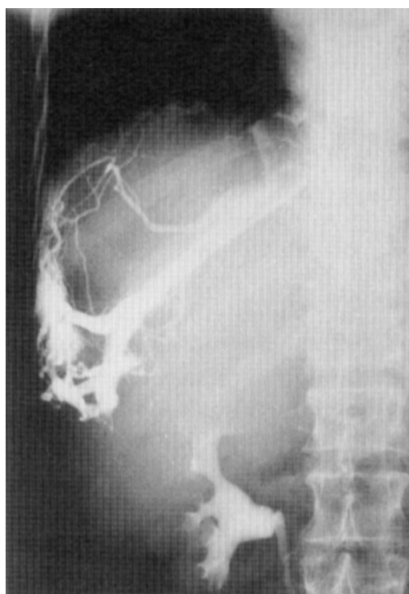


Fig. 3 Free venography of the right hepatic veins shows remarkable vein-to-vein anastomoses in the periphery of the hepatic veins.

A month after her admission the patient underwent a right lobectomy of the liver because of the huge mass and her symptoms. The resected specimen weighed 920 g. From the pathology reports the tumor was a typical cavernous hemangioma, and there were numerous deformations and dilatations of the central veins in the peripheral area of the normal part of the right lobe that showed vein-to-vein anastomoses (Fig. 4 and Fig. 5).

The patient is healthy and leading an ordinary life five and half years after the operation.

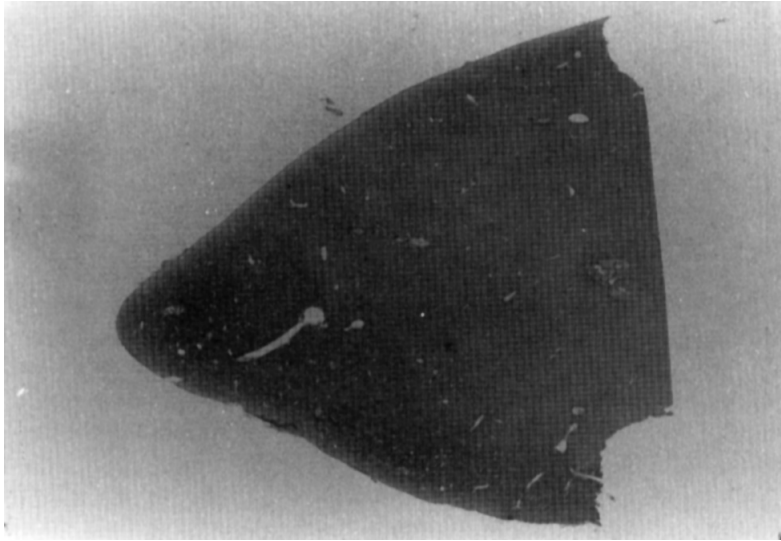


Fig. 4 A section of normal liver specimen apart from the hemangioma presents hepatic vein-to-vein anastomoses by venography. Numerous dilated small veins of the liver are visible and these vessels may present vein-to-vein anastomoses.

## DISCUSSION

Hemangiomas are being seen more often as a result of the more common use of radionuclide scans, ultrasonography, and computed tomography (CT), which are sophisticated and non-invasive imaging techniques<sup>3,4,5,9,10</sup>. CT is the best non-invasive method for determining the presence, nature and extent of hepatic lesions and may also be specific in the diagnosis of cavernous hemangioma<sup>4,5</sup>. Angiography is the most specific and sensitive examination for hemangiomas, but it is invasive and inconvenient<sup>2,5,11</sup> as compared with CT. The liver has three kinds of vessels, i.e., the hepatic arteries, the portal veins, and the hepatic veins, and patterns and abnormalities of these vessels are useful information especially for hepatic surgery.

Hepatic vein-to-vein anastomoses are well-known in Budd-Chiari syndrome and segmented ligation of veins<sup>6</sup>. Anastomoses of the hepatic veins are also reported in cases of hepatomas<sup>12</sup> and other tumors<sup>13</sup> when tumors obstruct a hepatic vein. However, when there is no obstruction of the hepatic veins these anastomoses are found to look remarkably like a "weeping willow" in idiopathic portal hypertension and minimally so in liver cirrhosis<sup>7,8</sup>. In the normal liver free hepatic venograms may also show some sinusoidal opacification, i.e., minimal hepatic vein-to-vein anastomosis<sup>7,8,15</sup>. Hepatic venography is rarely performed for hemangiomas, and there has been

## HEPATIC VEIN-TO-VEIN ANASTOMOSES IN CAVERNOUS HEMANGIOMA

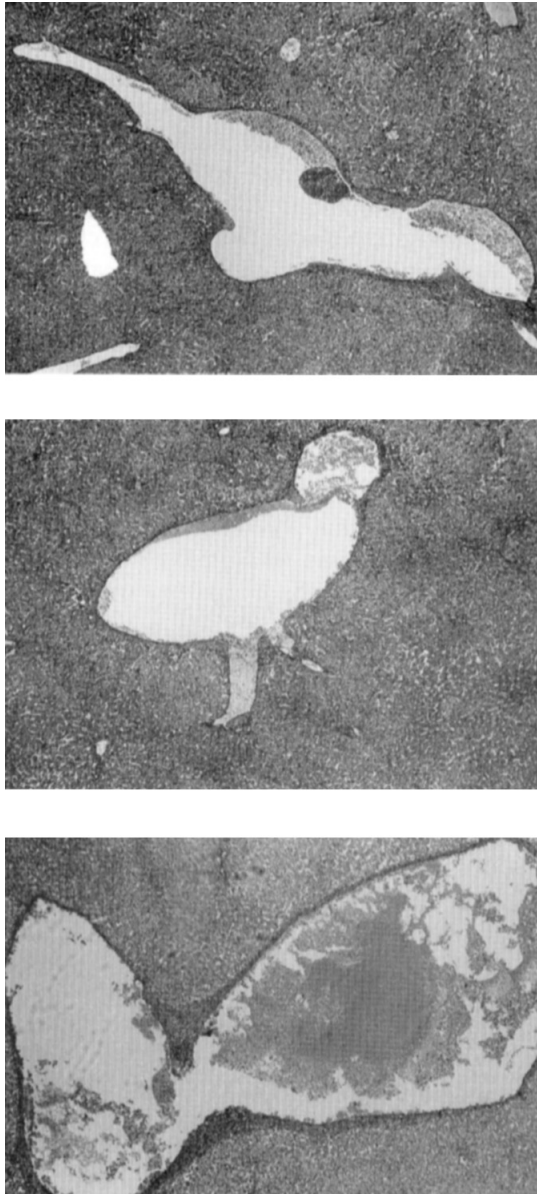


Fig. 5 Various deformations and dilatations of the central veins are seen in the areas of hepatic vein-to-vein anastomoses by venography (x12.5, Masson's trichrome stain). These abnormalities of the central veins are not seen in the normal liver.

only one report<sup>10)</sup> that total hepatic venography for three cases of hemangiomas demonstrated compression of the hepatic veins by the tumors but no other abnormality of the veins.

In the present case, hepatic venography was performed before hepatic resection to evaluate the hepatic morphology and hemodynamics because of the huge mass in the liver. Hepatic vein-to-vein anastomoses were observed (Fig. 3), with a low wedged hepatic vein pressure of -10 mm saline. This low wedged hepatic vein pressure indicates that hemodynamic change may have occurred in the liver.

Both the hepatic veins and the portal veins normally have an end vein pattern of distribution, there being no communication between the veins and the hepatic arteries. After hepatic veins are ligated, interlober collaterals develop between the patent hepatic veins<sup>6)</sup>. In portal hypertension reduction of portal flow results in gradual loss of parenchymal cells and in development of communication between sublobular veins, i.e., vein-to-vein shunts<sup>8)</sup>.

The patient in the present case had no symptoms or signs of portal hypertension. In a giant hemangioma, arterial flow and venous flow through the tumor must change because of the tumor's large blood space. Therefore communication between the hepatic veins may develop in the subcapsular space and in the peripheral veins.

In such cases, atypical hepatic resection is possible because venous drainage can be maintained even if one of the main hepatic veins is ligated. Normal parts of the liver can thus be preserved where they would usually have to be resected in a typical operation.

## CONCLUSION

A case of giant cavernous hemangioma of the liver presented remarkable hepatic vein-to-vein anastomoses in the periphery of the hepatic veins by hepatic venography. It was accompanied with low wedged hepatic vein pressure indicating the hemodynamic change in the liver, and histological examination proved various deformations and dilatations of the central veins. Hepatic venography, as well as hepatic angiography, is an important tool to evaluate the morphology and hemodynamics of the liver when a tumor is large. Giant cavernous hemangiomas should be considered one of the hepatic diseases in which hepatic vein-to-vein anastomoses may exist.

The author examined and operated on this patient at Hikone Chuō Hospital, Hikone-shi, Shiga-ken.

## ACKNOWLEDGEMENTS

The author thanks Dr. Kouji Ikuta, Associate Professor of the Department of Pathology, Aichi Medical University for the pathological studies on this case.

## REFERENCES

- 1) Adam Y.G., Huvos A.G. and Fortner J.G., Giant hemangiomas of the liver. *Ann. Surg.*, 172, 239-245, 1970.
- 2) Grieco M.B. and Miscall B.G., Giant hemangiomas of the liver. *Surg. Gynecol. Obstet.*, 147: 783-787, 1978.
- 3) Adoson M.A., Diagnosis and surgical treatment of primary and secondary solid hepatic tumors in the adult. *Surg. Clin. North Am.*, 61, 181-196, 1981.
- 4) Takaji H., Kido C., Morimoto T. et al. Surgical treatment of cavernous hemangioma of the liver. *J. Surg. Oncol.*, 26, 91-99, 1984.

## HEPATIC VEIN-TO-VEIN ANASTOMOSES IN CAVERNOUS HEMANGIOMA

- 5) Johnson C.M., Sheedy P.F., Stanson A.W. et al. Computed tomography and angiography of cavernous hemangioma of the liver. *Radiology*, 138, 115–121, 1981.
- 6) Qu Q.J. and Hermann R.E. The role of hepatic veins in liver operations. *Surgery*, 95, 381–391, 1984.
- 7) Futagawa S., Fukazawa M., Musha H. et al. Hepatic venography in non-cirrhotic idiopathic portal hypertension. Comparison with cirrhosis of the liver. *Radiology*, 141, 303–309, 1981.
- 8) Okuda K., Nakashima T., Okudaira M., et al. Anatomical basis of hepatic venographic alterations in idiopathic portal hypertension. *Liver*, 1, 255–263, 1981.
- 9) Moinuddin M., Allison J.R., Montgomery J. H., et al. Scintigraphic diagnosis of hepatic hemangioma. Its role in the management of hepatic mass lesions. *A. J. R.*, 145, 223–228, 1985.
- 10) Yoshimatsu S., Kuwabara Y., Suzuki H., et al. Giant cavernous hemangioma of the liver. *Jpn. J. Radiol.*, 29, 443–449, 1984. (in Japanese)
- 11) Starzel T.E., Koep L.J., Weil R., et al. Excisional treatment of cavernous hemangioma of the liver. *Ann. Surg.*, 192, 25–27, 1980.
- 12) Watanabe T., Hiramatsu K., Matsuyama S., et al. Hepatic venography on hepatoma. *Jpn. J. Clin. Radiol.* 20, 119–125, 1975. (in Japanese).
- 13) Takayasu K., Moriyama N., Muramatsu Y., et al. Intrahepatic venous collaterals forming via the inferior right hepatic vein in 3 patients with obstruction of the inferior vena cava. *Radiology*, 154, 323–328, 1985.
- 14) Kadir S., Hepatic venography. In *Diagnostic Angiography*. W.B. Saunders Company. 1986, pp. 390–392.