

CASE REPORT

Nagoya J. Med. Sci. 75. 131 ~ 137, 2013

STABILIZING INCOMPLETE REDUCTION OF THE RADIAL HEAD USING A HINGED SPLINT: CONSERVATIVE TREATMENT FOR A MONTEGGIA EQUIVALENT LESION

TAKAAKI SHINOHARA¹, EMIKO HORII², MASAHIRO TATEBE¹, MICHIRO YAMAMOTO¹,
SHIGERU KURIMOTO¹ and HITOSHI HIRATA¹

¹Department of Hand Surgery, Nagoya University Graduate School of Medicine, Nagoya, Japan

²Department of Orthopaedic Surgery, Nagoya First Red Cross Hospital, Nagoya, Japan

ABSTRACT

Radial head dislocation associated with plastic bowing of the ulna is classified as a Monteggia equivalent lesion. This injury in children can be treated by closed reduction, but manipulative reduction may not completely correct plastic bowing of the ulna. We encountered two cases of incomplete reduction in which the radial head was reduced in a supination position, but redislocated during rotation from neutral to a pronation position. The patients were treated conservatively using an adjustable hinged elbow splint. Plain radiography at 6 weeks after incomplete closed reduction showed that the radial head was reduced in all positions from supination to pronation; thus, both patients had good outcomes. Our method is non-invasive and may be an option for treatment of incomplete reduction of radial head dislocation with acute plastic bowing of the ulna.

Key Words: conservative treatment; hinged elbow splint; incomplete reduction; plastic bowing; radial head dislocation

INTRODUCTION

A Monteggia lesion is an uncommon injury in a pediatric elbow joint¹⁾ and radial head dislocation associated with traumatic plastic bowing of the ulna, which is classified as a Monteggia equivalent lesion, is easily overlooked²⁾. However, a dislocated radial head should be reduced as soon as possible because delayed treatment might produce a requirement for open reduction of the radial head and corrective osteotomy of the ulna³⁾. Failure of reduction might occur due to interposition of soft tissue in the radiocapitellar joint or incomplete correction of the ulnar deformity. We encountered two cases of incomplete reduction, in which the radial head showed eccentric motion during pronation to supination motion after reduction. Instead of open reduction, these cases were treated using a hinged splint.

Received: December 25, 2012; accepted: January 28, 2013

Corresponding author: Takaaki Shinohara

Department of Hand Surgery, Nagoya University Graduate School of Medicine,
65 Tsurumai-cho, Showa-ku, Nagoya 466-8550, Japan

Tel: +81-52-744-2957, Fax: +81-52-744-2964, E-mail: hand_surgery1966@yahoo.co.jp

CASE REPORT

Case 1

A 6-year-old boy was referred to our hospital due to incomplete reduction of the radial head. He had fallen down over an outstretched arm 8 days earlier. He had been diagnosed with radial head dislocation with plastic bowing of the ulna at a local hospital and reduction had been performed under general anesthesia on the same day. Plain radiography at the time of injury showed the radial head dislocated anteriorly and the ulna had a bowing deformity (Fig. 1). The ulnar bow rates⁴⁾ (the ratio of the maximum ulnar bow⁵⁾ divided by the ulnar length;

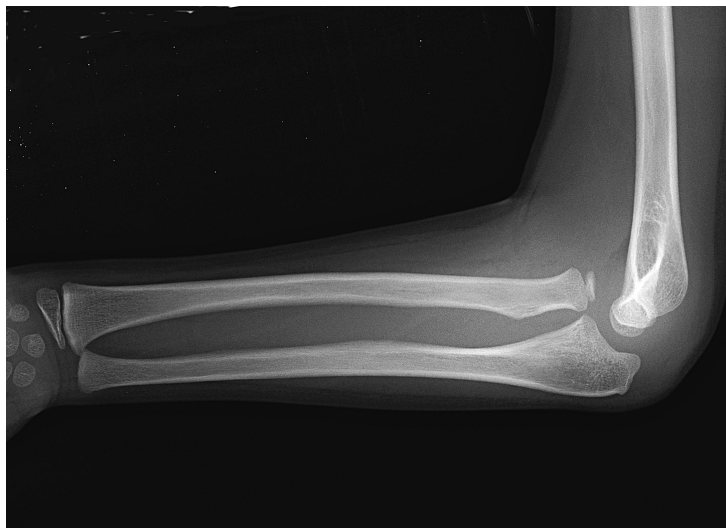

Fig. 1 Case 1, a 6-year-old boy. Lateral radiograph of the left forearm showing anterior dislocation of the radial head with plastic bowing of the ulna.

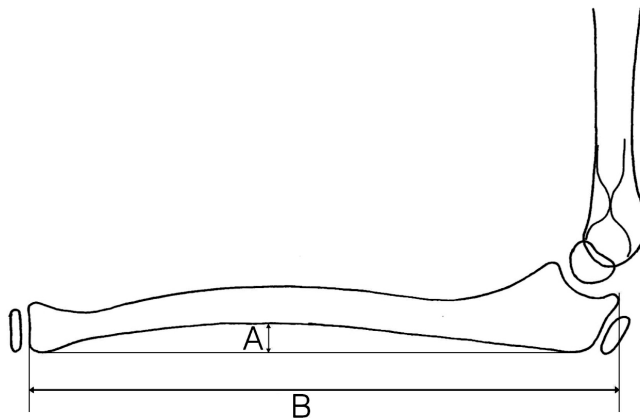


Fig. 2 Method of calculation of the ulnar bow rate as the percentage ratio A/B. A: The maximum ulnar bow, determined as the maximum perpendicular distance from a straight line drawn along the dorsal border of the ulna. B: Length of the ulna.

INCOMPLETE REDUCTION OF THE RADIAL HEAD

Fig. 2) were 3.6% on the affected side and 0% on the contralateral side. The ulnar bow rates were evaluated in neutral position. After reduction, the rate on the affected side decreased to 1.8%. Further examination revealed that the radial head was reduced in a supinated position, but anteriorly dislocated from neutral to a pronation position (Fig. 3).

Instead of performing open reduction, we decided to continue conservative treatment using an adjustable hinged elbow splint. The splint has a hinge at the elbow joint that controls the flexion-extension arc but permits free pronation-supination motion. The aim of the splint was to reduce the traction force of the biceps muscle on the radial head while allowing the soft tissue surrounding the radial head to heal and stabilize the proximal radio-ulnar joint.

The arm was immobilized in a long arm cast with the elbow at 100 degrees of flexion and the forearm and wrist in neutral positions for an additional 2 weeks. At 3 weeks after injury, active motion exercise was commenced with the splint. The flexion-extension arc was limited by the splint to 90 to 140 degrees and prosupination motion was encouraged (Fig. 4).

Restriction of elbow extension was gradually decreased, 10 degrees for every 3 days, under

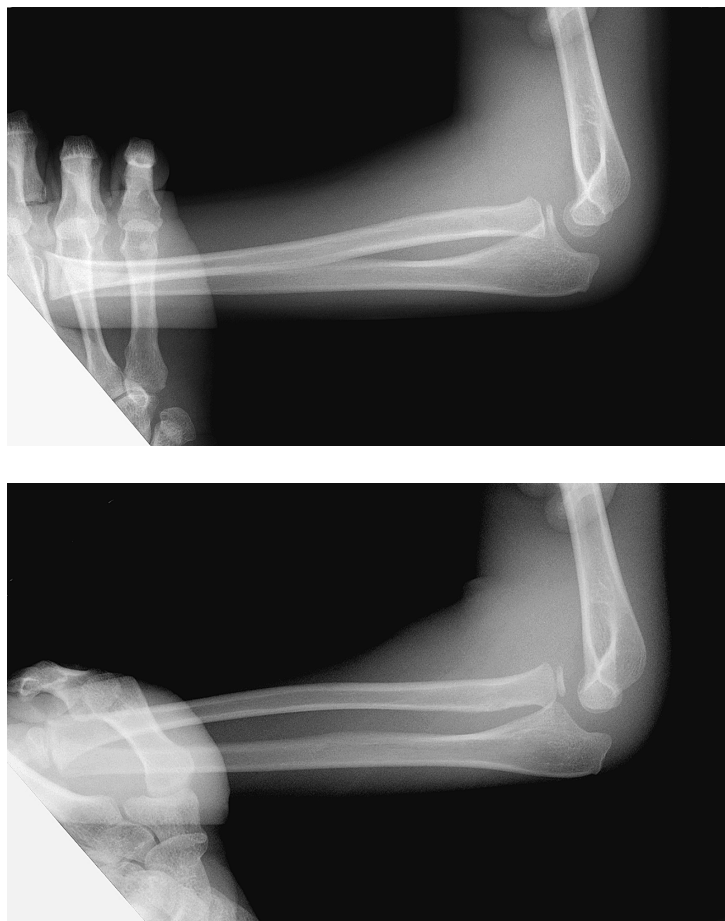

Fig. 3 Case 1, a 6-year-old boy. Lateral radiographs of the left forearm after closed reduction. A) The radial head was reduced in a supination position. B) The radial head was redislocated during rotation from neutral to a pronation position.

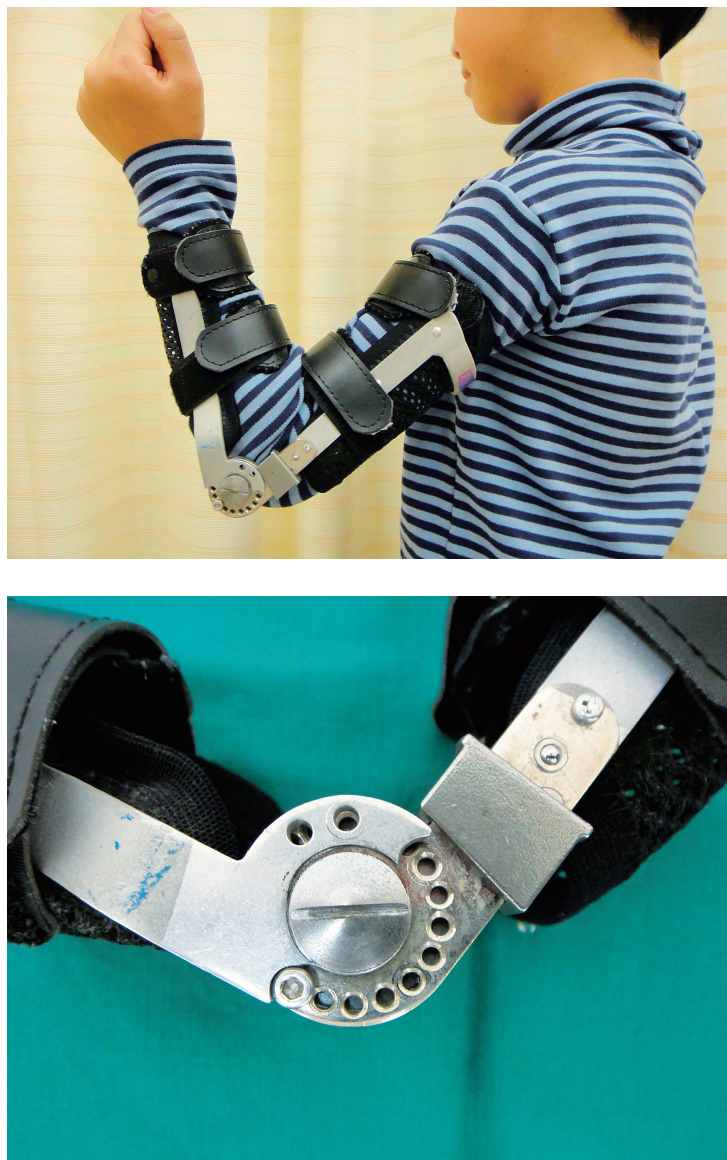

Fig. 4 Case 1, a 6-year-old boy. A) Photograph showing active range of motion exercises performed while wearing an adjustable hinged elbow splint that limits elbow extension. B) Photograph showing a hinge that can selectively control the range of elbow motion.

the control of the hinged splint. The patient was controlled to wear the splint all day for the first 4 weeks except bathing, and to hold the arm in 90 degree of flexion while bathing. Elbow extension reached full extension by 4 weeks after the commencement of exercise, then splinting was continued additional 2 weeks for prevention of elbow hyperextension. The splint was removed at 6 weeks. Plain radiography at 7 weeks after injury showed that the radial head was reduced in the full arc of pronation-supination motion. At 2 years and 3 months after injury, the patient had no pain and a full range of motion, and the radial head was reduced in all

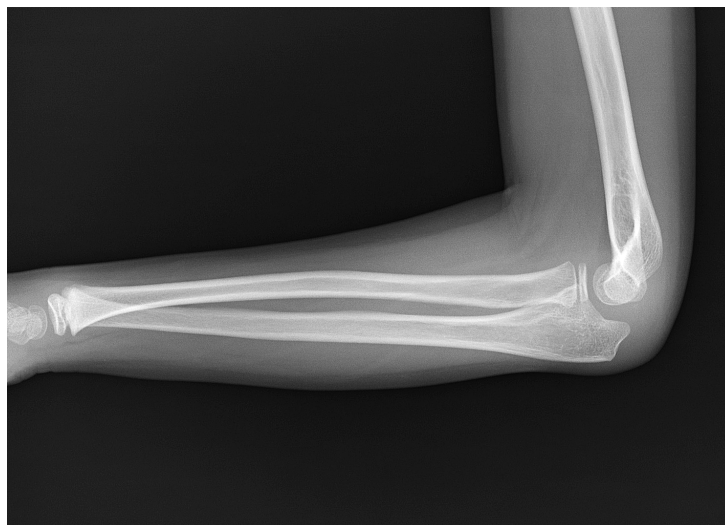

Fig. 5 Case 1, a 6-year-old boy. Lateral radiographs of the left forearm at 2 years and 3 months after injury, showing that the radial head was reduced in a pronation position.

positions on plain radiography (Fig. 5). The clinical outcome was excellent, as rated by Kim's elbow performance score⁶.

Case 2

A 9-year-old girl was referred to our hospital 12 days after injury complaining of pain and limited motion of her right elbow joint. She had radial head dislocation, but this had not been recognized by a local doctor. Physical examination revealed tenderness at the lateral side of the right elbow and the flexion-extension arc was 10 to 100 degrees, with 50 degrees of pronation and 50 degrees of supination. Plain radiography revealed anterior dislocation of the radial head with plastic bowing of the ulna. The ulnar bow rate of the affected side was 1.7% and that of the contralateral side was 0%.

Closed reduction was performed under general anesthesia at our hospital, but was only partly successful. Plain radiography showed that the ulnar bow rate improved to 1.1% and the radial head had been reduced in supination, but anteriorly dislocated in pronation, as also found in case 1. The arm was immobilized in a long arm cast with the elbow at 100 degrees of flexion, forearm and wrist in neutral position for 2 weeks after closed reduction. Subsequently, conservative treatment using a hinged splint was performed in the same manner as that in case 1. Plain radiography at 6 weeks after closed reduction showed that the radial head was reduced regardless of the forearm position. At 3 years and 4 months after injury, the patient had no pain and full range of motion, and the radial head was reduced in all positions on plain radiography. The clinical outcome was excellent based on Kim's elbow performance score.

DISCUSSION

Clinical and radiographic findings in traumatic bowing of the forearm were first reported by Borden⁷. This incomplete fracture is commonly seen in forearms of children⁸ and occurs by formation of slip lines or microfractures, which disrupt the collagen bundles and canaliculi of the

Haversian system⁹). Chamay¹⁰) demonstrated ulnar bowing deformity in dogs using longitudinal compression force and showed that plastic deformation resulted when the force exceeded the elastic limit but was below the fracture threshold. Plastic bowing is easily overlooked because of the lack of a visible cortical defect.

A Monteggia equivalent lesion, which involves radial head dislocation with traumatic bowing of the ulna, is also easily overlooked. Delays in correct diagnosis lead to increased morbidity and increase the risk of the need for open surgery to achieve reduction of the dislocated radial head³). Radial head dislocation with acute plastic bowing of the ulna in children can be treated by closed reduction, but manipulative reduction may not completely correct plastic bowing of the ulna⁷). It is important to confirm whether the radial head is reduced completely in full forearm rotation on radiographic examination, and careful attention is required when the ulnar bow rate after reduction does not reach that of the contralateral side.

In the cases reported here, the radial head was reduced in supination, but redislocated in a neutral to pronation position. In the second case, the 12-day interval from injury made it difficult to achieve complete reduction without open surgery. Incomplete reduction of the radial head is a candidate for open reduction surgery, but we chose conservative treatment using an adjustable hinged elbow splint. Open reduction can still be performed if this treatment fails. Tompkins¹¹) suggested over traction of biceps muscle as one of the mechanisms of the Monteggia lesion with an anterior radial head dislocation. By limiting elbow extension with a splint, we aimed to reduce the traction force of the biceps muscle on the radial head until soft tissue healing stabilized the radial head in a good position. We also think that stability of the radial head is provided due to the applied muscle contraction force in the axial direction of the forearm in the elbow flexion position. Prosupination motion was encouraged while limiting elbow extension, both to avoid contracture and to re-establish a good forearm prosupination axis.

Our splinting method is non-invasive and the two patients had good outcomes. Therefore, this method may be an option for treatment of incomplete reduction of radial head dislocation with acute plastic bowing of the ulna. However, if the annular ligament is interposed, the radial head would not reach stability in its normal position. Thus, evaluation of the condition of the injured annular ligament or capsule is required prior to commencing this conservative treatment. Ultrasonography provides a rapid, cost-effective, non-invasive, and dynamic method for examination of soft-tissue structures¹²) and is useful to evaluate the unossified epiphysis or to identify interposition of soft tissue between fracture fragments in the region of the elbow in infants and young children¹³). We have recently used ultrasonography to evaluate soft-tissue injuries around the elbow area and such diagnostic imaging is likely to enhance the reliability of our splinting treatment.

REFERENCES

- 1) Letts M. Dislocations of the child elbow. *In The elbow and its disorders*, 3rd ed, edited by Morrey BF. pp.288–315, 1996, Saunders, Philadelphia.
- 2) Dormans JP, Rang M. The problem of Monteggia fracture-dislocation in children. *Orthop Clin North Am*, 1990; 21: 251–6.
- 3) Sai S, Fujii K, Chino H, Inoue J. Radial head dislocation with acute plastic bowing of the ulna. *J Orthop Sci*, 2005; 10: 103–107.
- 4) Yamamoto M, Kino Y, Hattori Y, Uno A, Yamada T, Sakuma M. Dislocation of the radial head with acute plastic bowing of the ulna: Report of three cases. *Seikeigeka*, 2003; 54: 663–667. Japanese.
- 5) Lincoln TL, Mubarak SJ. “Isolated” traumatic radial-head dislocation. *J Pediatr Orthop*, 1994; 14: 454–457.
- 6) Kim HT, Park BG, Suh JT, Yoo CI. Chronic radial head dislocation in children, Part 2: results of open treatment and factors affecting final outcome. *J Pediatr Orthop*, 2002; 22: 591–597.

INCOMPLETE REDUCTION OF THE RADIAL HEAD

- 7) Borden S 4th. Traumatic bowing of the forearm in children. *J Bone Joint Surg Am*, 1974; 56: 611–616.
- 8) Komara JS, Kottamasu L, Kottamasu SR. Acute plastic bowing fractures in children. *Ann Emerg Med*, 1986; 15: 585–588.
- 9) Güleç A, Büyükbeci O. Traumatic bowing of the forearm in a child. *Eur J Radiol*, 1996; 23: 247–249.
- 10) Chamay A. Mechanical and morphological aspects of experimental overload and fatigue in bone. *J Biomech*, 1970; 3: 263–270.
- 11) Tompkins DG. The anterior Monteggia fracture: observations on etiology and treatment. *J Bone Joint Surg Am*, 1971; 53: 1109–1114.
- 12) Lee JC, Healy JC. Normal sonographic anatomy of the wrist and hand. *Radiographics*, 2005; 25: 1577–1590.
- 13) Davidson RS, Markowitz RI, Dormans J, Drummond DS. Ultrasonographic evaluation of the elbow in infants and young children after suspected trauma. *J Bone Joint Surg Am*, 1994; 76: 1804–1813.