

## CONGENIC STRAIN DIFFERENCES OF RENAL MALFORMATIONS IN ACI/MNA RATS BY INTROGRESSION OF THE CHROMOSOMAL REGION OF BUF/MNA RATS CONTAINING *PUR1*

MUTSUSHI MATSUYAMA<sup>1</sup>, CHIEMI HANEDA<sup>2</sup> and KAZUO KATO<sup>3</sup>

<sup>1</sup>*Department of Cell Biology and Anatomy, Fujita Health University School of Medicine, Toyoake-shi, Aichi-ken, Japan*

<sup>2</sup>*Education and Research Center of Animal Models for Human Diseases, Fujita Health University, Toyoake-shi, Aichi-ken, Japan*

<sup>3</sup>*Department of Pathology, Chubu Rousai Hospital, Nagoya, Japan*

### ABSTRACT

The ACI rats developed hereditary renal malformations including agenesis and hydronephrosis at moderate penetrance. During construction of a variety of congenic strains based on ACI/Mna (ACI), BUF/Mna (BUF), and WKY/NCrj (WKY) rats, we found that the renal malformations were significantly suppressed by introgression of a segment of chromosome 13 of BUF rats containing *Pur1* locus. It is plausible that this region contain a modifier locus influencing development of renal malformations.

Key Words: Renal agenesis, Hydronephrosis, ACI/Mna, ACI-Tsr1/Tsr1, BUF/Mna

#### Abbreviations:

Ten1	Thymus enlargement-1
Ten2	Thymus enlargement-2
Tsr1	Thymoma susceptible gene of rat-1
Pur1	Proteinuria-1

### INTRODUCTION

Occurrences of renal agenesis and hydronephrosis are well known in ACI rats.<sup>1-8)</sup> A semidominant locus in the vicinity of *D14Rat65* of Chromosome 14 has been shown responsible for renal malformation.<sup>9)</sup> However, the renal lesion is assumed to occur in a polygenic trait. In the course of the genetic study on thymoma developments of BUF/Mna rats,<sup>10,11)</sup> we noticed that moderate substrain differences in the incidences of the renal malformations were found among congenic strains of control ACI/Mna rats with introgressed chromosomal segments from BUF/Mna rats.

---

Received: June 11, 2013; accepted: June 21, 2013

Corresponding author: Mutsushi Matsuyama

Department of Cell Biology and Anatomy, Fujita Health University School of Medicine.  
Toyoake-shi, Aichi-ken 470-1192, Japan.

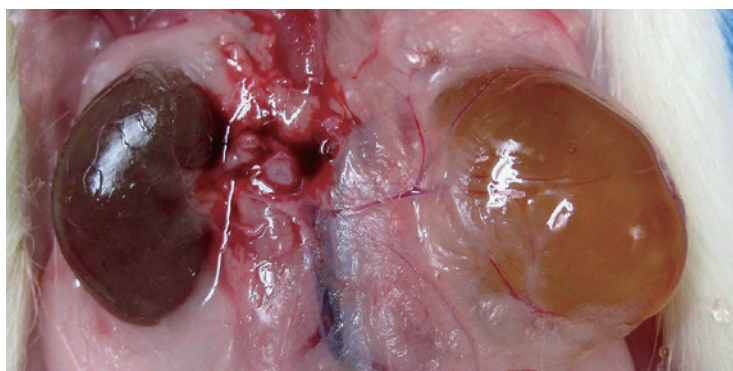
Tel: +81-562-93-2431, Fax: +81-562-93-4008. E-mail: mmatsuya@fujita-hu.ac.jp

## MATERIALS AND METHODS

The rats of the inbred ACI/Mna (ACI), BUF/Mna (BUF) and WKY/NCrj (WKY) strains, and of congenic strains, in which genetic regions of *rat nude (Rnu)*, *thymus enlargement-1 (Ten1)* and *thymus enlargement-2 (Ten2)*, *thymoma susceptible gene of rat-1 (Tsr1)*, *atrophy of fast-twitch muscle-1 (Aftm1)* and *proteinuria-1 (Pur1)* were transferred into ACI, BUF or WKY strain, respectively, were used.<sup>10,11</sup> The BUF-*Rnu*/+ rats were raised during the course of the establishment of the BUF-*Rnu/Rnu* strain, as described in the previous study.<sup>12</sup> They were housed with free access to food (CMF, Oriental Yeast, Tokyo, Japan) and tap water at the Animal Facility of Fujita Health University. All animal experiments were approved based on the approval of the Guide for the Care and Use of Laboratory Animals of Fujita Health University School of Medicine. Rats of these strains, as surpluses in the course of the maintenance of the strains, were killed at the age of 6–104 weeks, except 3 rats died of bilateral renal malformations 1–5 days after birth. Autopsies were performed and kidneys were macroscopically examined. The statistical analyses were carried out by the Fisher's exact test.

## RESULTS

ACI and their congenic rats developed unilateral renal agenesis and hydronephrosis (Fig. 1) in 1–13 %, but BUF and WKY, and their congenic rats hardly developed. Since there were no sex differences in the incidences in renal agenesis and hydronephrosis in these strains, the data for both sexes were accumulated (Table 1). Higher incidences of renal agenesis in the right side and hydronephrosis in the left side, respectively, were observed. Three rats died 1–5 days after birth; 1 developed no kidneys in bilateral sides and other 2 did bilateral hydronephrosis (Table 1). Statistically, lower incidences of these developmental abnormalities were found in rats of the ACI-*Pur1* and ACI-*Pur1-Ten2* strains than ACI, ACI-*Tsr1*, ACI-*Ten1*, and ACI-*Aftm1* strains (Table 1).



**Fig. 1** Hydronephrosis of the left kidney of a male albino ACI-*Aftm1* rat.

## STRAIN DIFFERENCES OF RENAL ABNORMALITIES

**Table 1** Incidences of renal agenesis and hydronephrosis in rats of both sexes of the ACI, BUF, and WKY strains and their congenic strains

Strain	No. of rats	No. & (%) of renal agenesis			No. & (%) of hydronephrosis		
		Right	Left	Bilateral	Right	Left	Bilateral
ACI	84	5 (6) <sup>1</sup>	5 (6) <sup>7</sup>	0 (0)	1 (1)	7 (8) <sup>14</sup>	0 (0)
ACI- <i>Tsr1</i>	76	4 (5) <sup>2</sup>	3 (4) <sup>8</sup>	0 (0)	0 (0)	3 (4)	1* (1)
ACI- <i>Ten1</i>	251	23 (9) <sup>3</sup>	4 (2)	0 (0)	4 (2)	9 (4)	0 (0)
ACI- <i>Aftm1</i>	340	32 (9) <sup>4</sup>	12 (4) <sup>9</sup>	0 (0)	9 (3) <sup>11</sup>	33 (10) <sup>15</sup>	1** (0.3)
ACI- <i>Pur1</i>	180	1 (1) <sup>5</sup>	1 (1) <sup>10</sup>	0 (0)	0 (0) <sup>12</sup>	1 (1) <sup>16</sup>	0 (0)
ACI- <i>Pur1-Ten2</i>	165	4 (2) <sup>6</sup>	6 (4)	0 (0)	0 (0) <sup>13</sup>	1 (1) <sup>17</sup>	0 (0)
BUF	90	0 (0)	0 (0)	1 <sup>#</sup> (1)	0 (0)	5 (6)	0 (0)
BUF- <i>Rnu+</i>	185	0 (0)	0 (0)	0 (0)	1 (1)	3 (2)	0 (0)
WKY	162	0 (0)	0 (0)	0 (0)	0 (0)	0 (0)	0 (0)
WKY- <i>Tsr1</i>	346	0 (0)	0 (0)	0 (0)	0 (0)	0 (0)	0 (0)
WKY- <i>Ten1-Ten2</i>	71	0 (0)	0 (0)	0 (0)	0 (0)	0 (0)	0 (0)
WKY- <i>Ten2</i>	22	0 (0)	0 (0)	0 (0)	2 (9)	1 (5)	0 (0)
WKY- <i>Pur1-Ten1-Ten2</i>	213	0 (0)	0 (0)	0 (0)	0 (0)	0 (0)	0 (0)

The statistical analyses were carried out by the Fisher's exact test.

<sup>5:3,4</sup> Highly significant; <sup>5:1,2</sup> significant; <sup>6:3,4</sup> highly significant;

<sup>10:7,8,9</sup> Significant; <sup>12:11</sup> significant; <sup>13:11</sup> significant;

<sup>16:14,15</sup> Highly significant; <sup>17:14, 15</sup> highly significant.

\*Died 5 days after birth. The rats had bilateral hydronephrosis.

\*\*Died 2 days after birth. The rats had bilateral hydronephrosis.

<sup>#</sup>Died 1 day after birth. The rat had no kidneys in both sides.

## DISCUSSION

The unilateral renal agenesis, hydronephrosis, and associated genitourinary anomalies in ACI rats were thought to be a part of a mesonephric duct defect.<sup>13</sup> The inheritance of the unilateral renal agenesis is believed to be polygenic<sup>2</sup> and one of the genes for unilateral renal agenesis was mapped on chromosome 14.<sup>2,14</sup> The present study revealed that the renal agenesis and hydronephrosis were significantly suppressed by the insertion of the genetic region of *proteinuria* in ACI-*Pur1* and ACI-*Pur1-Ten2* rats originated from BUF rats. Conversely, it means that the *Pur1* region of ACI rats contains a second gene for the induction of renal malformations. We previously showed that genetic *Pur1* region was located on the chromosome 13 and that the genetic *Pur1* region contained 38 genes,<sup>15</sup> which should be analyzed by molecular methods.

The present study also showed that ACI rats developed unilateral hydronephrosis more in the left side. The exact mechanism why unilateral hydronephrosis occurs more in the left side is not known. Explanations for this difference between sides have to be elucidated.<sup>16,17</sup>

## REFERENCES

- 1) Fujikura T. (1970) Kidney malformations in fetuses of A x C line 9935 rats. *Terat.* 3, 245–249.
- 2) Cramer D.V., Gill T.J. IIIrd. (1975) Genetics of urogenital abnormalities in ACI inbred rats. *Terat.* 12, 27–32.
- 3) Fujita K., Fujita H.M., Ohtawara Y. *et al.* (1979) Hydronephrosis in ACI/N rats. *Lab Anim.* 13, 325–327.
- 4) Solleveld H.D., Boorman G.A. (1986) Spontaneous renal lesions in five rat strains. *Toxicol Pathol.* 14, 168–174.

- 5) McPherson E., Hall J.G., Pauli R.N. *et al.* (1987) Dominantly inherited renal dysplasia. *Am J Med Gen.* 26, 863–872.
- 6) Kneidl M., Shibasaki Y., Komitowski D. (1995) Trisomy 8 and urogenital malformation in the ACI-rat. *Hereditas* 123, 97–101.
- 7) Brown D.M., Provoost A.P., Daly M.J. *et al.* (1996) Renal disease susceptibility and hypertension are under independent genetic control in fawn-hooded rat. *Nat Genet.* 12, 44–51.
- 8) Amakasu K., Suzuki K., Suzuki H. (2009) The unilateral urogenital anomalies (UUA) rat: a new mutant strain associated with unilateral renal agenesis, cryptorchidism, and malformations of reproductive organs restricted to the left side. *Comp. Med.* 24, 249–256.
- 9) Yamashita S., Suzuki S., Nomoto T. *et al.* (2005) Linkage and microarray analyses of susceptibility genes in ACI/Seg rats: A model for prostate cancers in the aged. *Cancer Res.* 65, 2610–2616.
- 10) Matsuyama M., Kato K., Higo-Moriguchi, K. *et al.* (2008) Establishment of thymoma-prone congenic rat strain, ACI.BUF/Mna-Tsr1/Tsr1. *J. Cancer Res. Clin. Oncol.*, 134, 789–792, 2008.
- 11) Yamada T., Matsuyama M., Yanagida T. *et al.* (2011) Cervical thymuses exist, but no cervical thymomas develop in thoracic thymomas-prone BUF rats. *Int. J. Exp. Path.* 92, 117–120.
- 12) Matsuyama M., Kojima A., Katoh H. *et al.* (1989) Establishment of a congenic nude strain of rats, BUF/Mna-rnu. Suppression of thymomagenesis in heterozygous rats. In: *Immune-Deficient Animals in Experimental Medicine*, pp. 27–31 (eds B.-q. Wu, J. Zheng), Basel: Karger.
- 13) Marshall F.F., Garcia-Bunuel R., Beisel R. (1978) Hydronephrosis, renal agenesis, and associated genitourinary anomalies in ACI rats. *Urology* 11, 58–61.
- 14) Shull J.D., Lachel C.M., Strecker T.E., *et al.* (2006) Genetic bases of renal agenesis in the ACI rat: mapping of Renag 1 to chromosome 14. *Mamm Genome* 17, 751–759.
- 15) Akiyama K., Morita H., Suetsugu S. *et al.* (2008) Actin-related protein 3 (Arp3) is mutated in proteinuric BUF/Mna rats. *Mamm. Genome* 19, 41–50.
- 16) Sakuma R., Ohnishi Y., Meno C. *et al.* (2002) Inhibition of nodal signaling by lefty mediated through interaction with common receptors and efficient diffusion. *Genes Cell.* 401–412.
- 17) Schreuder M.F. (2011) Unilateral anomalies of kidney development: why is left not right? *Kidney Internat.* 80, 740–745.