Nagoya J. Sci. 34: 191-197, 1971

A STUDY OF INCREASED PERMEABILITY OF VASA VASORUM*

TAKASHI YANO

1st Department of Surgery, Nagoya University School of Medicine
(Director: Associate Prof. Itsuro Fukukei)

ABSTRACT

The following experiments were made to examine the increased permeability of vasa vasorum. Dogs of approximately 10 kg body weight were anesthetized by intraperitoneal injection of 30 mg/kg of pentobarbiturate. One ml of 5 μg/ml bradykinin solution in saline was iufiltrated around the tissues of the exposed carotid arteries and iliac arteries respectively. Immediately afterwards 50 ml of homologous serum protein combined with fluorescent dye was injected intravenously. The vessels were removed 2 to 8 minutes after the injection of the dye. The removed vessels were observed under a fluorescence microscope. The intima was peeled to make the material transparent which was essential for the microscopic observation. Control experiments were made by using normal saline in the same operative procedure. Vasa vasorum of the arteries were distinctly seen emitting green fluorescence. Leakage was most prominent from venules of 20 to 30 μ in diameter, especially at the branching junctions, but no leakage was found along arterioles. The fact that bradykinin increases permeability of vasa vasorum suggests an important role on the venular side of vasa vasorum in the pathogenesis of vasular diseases.

INTRODUCTION

The wall of blood vessels is doubly nourished from the inside and outside. While the intima and the inner third of the media are thought to be nourished by imbibition from the lumen, the adventitia and the outer third of the media are thought to be nourished by blood supply from the vasa vasorum. In comparison with the former, the latter blood supply has not received much attention in physiological and pathological studies though the existence of vasa vasorum has been known for over a hundred years[1], and was reviewed by Ramsey[2] in 1936, because lipid metabolism in arterioselerosis[3] has been investigated chiefly from the view point of imbibition from the lumen and partly because of methodological difficulties in spite of the great effort to demonstrate vasa vasorum[4]. Recently, the establishment of microangiographical technique[5] and its practical

矢　野　　孝

Received for publication February 27, 1971.

* This work was supported by The Institute for Protein Research, Osaka University (Director: Prof. Tomoji Suzuki). And an outline of the present paper was read at the 9th Congress of Japanese College of Angiology on November 15, 1968.

application have been contributing to the morphological study of vasa vasorum[6], but they are not always adequate in physiological studies of vasa vasorum.

The present experiments were designed to evaluate the role of the vasa vasorum in the pathogenesis of vascular diseases. Bradykinin[7] solution in saline was used to determine functional disorder of the vasa vasorum. When leakage of blood or its constituents from the vasa vasorum exists, it would suggest the possible presence of resulting vascular diseases caused by primary disorder of the vasa vasorum. Homologous serum protein combined with fluorescent dye was used to make the phenomenon of leakage visible under a fluorescence microscope. This made it possible to comprehend the phenomenon of leakage, because fluorescent dye loses its pharmacological activity by being combined with serum protein.

EXPERIMETAL PROCEDURE

Preparation of Homologous Serum Protein Combined with Fluorescent Dye

Fifty mg of 5-dimethylamino-1-naphthalene sulfonyl chloride was dissolved in 1 ml of slightly warmed methanol. This solution was added to 50 ml of homologous dog serum drop by drop with thorough mixing. The mixture was kept for ten minutes at room temperature to promote combination of the serum protein with fluorescent dye. Then methanol, the solvent of dye, and excessive fluorescent dye which did not combine with the serum protein were removed by dialysis against 2,000 ml of normal saline. The protein combined with fluorescent dye described above is to be noticed at one hundredth concentration[8] of other pigments.

Method

Dogs of approximately 10 kg body weight were anesthetized by intraperitoneal injection of 30 mg/kg of pentobarbiturate. First, the carotid arteries and iliac arteries of both sides were exposed. One ml of 5 μg/ml bradykinin solution in saline was infiltrated in the tissues around each exposed vessel. Immediately afterwards 50 ml of the serum protein combined fluorescent dye was injected intravenously. The vessels were removed 2 to 8 minutes after injection of the dye. Control experiments were made using normal saline in stead of bradykinin solution under the same operative procedure. The removed vessels were kept in saline to prevent from drying. The intima was peeled off to make the material transparent, which was essential to observation under a fluorescence microscope.

RESULTS

Vasa vasorum of the arterial wall were distinctly seen under a fluorescence microscope emitting green fluorescence. There was observed leakage of blood or its constituents containing fluorescent dye in the bradykinin infiltrated group.

The leakage reached a peak 4 min. after the infiltration and the intensity of leakage 6 min. after the infiltration was almost equal to that 8 min. after. No appreciable differences were observed in the vasa vasorum of the carotid and iliac arteries. The dogs injected with homologous serum protein (combined with fluorescent dye) never showed any change in general condition, such as shock.

Control Group

No leakage was seen from the vasa vasorum of dog's carotid artery around which normal saline was infiltrated in stead of bradykinin solution (Fig. 1). The hook-shaped vessel in Fig. 1 was a venule of approximately 50 μ in diameter which was differentiated by tracing it from a small vein under the microscope.

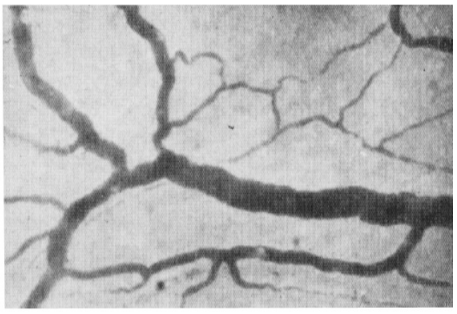

FIG. 1. Vasa vasorum of dog's carotid artery (control).

Bradykinin Infiltrated Group

1. Leakage from venules

There could be observed prominent leakage from the vasa vasorum caused by the infiltration of bradykinin around the tissues of the dog's carotid artery (Fig. 2) and iliac artery (Fig. 3). The leakage spread in circular or semicircular shape surrounding the branching junctions of venules of the vasa vasorum.

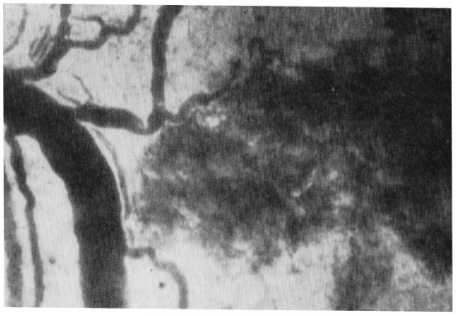

FIG. 2. Venular leakage of vasa vasorum of dog's carotid artery. 4 min. after bradykinin infiltration.

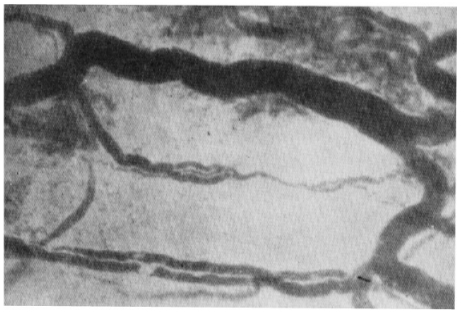

FIG. 3. Venular leakage of vasa vasorum of dog's iliac artery. 6 min. after bradykinin infiltration.

2. Leakage from capillaries

Leakage was often seen in the capillaries. The shape and site of capillary leakage were similar to those of venular leakage, but it was less intense and small in extent (Fig. 4 and Fig. 5).

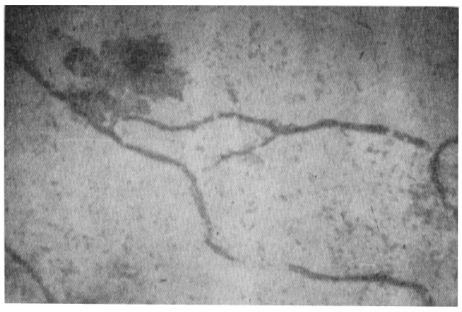

FIG. 4. Capillary leakage of vasa vasorum of dog's carotid artery. 6 min. after bradykinin infiltration.

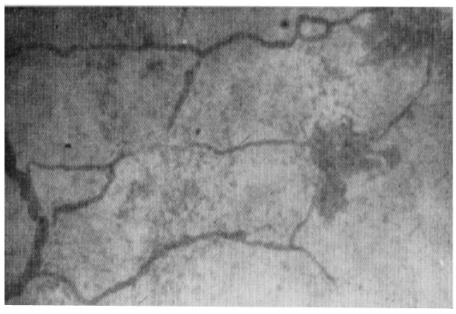

FIG. 5. Capillary leakage of vasa vasorum of dog's carotid artery. 6 min. after bradykinin infiltration.

3. Leakage from arterioles

No leakage was observed along the arterioles. In Fig. 6 arterioles and venules were differentiable by tracing them from small arteries and veins under the microscope. No leakage was noticed along the arterioles, while venules showed prominent leakage (Fig. 6 and Fig. 7).

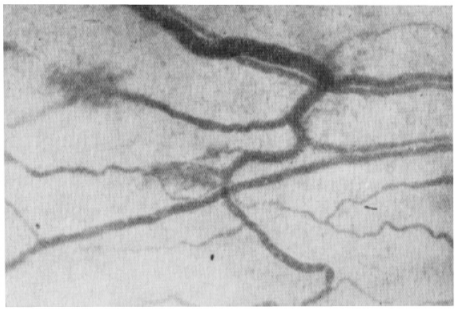

FIG. 6. Vasa vasorum of dog's carotid artory. Arterioles and venules are differentiable. Leakage occurs from venules and not from arterioles. 6 min. after bradykinin infiltration.

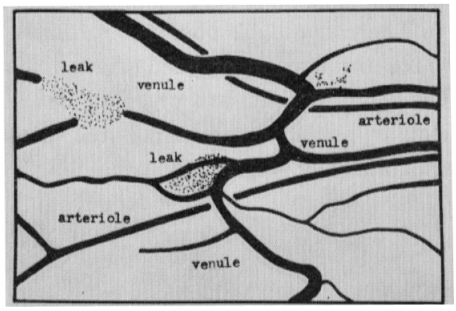

FIG. 7. Illustration of FIG. 6.

DISCUSSION

In 1936 Menkin[9] noticed the presence of permeability increasing substance in inflammatory exudate. This substance was named leukotaxin from its leukotaxic action. But this substance was not accepted to increase permeability directly, as histamine was then the only substance known to increase permeability, and Rocha e Silva, who in 1949[7] reported on bradykinin, considered at that time that the permeability increase action of leukotaxin was manifested through the release of histamine. Bradykinin was released from plasma globulin by snake venom and trypsin. It caused the basic reactions of inflam-

mation, namely, increased permeability, leukotaxis, pain production, vasodilatation, etc. Above all, the prominent exudation caused by bradykinin as the result of increased permeability excited the attention of investigators, because it was the most characteristic feature of inflammation. Thus, histamine conceded its primary status as a chemical mediator of inflammation to bradykinin. On the other hand Lewis[10] noticed that kinin releasing activity of lymph in traumatic tissue could be blocked by antihistamic agents. He concluded from this observation that histamine increased as a first step in traumatic tissue and leakage of plasma from capillaries resulted. Next, kinin releasing enzyme in plasma produced kinins, and the inflammatory process occurred. Thus the notion that bradykinin is the second phase mediator of inflammation was generally accepted in spite of some objections[11].

Homeostasis of the vascular wall is maintained by the perfusion system which is composed of intimal imbibition of plasma constituents, import and transport through the vasa vasorum and lymphatic drainage. According to Doerr[12] the imbibed plasma constituents flow in the vascular wall forming a "Flüssigkeitsstrasse" which runs longitudinally under the endothelial lining. In other words, the vascular wall is bathed in plasma constituents constantly and metabolic process may occur intramurally. An impediment to the flow and absorption by the vasa vasorum of these plasma constituents may lead to deposition with mischievous side effect resulting in arteriosclerosis[13].

It is, however, quite reasonable to assume that the vasa vasorum are also susceptible to inflammation. When the vasa vasorum are involved in inflammatory process, increased permeability occurs and exudation of various substances from vasa vasorum into vascular wall will result. This may produce a breakdown of maintaining homeostasis in the vascular wall, and edematous change in the vascular wall will appear as a result of the retention of plasma constituents in the vascular wall. Doerr referred the disturbed homeostasis of vascular wall perfusion to the elevation of edematous intima and dissecting phenomenon observed in arteriosclerotic vessels.

The question on the site and mechanism of leakage has received the attention of many investigators. In the present experiments bradykinin induced leakage at the venular side of the vasa vasorum. Rous and his colleagues[14] thought that the walls of minute vessels were relatively impermeable near the arterioles but became increasingly permeable as the venules and veins were approached. This was not contradictory to Zweifach's description[11] that indications of permeability developed in the postcapillaries and collecting venules. The author observed leakage occurring along venules of 20 to 30 μ in diameter especially at the branching junctions. One clue to the solution of why leakage occurred at the venular side and not at the arteriolar side was given by Majno *et al.*[15], who discovered endothelial gaps in the inner surface of venules. These venules with endothelial gaps were called leaking vessels. Many in-

vestigations have been made to demonstrate the relationship of disturbance of vasa vasorum to vascular diseases. Shionoya and Griss[16] noticed that recurrent provocation of Arthus's phenomenon in the neighbourhood of the abdominal aorta and common iliac arteries of rats was followed by mural thrombosis, intimal proliferation, diffuse thickening of the vessel wall, localized cystic degeneration of the media and marked fibrosis of the adventitia. It is not unreasonable to suppose the existence of venular leakage and disturbance of vascular wall perfusion when Arthus's phenomenon occur in the vasa vasorum. Moreover, the vasa vasorum play an important role as the pathway by which pathological changes around the adventitia may extend to the media and intima.

Further studies are needed to correlate the anatomical and pathological relationship between the vasa vasorum and the lymphatics.

SUMMARY

These experiments were designed to demonstrate leakage of blood or its constituents from the vasa vasorum into the vascular wall by inducing inflammation with the aid of bradykinin. Serum protein combined with fluorescent dye was used to comprehend the leakage under physiological conditions. Leakage was most prominent at the venular side of the vasa vasorum. This fact suggests an important role of the venular side of the vasa vasorum in the pathogenesis of vascular diseases.

ACKNOWLEDGEMENT

The author thanks Associate Prof. Dr. I. Fukukei and Prof. Dr. K. Takagi for their interest and reviews, and to Dr. K. Kamiya and Dr. T. Takao for their suggestions. The author also wishes to thank Dr. S. Shionoya and Dr. K. Hayashi for their cooperation and guidance.

REFERENCES

1) Rotitansky, C., *In* A Manual of Pathclogical Anatomy, Translated by Moore, C. W., Blanchard-Lea, Philadelphia, 1855, Vol. 4, p. 200 (Cited in LeCompte, P. M.[4]).
2) Ramsey, E. M., Nutrition of the vessel wall, review of the literature, *Yale J. Biol. Med.*, **9**, 14, 1936-37.
3) Gofman, J. W., Jones, H. B., Lingren, F. T.. Lyon, T. P., Elliott, H. A. and Strisower, B., Blood lipids and human atherosclerosis, *Circulation*, **2**, 161, 1950.
4) LeCompte, P. M., Reactions of the vasa vasorum in vascular disease, *In* Cowdry's Arteriosclerosis, 2nd edition, Edited by Blumenthal, T. H., Thomas, Springfield, 1967, pp. 212-224.
5) Clarke, J. A., An X-ray microscopic study of the vasa vasorum of the normal human coronary arteries, *J. Anat.*, **98**, 539, 1964.
6) Nakata, Y. and Shionoya, S., Vascular lesions due to obstruction of the vasa vasorum, *Nature (London)*, **212**, 1258, 1966.

7) Rocha e Silva, M., Beraldo, T. and Rosenfeld, G., Bradykinin, a hypotensive and smooth muscle stimulating factor released from plasma globulin by snake venoms and by trypsin, *Amer. J. Physiol.*, **156**, 261, 1949.
8) Krieg, A., Fluorescenzanalyse und Fluorochromie in Biologie und Medizin, *Klin. Wschr.*, **31**, 350, 1953.
9) Menkin, V., Studies on Inflammation, XII, Mechanism of increased capillary permeability, a critique of the histamine hypothesis, *J. Exp. Med.*, **64**, 458, 1936.
10) Lewis, G. P., Plasma kinins and other vasoactive compounds in acute inflammation, *Ann. NY Acad. Sci.*, **116**, 847, 1964.
11) Zweifach, B. W., Microcirculatory effects of polypeptides, *In* Hypotensive Peptides, Edited by Erdös, E. G., Back, N. and Sicuteri, F., Springer, Berlin, 1966, pp. 451–462.
12) Doerr, W., Perfusionstheorie der Arteriosklerose, Thieme, Stuttgart, 1963.
13) Johnson, R. A., Lymphatics of blood vessels, *Lymphology*, **2**, 44, 1969.
14) Rous, P., Gilding, P. and Smith, F., The gradient of vascular permeability, *J. Exp. Med.*, **51**, 807, 1930.
15) Majno, G., Palade, G. E. and Schofl, G. I., Studies on inflammation, II, The site of action of histamine and serotonin along the vascular tree, a topographic study, *J. Biophys. Biochem. Cytol.*, **2**, 607, 1961.
16) Shionoya, S. and Griss, P., Zur Pathogenese der Takayasu-Krankheit, Arthusphänomen an den Vasa vasorum, *Virchow Arch (Path Anat)*, **348**, 269, 1969.