Nagoya J. med. Sci. 34: 297-302, 1972

RENAL GLOMERULOGRAPHY IN FOURFOLD MAGNIFICATION

MASAO KANEKO AND SADAYUKI SAKUMA*

Department of Radiology, Nagoya University School of Medicine
(Director: Professor Shinji Takahashi)

ABSTRACT

Selective renal angiogrgphy in 7 patients with normal kidneys, taken in fourfold magnification, using a special X-ray tube with a very fine focal spot less than 0.05 mm in diameter, revealed numerous small linear shadows of interlobular arteries accompanied with small granular punctiform shadows of glomeruli in the cortex, as well as in the medulla.

In order to obtain the glomerular phase of opacification after injection of contrast media through the Odman's green cathter, serial angiograms were taken with one film per second for 5 to 10 seconds. Similar small granular punctiform shadows were seen in magnified angiograms using the same technique in the kidney of a living dog. These shadows were verified, by means of microangiography, to be glomeruli and interlobular arteries.

In 1964, the possibility was first postulated[7], to visualize the renal glomeruli by using renal arteriography in four-fold roentgenographic magnification and later verified histologically. This work was reported in 1966[3]. In this communication, some of the experimental works are rewritten and more convincing glomerulograms of normal human kidneys are illustrated.

The term "Glomerulography" was first used by T. Takaro[16]. The glomerulogram is distinguished as a particular phase of renal vascular opacification from renal arteriogram, nephrogram and phlebogram. Therefore, the term "Glomerulography" is especially suitable when the object of angiography is aimed at radiography of glomeruli, because a glomerulogram is a part of renal arteriography.

I. EXPERIMENTAL GLOMERULOGRAPHY

Materials and Methods

Healthy mongrel dogs weighing from 3 to 5 kg. were anesthetized by intravenous administration of pentobarbital sodium, 30 mg. per kg. of body weight. The trachea was intubated so as to control the respiration and to

金子昌生，佐久間貞行
Received for publication February 2, 1972.
* Professor of Radiology, Nagoya City University School of Medicine.

limit the voluntary movement during the X-ray exposures. Ether was also added, when necessary, to the oxygen mixture. The animal was fixed in the supine position on a roentgenographic table. Femoral artery was catheterized by Seldinger's method[8] with a red Ödman's catheter[6]. The curved tip of the catheter was wedged into a renal artery under fluoroscopic guidance. As a contrast media, 0.5 to 3.0 cc of 76% diatriozate or 80% iothalamate was used. Serial exposures starting simultaneously with the injection, one exposure per 1 to 2 seconds, were made for macroroentgenography by a special X-ray tube[10)~15)] using Kodak Royal blue brand films with medium speed screen. Thereafter, conventional serial renal arteriography was performed for comparison with the macroroentgenography. After the injection of contrast media, saline solution was infused into the catheter in order to prevent coagulation.

After these procedures, the kidney was removed and microfine barium sulphate suspension was injected into the renal artery in a sufficient amount and a macroroentgenogram of the kidney specimen was taken. Then, the kidney was fixed in 10% formalin solution for 10 days, and sliced in 3 mm thick sections. Each piece of the sliced kidney was radiographed in 25 KVp, using Fuji Industrial X-ray film type 80. Such microangiograms were enlarged photographically to the same size as the macroroentgenogram of the kidney.

Results

On the renal arteriogram of the living dog, one second after injecticn of contrast media, the main renal, interlobar and arcuate arteries were visualized (Fig. 1, A), but the minor branches were not seen even though it was enlarged photographically to the size of macroroentgenogram (Fig. 1, B).

However, on the four-fold macroroentgenogram of the same kidney (Fig. 1, C), numerous interlobular arteries were visualized mainly in the cortex as brush-like appearance. In addition, small granular punctiform shadows of the size of millet seeds were seen abundantly among these linear shadows of interlobular arteries.

In order to elucidate the nature of these shadows, the kidney was removed and the barium sulphate suspension was injected into the renal artery. Then the macroroentgenogram of the specimen was obtained (Fig. 2, A). Compared with the living dog, linear and granular shadows were clearly visualized, because the barium is higher in contrast than diatriozate or iothalamate and no filtration from vascular to urinary space in the glomeruli could have occurred. Moreover, nothing is overlapped with the kidney in a removed specimen. After fixation by formalin, the specimen was sliced and soft X-rayed (Fig. 2, B). On this 4-times magnification (Fig. 2, C), the arcuate arteries branched into many interlobular arteries like twigs of trees.

Resembling fruits on trees, the linear shadows were accompanied by numerous punctiform round shadows, approximately of the tendency of smaller sized shadows in the cortex to larger ones in the medulla.

Considering that each punctiform shadow is always connected with the arterial branches, it is evident that such punctiform ahadows are nothing but glomeruli from the anatomical point of view.

Therefore, linear and punctiform shadows seen in the fourfold macroroentgenogram of the living dog were verified as interlobular arteries and glomeruli.

II. NORMAL GLOMERULOGRAPHY IN MAN

Materials and Methods

In seven patients without any clinically evident renal disease, renal angiography was performed to investigate the normal glomerulogram in man. The patient was placed in a supine position on the roentgenographic table. After local anesthesia of the femoral region, the Ödman's green catheter[6] was inserted into the femoral artery by Seldinger's technique[8]. Under X-ray television control, the curved tip was wedged into the renal artery. The confirmation was made by flush injection of a small amount of contrast media. Six to 10 cc of 60% diatriozate or iothalamate was used as a contrast medium.

In conventional radiography, injection was made under the pressure of 1.0 kg per cm^2 by Gidlund automatic injector. In macroroentgenography, however, manual injection was employed. In both techniques, serial angiography was performed for 5 to 10 seconds. In the conventional, one to two exposures per second were made with factors of 80 to 95 KVp, 300 mA and 0.05 to 0.06 sec. using an X-ray tube wtih a focal spot of 2 mm in diameter. In macroroentgenography, one exposure was made per second with factors of 125 KVp, 3 mA and 0.2 to 0.5 sec. using a special X-ray tube[9)~15)], with a very fine focal spot less than 0.05 mm in diameter (Toshiba DRX 89 H No. 5509).

In macroroentgenography, the distance from the focal spot of the X-ray tube to the roentgenographic table was fixed at 25 cm and from the focus to the X-ray film cassette at 100 cm (Fig. 3).

Results

In all the seven patients glomerulography with normal kidneys was studied successfully.

The right kidney of a 51 years old man will be shown in this report.

In a conventional roentgenogram, one second after contrast injection, the main renal, interlobar and arcuate arteries were observed and the interlobular arteries were scarcely seen (Fig. 4, A). In the late phase of the arteriogram, 7 seconds after infection of contrast media, interlobar and arcuate arteries were seen in the background of the nephrogram (Fig. 4, B).

However, in the macroroentgenogram, even in an early phase of arteriography, one second after injection of contrast media, interlobular arteries and glomeruli were observed in a part (arrow) as well as arcuate, interlobar and main renal arteries (Fig. 5, A). In the late arterial phase, 7 seconds after contrast injection, numerous granular shadows were detected mainly in the cortex as well as in the medulla (Fig. 5, B).

There is no doubt that these granular punctiform shadows are glomeruli considering the verification of the fact in animal experiments.

Discussion

It is not adequate to study the renal vascular trees using celloidine[2] and neoprene[5] methods especially from the pathologic standpoint[1], because of the unavoidable destruction of the kidney tissue.

The use of radiopaque injection for the study of renal circulation dates back almost as far as the diagnostic use of Roentgen rays. In 1928, R. S. Graham[1] succeeded in the roentgenographic visualization of glomeruli by injecting a 17% suspension of bismuth oxychloride in water containing 10% acacia, into the renal artery of the kidneys obtained at necropsies. But this contrast material can not be used for actual renal angiography.

In our previous report[3], we showed the roentgenographic visualization of glomeruli both *in vitro* and *in vivo* by 4 times roentgenographic magnification of the renal vasculture, using a special X-ray tube with a very fine focal spot less than 0.05 mm in diameter[9)~15)]. With this tube, fourfold magnification is the most appropriate size for macroroentgenography from the standpoint of optical transfer function (OTF) or modulation transfer function (MTF)[10].

Formerly the capacity of the tube was limited to 2 mA with rotating anode of 3,000 rpm. But now the tube is capable of 3 mA with 9,000 rpm. Therefore, it is usually possible to take a macroroentgenogram of the renal vasculture with 125 KVp and time variation of 0.2 to 0.5 sec.

Recently, T. Takaro[16] succeeded also in visualization of the glomeruli of the canine kidney in a single magnified film, coinciding with the glomerular phase of opciafication by the use of momentary renal circulation arrest produced by inflating a balloon catheter in the abdominal aorta at the renal artery orifice during the radiopaque injection through a second catheter.

He used the 0.3 mm focal spot of the Siemens roentgen tube at 100 mA., approximately 64 to 76 KVp., and 0.12 to 0.24 sec.. As he mentioned, canine glomeruli ordinarily measure approximately 200 to 300 microns in diameter after death of the animal, fixation of the tissue and staining. The good delineation of glomeruli with a focal spot of 0.3 mm diameter leads to the assumption that renal glomeruli have a larger diameter than those seen in a fixed state, during momentary cessation of renal blood flow and pressure injection of contrast media, considering the penumbra it produces.

With a conventional renal arteriography, glomeruli can be demonstrated in cases of hydronephrosis because of the enlarged glomeruli, but more clearly seen by 4-times magnified macroroentgehography. Therefore, the special X-ray tube[9)~15)] has the potentiality to demonstrate clearly the glomeruli even in a normal state without recognizable penumbra.

In our method, serial angiograms were made in order to catch the glomerular phase of opacification after injection of contrast media through the Ödman's green catheter into the renal artery. It is easier to make glomerulograms and conventional renal arteriograms with the same procedures.

In fact, macroroentgenography is a more detailed examination than the conventional method. Therefore, a glomerulogram is also very helpful to see in detail a part of a kidney after conventional renal angiography. In our next report[4)], clinical application of glomerulography will be described.

REFERENCES

1) Graham, R. S.: A study of the circulation in the normal and pathologic kidney with roentgenographic visualization of the arterial tree, including the glomeruli, *Am. J. Pathology.*, **4**, 17, 1928.
2) Huber, G. C.: The arteriolae rectae of the manmalian kidney, *Am. J. Anatomy.*, **6**, 391, 1906–7.
3) Kaneko, M.: Angiography in four times magnification applied to kiduey of living human body, *Nippon acta radiol.*, **26**, 55, 1966.
4) Kaneko, M., Renal Glomerulography in the diagnosis of renal tumor (in preparation).
5) Moore, G. C. and Duff, G. L.: The renal arterial vasculture in man, *Am. I. Pathology.*, **27**, 95, 1951.
6) Ödman, P.: The radiopaque polythene catheter, *Acta radiol.*, **52**, 52, 1959.
7) Sakuma, S., Kaneko, M., Koga, S., Takeuchi, A. and Ikeda, H.: Studies of macroroentgenography. Observation of fine arterial structure by macroroentgenography, *Nippon acta radiol.*, **24**, 766, 1964.
8) Seldinger, S. I.: Catheter replacement of the nesdle in percutaneous arteriography. *Acta radiol.*, **36**, 368, 1953.
9) Takahashi, S., Komiyama, K. and Tanaka, M.: A fixed anode tube with a very fine focus made with autobiased electron beam, *Tohoku I. exp. Med.*, **62**, 253, 1955.
10) Takahashi, S., Sakuma, S. and Ayakawa, Y.: Der Vergrösserungs Aufnahmen Technik. Der Radiologe. **8**, Nr. 1, 1968 (in press).
11) Takahashi, S., Sakuma, S., Kaneko, M. and Koga, S.: Angiography at fourfold magnification with special reference to the examination of tumours. *Acta radiol.* (*Diag.*), **4**, 206, 1966.
12) Takahashi, S., Sakuma, S. and Sugie, Y.: Vierfache direkte Vergrösserungsaufnamen der Lungen bei gesunden und bei frühen silikotischen Personen, *Fortschr. Röntgenstr.*, **92**, 294, 1960.
13) Takahashi, S., Watanabe, T. and Shiga, K.: Rotating anode tube with very small focal spot, *Nagoya J. med. Sci.* **20**, 231, 1958.
14) Takahashi, S. and Yoshida, M.: Roentgenography in high magnification. Reliability and limitation of enlargement, *Acta radiol.*, **48**, 280, 1957.
15) Takanashi, S. and Yoshida, M.: Radiographic effects influencing image formation in high magnification, *Nagoya J. med. Sci.*, **21**, 115, 1958.

16) Takaro, T.: Experimental renal glomeruligraphy, *Am. J. Roentgenol., Rad. Therapy and Nuclear Med.*, **101**, 681, 1967.

LEGENDS FOR ILLUSTRATIONS

FIG. 1. Renal arteriogram of living dog, one second after injection of contrast media (A). Photographically enlarged renal arteriogram to the same size of macroroentgenogram (B). Four times macroroentgenogram of the same kidney (C).

FIG. 2. Four times macroroentgenogram of the removed kidney, in which barium sulphate suspension was injected into the renal artery at (A). Microangiogram of the sliced specimen (B). Four times magnified microangiogram of the same slice (C).

FIG. 3. Equipment for macroroentgenography. X-ray tube is under the roentgenographic table. Film cassette changer is placed independently from the table.

FIG. 4. Conventional renal arteriogram, one second after contrast injection. Main renal, interlobar and arcuate arteries are seen (A). The late phase of the arteriogram, 7 seconds after contrast injection. Interlobar and arcuate arteries are seen in the background of nephrogram (B).

FIG. 5. Four times macroroentgenogram of the same patient, one second after contrast injection. Interlobular arteries and glomeruli were observed in a part (Arrow) as well as arcuate, interlobar and main renal arteries (A). The late arterial phase, 7 seconds after contrast injection. Numerous granular shadows of glomeruli are detected mainly in cortex, and in medulla as well (B).

A

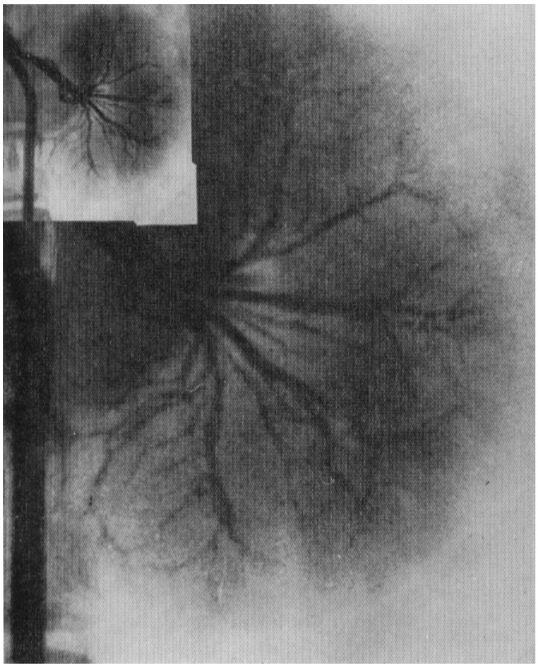

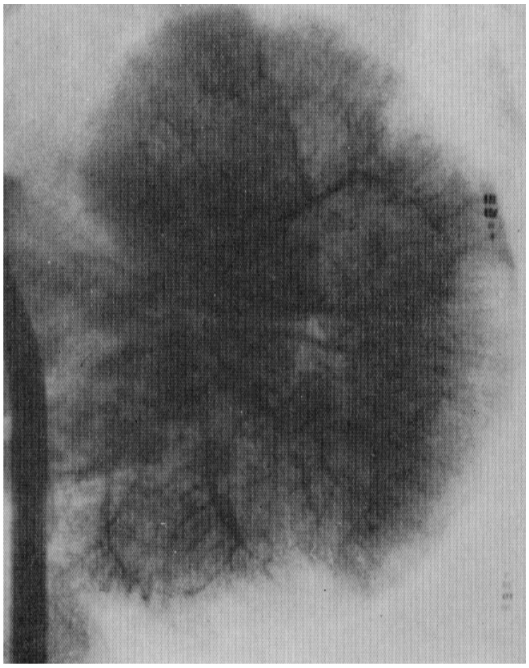

B C

FIG. 1

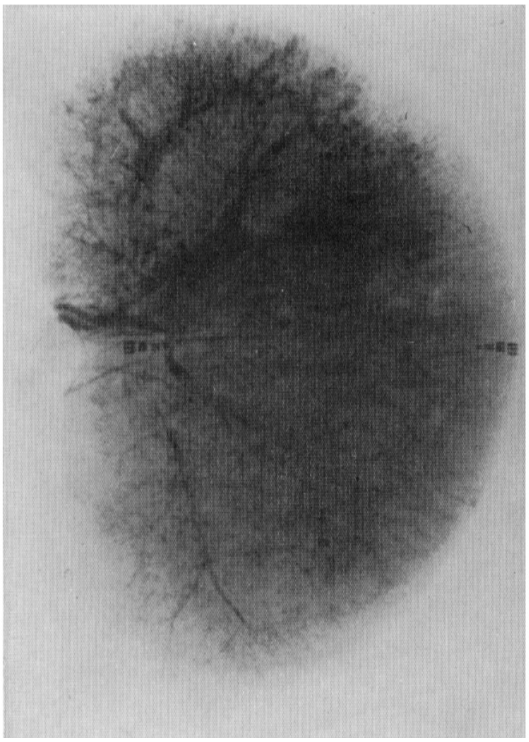

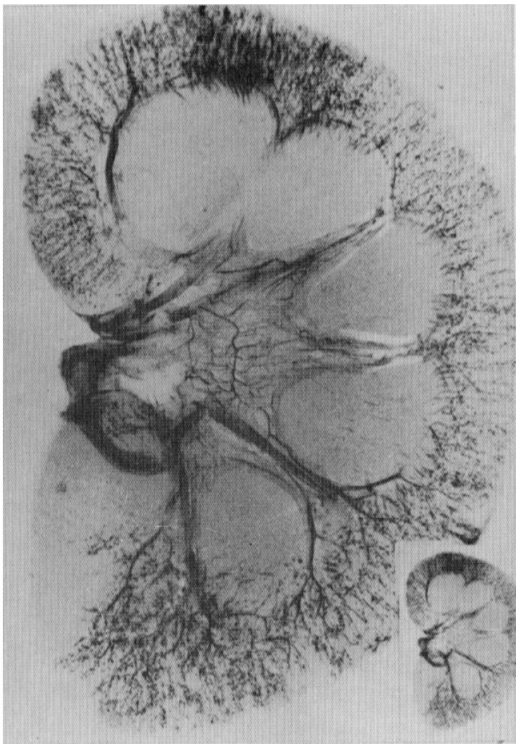

A C B

FIG. 2



FIG. 3

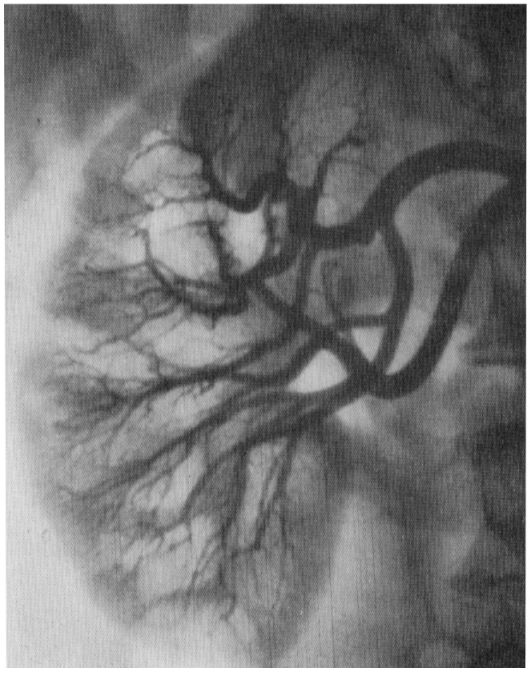

FIG. 4 (A)

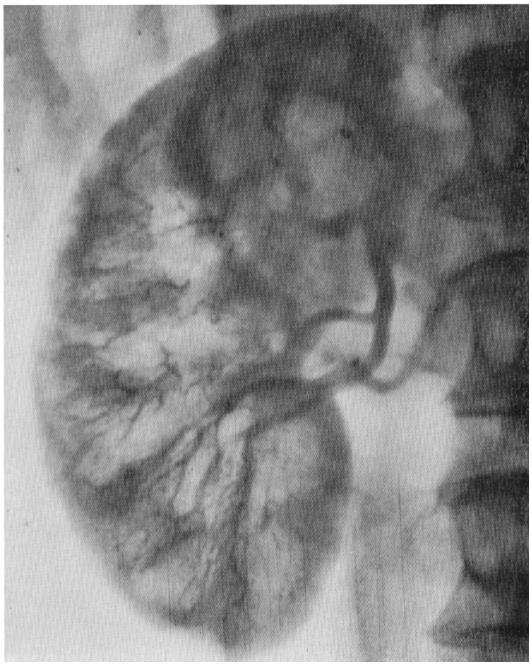

FIG. 4 (B)

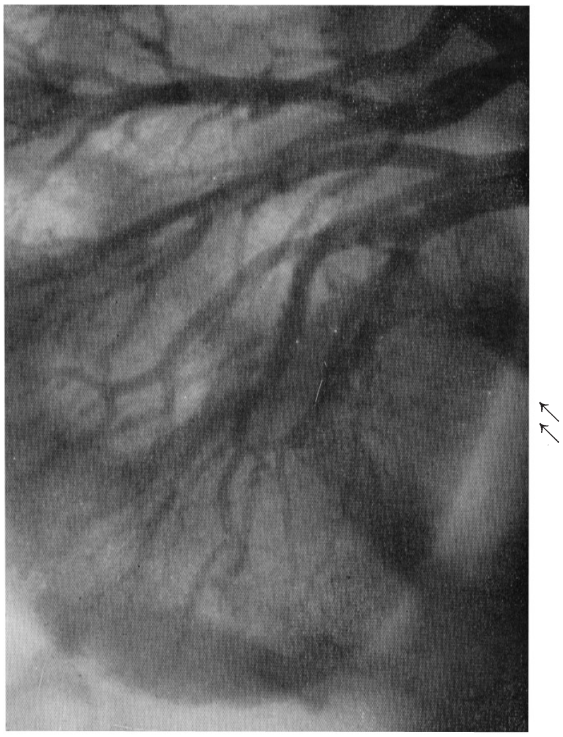

FIG. 5 (A)

FIG. 5 (B)