

**UNEXPECTED OVARIAN MALIGNANCY FOUND AFTER
LAPAROSCOPIC SURGERY IN PATIENTS
WITH ADNEXAL MASSES
–A SINGLE INSTITUTIONAL EXPERIENCE–**

SHIGEKO SAITO¹, MD; HIROAKI KAJIYAMA², MD, PhD; YOKO MIWA², MD;
MIKA MIZUNO², MD, PhD; FUMITAKA KIKKAWA², MD, PhD; SHIHO TANAKA¹, MD;
and TOMOMITSU OKAMOTO¹, MD, PhD

¹Department of Gynecology, Social Insurance Chukyo Hospital, Sanjo 1-1-10, Minami-ku, Nagoya, Japan
²Department of Obstetrics and Gynecology, Nagoya University Graduate School of Medicine, Nagoya, Japan

ABSTRACT

Laparoscopy has become the standard surgery for the treatment of benign ovarian tumors. The aim of this study was to evaluate the appropriateness of laparoscopy for ovarian tumors, including those with malignant potential. A total of 487 patients with adnexal masses underwent laparoscopic surgery in Social Insurance Chukyo Hospital from January 2000 to December 2012. We reviewed 471 cases that fulfilled the criteria set for this study, and examined 10 cases with unexpected ovarian malignancy to analyze their preoperative diagnosis, second surgery, postoperative chemotherapy, and prognosis. The ages of the 471 patients ranged from 13 to 50 years, with a median of 31. Nulliparous patients numbered 321 (68.1%). Of all, 436 patients mostly consisted of those with endometrioma, benign ovarian neoplasm or functional cyst. In all, we histologically identified 10 women with malignancy: 6 with borderline ovarian tumors (BOT), 2 with ovarian cancer, and 2 with histologically rare tumors (immature teratoma and granulosa cell tumor). All patients with BOT were diagnosed with a mucinous histology. Two patients underwent both second radical surgery (hysterectomy and contra- or bilateral salpingo-oophorectomy) and chemotherapies that consisted of CBDCA and PTX or DTX. Thus, 2 patients underwent staging procedures, but the remaining 8 cases did not. None of them had evidence of recurrences. With accurate staging and careful postoperative follow-up, laparoscopic surgery could be a feasible initial operation for patients with adnexal masses including early-stage ovarian malignancy.

Key Words: laparoscopy, ovarian malignant tumor, borderline malignancy, recurrence, clinical outcome

Abbreviations: LAA: laparoscope-assisted adnectomy, LAC: laparoscope-assisted cystectomy, BOT: borderline ovarian tumor

INTRODUCTION

Patients who undergo treatment for adnexal masses are seen at a relatively high incidence. Laparoscopy has become the standard surgery due to the treatment of benign adnexal masses for

Received: August 23, 2013; accepted: November 19, 2013

Corresponding author: Hiroaki Kajiyama, MD, PhD

Department of Obstetrics and Gynecology, Nagoya University Graduate School of Medicine,
65 Tsuruma-cho, Showa-ku, Nagoya 466-8550, Japan

TEL: +81-52-744-2262, FAX: +81-52-744-2268, E-mail: kajiyama@med.nagoya-u.ac.jp

its minimal invasiveness. Laparoscopic surgery is superior to laparotomy because of its various benefits, such as shorter hospitalization, less intraoperative complications, and quicker recovery⁹⁾. It is cosmetically preferable for younger patients because it requires only small incisions in the skin. It also causes less adhesion in the abdomen¹²⁾, which means that it is appropriate for patients who desire to have children. As the prevalence of adnexal masses with malignancy is relatively low, we seldom encounter malignant ovarian tumors in patients undergoing laparoscopy. However, when ovarian malignant tumors are treated by laparoscopy, there are concerns that spillage and misdiagnosis of the stage may lead to a poor prognosis. Despite the fact that preoperative assessments including transvaginal ultrasonography, MRI and serum tumor marker tests are performed routinely, it sometimes remains difficult to discriminate malignant from benign ovarian tumors.

In the present study, focusing on the oncologic outcome, we reviewed 471 patients who underwent laparoscopy in Social Insurance Chukyo Hospital to examine the characteristics, frequency, and the recurrence rate of patients with unexpected ovarian malignancy diagnosed after surgery.

METHODS

Patients

From January 2000 to December 2012, 487 patients with adnexal masses underwent laparoscopic surgery in Social Insurance Chukyo Hospital. All patients had been diagnosed with a benign adnexal tumor before the surgery by pelvic examination and transvaginal or transabdominal ultrasonography. Approximately 70% of the patients had received a preoperative MRI-based diagnosis.

Among them, we picked up 471 patients according to the following criteria:

- 1) Patients aged younger than 50 years
- 2) Patients who underwent either laparoscope-assisted cystectomy (LAC) or laparoscope-assisted adnectomy (LAA)
- 3) Patients who completed routine check-up after the surgery

Surgery

All patients underwent laparoscopic surgery, which consisted of laparoscope-assisted adnectomy (LAA) and laparoscope-assisted cystectomy (LAC) under general anesthesia. Each surgical procedure was selected at surgeon's discretion considering the size of the tumors, age of the patients, and the technical operative feasibility. In all cases, tumors were punctured during the operation for the purpose of reducing their sizes by aspirating intratumoral fluid.

Analysis of cases

We classified the 471 patients by the age, surgical procedures, pathological diagnosis of the tumors, and parity after treatment. We also examined 10 patients with subsequently proven borderline or a higher level of malignancy, regarding their preoperative diagnoses, procedure of second surgery, postoperative chemotherapies, and oncologic outcome.

RESULTS

Characteristics of patients

Patients' characteristics are shown in Table 1. The median age of all 471 patients was 31 years, ranging from 13 to 50, but nearly half of them were younger than 30 years. Nulliparous

OVARIAN MALIGNANT TUMOR FOUND AFTER LAPAROSCOPY

Table 1 Patients' characteristics

	N	%
<i>Age</i>		
Median (SD)	31 ± 7.0	
~30	234	49.7
31–40	172	36.5
41–45	46	9.8
46–50	19	4.0
<i>Parity before surgery</i>		
Average (SD)	0.57 ± 0.94	
0	321	68.2
1	59	12.5
2	69	14.6
3~	22	4.7
<i>Surgery</i>		
LAC (unilateral cystectomy)	340	72.2
LAC (bilateral cystectomy)	90	19.1
LAA	41	8.7
<i>Pathology</i>		
Endometrial cyst	182	38.6
Benign ovarian neoplasm	232	49.0
Functional cyst	14	3.0
Paraovarian cyst	14	3.0
Paratubal cyst	11	2.3
Others	10	2.3
Unknown	8	1.7

Benign ovarian neoplasm contains teratoma, serous cystadenoma, mucinous cystadenoma and struma

LAA : laparospe assisted adnectomy

LAC : laparospe assisted cystecomy

patients numbered 321(68.1%), and the average parity before surgery was 0.57 ± 0.94 . More than 90% (N =430) of the patients underwent LAC, of which 79.0% (N =340) was unilateral and 21% (N =41) was bilateral. The remaining women (N =41) received LAA. Ten patients were diagnosed with borderline or higher-level malignancy, 4 of whom underwent second surgery which included 1 laparoscopy and 3 laparotomies. They corresponded to 2.1% (10/471) of all patients. There was endometrioma in 182, benign ovarian neoplasm in 232, and functional cyst

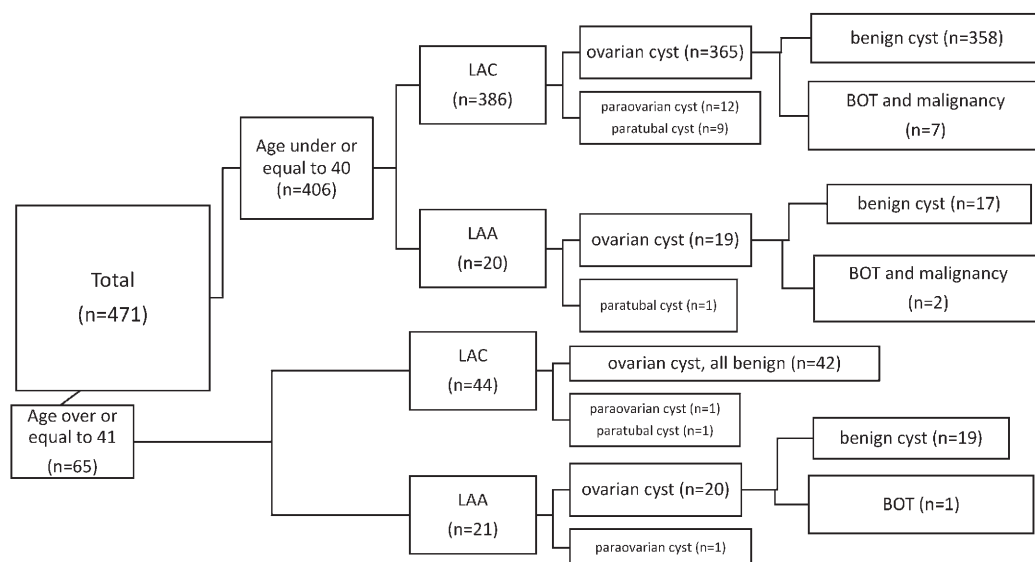


Fig. 1 The classification of all patients according to the age, surgical procedures, parts of the adnexa in which the tumors arose and whether or not the tumors are benign. BOT: borderline ovarian tumor, LAA: laparoscopy-assisted adnectomy, LAC: laparoscopy-assisted cystectomy

in 14 patients. Benign neoplasms included teratoma (N =185), serous cystadenoma (N =16), mucinous cystadenoma (N =29), and struma ovarii (N =2). Figure 1 is a flowchart showing patients' classification according to the age, surgical procedures, parts of the adnexa where the tumors arose and whether the tumors were benign or malignant.

Ten cases diagnosed with borderline or higher-level malignancy

Table 2 shows these 10 patients in terms of their preoperative examinations, surgical procedure, histological type, postoperative chemotherapy, and follow-up period. There were 6 patients with BOT, 2 with epithelial ovarian carcinoma, 1 with immature teratoma, and 1 with granulosa cell tumor. All patients with BOT were diagnosed with mucinous cystadenoma showing borderline malignancy. Preoperative MRI suggested malignancy (adenoma or carcinoma, mature or immature teratoma) only in 2 cases (case 1 and case 8). The remaining 8 cases showed no findings suspecting as malignancy. Figure 2 shows two typical images leading to diagnoses of mucinous cystadenoma and teratoma, respectively. Elevations of serum tumor markers were observed in cases 6 and 8. Cancer antigen 125 (CA125) and squamous cell carcinoma antigen (SCC) were elevated in cases 6 and 8, respectively. Two patients with BOT (case 6 and 7), one case with epithelial ovarian carcinoma (case 4), and the patient with immature teratoma (case 8) underwent a second surgery. Of them, 2 nulliparous patients who were younger than 30 years (cases 7 and 8) chose fertility-sparing surgery. The other 2 multiparous patients (cases 4 and 6) underwent non-conservative surgery (hysterectomy and contra- or bilateral salpingo-oophorectomy). Case 4 involved a carcinoma suspected to have arisen from a benign tumor that had been treated 6 years previously. She underwent hysterectomy, bilateral salpingo-oophorectomy, omentectomy, and pelvic lymphnodectomy. The other patients with BOT underwent hysterectomy and left salpingo-oophorectomy. Both received chemotherapies that consisted of carboplatin and taxane for 4 months. Although the period of postoperative follow-up varied from 12 to 120 months, none of them showed evidence of recurrence.

OVARIAN MALIGNANT TUMOR FOUND AFTER LAPAROSCOPY

Table 2 Cases of ovarian tumor with borderline malignancy or more

Case No.	Age	Parity	Preoperative MRI	Tumor marker (CA125 U/ml)	1st surgery	Histological type	2nd surgery	Chemotherapy	Follow-up (M)
1	19	0	BT or CA	N.A.	LAA	Mucinous BOT	None	None	24
2	26	2	BT	N.A.	LAA	Mucinous BOT	None	None	120
3	28	0	BT	N.A.	LAC	granulosa cell tumor	None	None	96
4	38	3	BT	19	LAC	Mucinous BT (1st surgery) Mucinous CA (2nd surgery)	ATH+BSO+ PLN+OM	Taxane + Platinum	72
5	23	0	BT	28	LAA	Mucinous BOT	None	None	60
6	45	2	BT	41.8	LAA	Mucinous BOT	ATH LSO	Taxane + Platinum	60
7	25	0	BT	N.A.	LAC	Mucinous BOT	LAA	None	48
8	17	0	BT or IM	31.2	LAC	imature teratoma	RSO PLN	None	36
9	29	0	BT	N.A.	LAC	Mucinous BOT	None	None	36
10	33	0	BT	12.8	LAC	Mucinous CA	None	None	12

BT: benign tumor, CA: carcinoma, N.A.: not available, LAA: laparoscope assisted adnectomy, LAC: laparoscope assisted cystectomy, BOT: borderline ovarian tumor, ATH: abdominal total histerectomy, BSO: bilateral sappingo-oophorectomy, RSO:right sappingo-oophorectomy, LSO:left sappingo-oophorectomy, PLN: retroperitoneal lymphadenectomy, OM: omentectomy

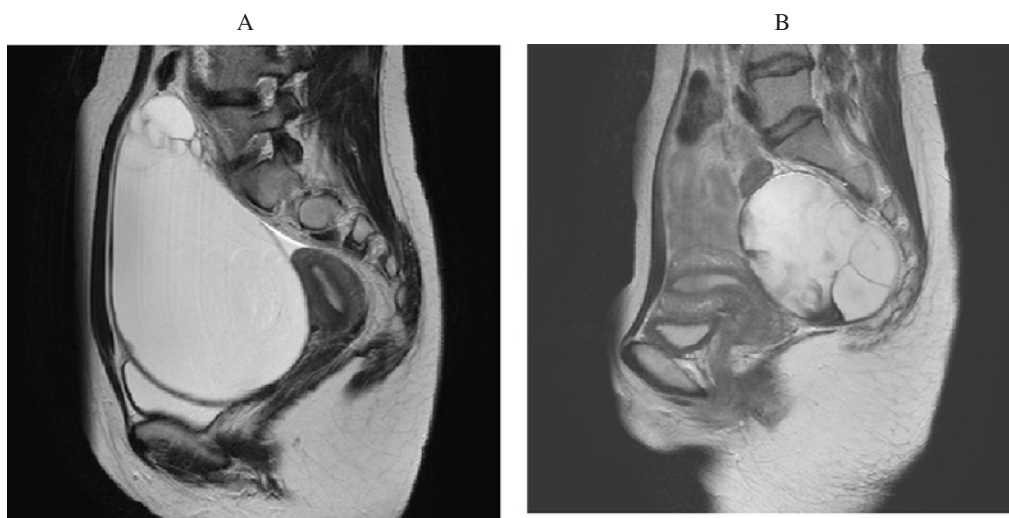


Fig. 2 Preoperative MRI involving cases 7 and 9 in Table 2. Image A: case 7, diagnosed with mucinous adenoma. Image B: case 9, diagnosed with teratoma

Reproductive outcome

Parity after surgery was observed in 49 patients, all of whom were younger than 40 years (Table 3). Eight of 10 women were given treatments preserving their fertility, which meant conservative surgery and avoiding chemotherapies. However, none of them became pregnant after the treatment.

Table 3 Number of the patients with parity after surgery

Age	LAC	LAA	Total
~30	32 (13.6%)	0	234
31~40	15 (8.7%)	2 (1.1%)	172
41~45	0	0	46
46~50	0	0	19
Total	47 (9.9%)	2 (0.4%)	471

LAC: laparoscope assisted cystectomy, LAA: laparoscope assisted adnectomy

DISCUSSION

We analyzed 471 patients who underwent laparoscopic surgery for adnexal masses in a single institution, and picked up 10 patients with malignancy to assess the appropriateness of the treatments that they received. All 10 subjects with malignant tumors have shown no evidence of recurrence to date. However, we became aware of several issues to consider regarding surgical methods on reviewing the previous literature.

In the present study, the rate of patients with unsuspected ovarian cancers was 0.4% (2 patients), which was similar to the report by Leng *et al.*⁸⁾. Of these, one patient was multiparous, who accepted radical treatment including chemotherapy. She had been treated for a mucinous cystadenoma 6 years before the mucinous cystadenocarcinoma had arisen. According to the classification of BOT⁷⁾, the first tumor (mucinous cystadenoma) is considered to be a precursor of the second tumor (mucinous cystadenocarcinoma). The other was a nulliparous 33-year-old woman who strongly desired only conservative treatment despite our recommendation of second surgery with full comprehensive staging. Consequently, she finished the treatment with LAC alone. The pathological diagnosis was a well-differentiated mucinous adenocarcinoma. Morice *et al.* reported that conservative surgery in patients with ovarian cancer could only be considered when tumors are serous, mucinous, or endometrioid with grade 1 or 2, and stage IA to IC, and when close follow-up is possible¹⁰⁾. However, Fruscio *et al.* reported that the recurrence rate of early-stage ovarian cancer with or without a second surgery reached 11%⁴⁾. At present, we think that laparoscopic surgery alone as a fertility-sparing treatment should not be recommended and it is better to perform second staging surgery. Owing to the lack of adequate staging, the patient requires very close follow-up, although 12 months have passed so far without any signs of recurrence.

We identified six patients (1.2%) with BOT, which was three times as many as in the report by Leng *et al.* (0.3%)⁸⁾, but far fewer than reported by Demir *et al.* (5.0%)³⁾. There were 2 patients with histologically rare tumors. The patient with an immature teratoma underwent ipsilateral adnectomy and pelvic lymphadenectomy as second surgery and completed the treatment without adjuvant chemotherapy. Malignant ovarian germ cell tumor patients have been reported to show an excellent prognosis, mainly because of the tumor's marked sensitivity to chemotherapy¹⁾. Although the risk of upstaging only involved the intraoperative puncture of the tumor in this case, she should be followed carefully, considering the absence of chemotherapy. The patient with a granulosa cell tumor received neither second surgery nor chemotherapy. The pathological diagnosis did not revealed a high mitotic rate of the tumor, which is a risk factor of recurrence¹³⁾, but the procedure (LAC) was insufficient to avoid recurrence because the chemotherapy is not effective and complete resection of the tumor is essential. As relapses more than five years after surgery are characteristic of granulosa cell tumors, she needs to undergo long-term follow-up.

OVARIAN MALIGNANT TUMOR FOUND AFTER LAPAROSCOPY

As laparoscopic procedures always involve the intra-abdominal puncture of a tumor, which worsens the disease stage, our 10 patients would be staged as intraoperative-rupture-IC. However, none of the 4 patients who underwent second surgery were upstaged based on pathological findings. A number of researchers have discussed the issue of whether the intraoperative rupture of tumors negatively affects the oncologic outcome. While Bakkum-Gamez JN *et al.* reported the increased risk of recurrence due to intraoperative rupture of a tumor²⁾, several recent studies have reported that cyst puncture may not affect the prognosis^{5,6,8)}. Needless to say, our cases should receive careful follow-up even though they have not exhibited any signs of recurrence to date. However, these results from previous studies at least support laparoscopic surgery as a feasible treatment for BOT.

Most of the patients with malignancy in our study were young and preferred to avoid multiple surgeries, which resulted in the lack of accurate staging. The study by Muzii *et al.* described laparoscopic fertility-sparing staging in early-stage ovarian malignancies as a feasible and safe procedure¹¹⁾. The staging consisted of peritoneal washing for cytology, multiple peritoneal biopsies, infracolic omentectomy, biopsy of the contralateral ovary, etc. As they did not impair the fertility of patients, they would be acceptable for patients undergoing laparoscopic surgery for adnexal masses.

In conclusion, laparoscopic surgery for at least early-stage BOT or higher-level malignancy may be feasible when accurate staging is carried out. Intraoperative pathological evaluation is necessary to consider whether procedures for accurate staging, such as peritoneal washing cytology and biopsies of the peritoneum or contralateral ovary, should be performed. We need to accumulate a larger number of cases. The possibility of laparoscopic surgery for ovarian neoplasm may be expanded by the continuous and careful inspection of outcomes in the future.

CONFLICT OF INTEREST STATEMENT

All authors declare that there are no financial disclosures or conflicts of interest.

REFERENCES

- 1) Anita AN, Rushdan MN (2012) Reproductive function after treatment of ovarian germ cell malignancy. *The Medical journal of Malaysia* 67: 71–76
- 2) Bakkum-Gamez JN, Richardson DL, Seamon LG, Aletti GD, Powless CA, Keeney GL, O'Malley DM, Cliby WA (2009) Influence of intraoperative capsule rupture on outcomes in stage I epithelial ovarian cancer. *Obstetrics and gynecology* 113: 11–17
- 3) Demir RH, Marchand GJ (2012) Adnexal masses suspected to be benign treated with laparoscopy. *JLS : Journal of the Society of Laparoendoscopic Surgeons / Society of Laparoendoscopic Surgeons* 16: 71–84
- 4) Fruscio R, Corso S, Ceppi L, Garavaglia D, Garbi A, Floriani I, Franchi D, Cantu MG, Bonazzi CM, Milani R, Mangioni C, Colombo N (2013) Conservative management of early-stage epithelial ovarian cancer: results of a large retrospective series. *Annals of oncology : official journal of the European Society for Medical Oncology / ESMO* 24: 138–144
- 5) Higashi M, Kajiyama H, Shibata K, Mizuno M, Mizuno K, Hosono S, Kawai M, Nakanishi T, Nagasaka T, Kikkawa F (2011) Survival impact of capsule rupture in stage I clear cell carcinoma of the ovary in comparison with other histological types. *Gynecologic oncology* 123: 474–478
- 6) Kajiyama H, Shibata K, Suzuki S, Ino K, Nawa A, Kawai M, Nagasaka T, Kikkawa F (2010) Fertility-sparing surgery in young women with invasive epithelial ovarian cancer. *European journal of surgical oncology : the journal of the European Society of Surgical Oncology and the British Association of Surgical Oncology* 36: 404–408
- 7) Lalwani N, Shanbhogue AK, Vikram R, Nagar A, Jagirdar J, Prasad SR (2010) Current update on borderline ovarian neoplasms. *AJR American journal of roentgenology* 194: 330–336

- 8) Leng JH, Lang JH, Zhang JJ, Feng FZ, Liu ZF, Sun DW, Zhu L, Zhao XY (2006) Role of laparoscopy in the diagnosis and treatment of adnexal masses. *Chinese medical journal* 119: 202–206
- 9) Medeiros LR, Rosa DD, Bozzetti MC, Fachel JM, Furness S, Garry R, Rosa MI, Stein AT (2009) Laparoscopy versus laparotomy for benign ovarian tumour. *Cochrane database of systematic reviews*: CD004751
- 10) Morice P, Dubernard G, Rey A, Atallah D, Pautier P, Pomel C, Lhomme C, Duvillard P, Castaigne D (2003) Results of interval debulking surgery compared with primary debulking surgery in advanced stage ovarian cancer. *Journal of the American College of Surgeons* 197: 955–963
- 11) Muzii L, Palaia I, Sansone M, Calcagno M, Plotti F, Angioli R, Panici PB (2009) Laparoscopic fertility-sparing staging in unexpected early stage ovarian malignancies. *Fertility and sterility* 91: 2632–2637
- 12) Pismensky SV, Kalzhanov ZR, Eliseeva MY, Kosmas IP, Mynbaev OA (2011) Severe inflammatory reaction induced by peritoneal trauma is the key driving mechanism of postoperative adhesion formation. *BMC surgery* 11: 30
- 13) Sehouli J, Drescher FS, Mustea A, Elling D, Friedmann W, Kuhn W, Nehmzow M, Opri F, Klare P, Dietel M, Lichtenegger W (2004) Granulosa cell tumor of the ovary: 10 years follow-up data of 65 patients. *Anticancer research* 24: 1223–1229