

## **FULL-THICKNESS SMALL INTESTINE NECROSIS WITH MIDGUT VOLVULUS, DISTRIBUTED IN A PATCHY FASHION, IS REVERSIBLE WITH MODERATE BLOOD FLOW: RESUMPTION OF NORMAL FUNCTION TO NON-VIABLE INTESTINE**

HIZURU AMANO<sup>1</sup>, HIROO UCHIDA<sup>3</sup>, HIROSHI KAWASHIMA<sup>1</sup>,  
YUJIRO TANAKA<sup>1</sup> and HIROSHI KISHIMOTO<sup>2</sup>

*<sup>1</sup>Department of Pediatric Surgery, and*

*<sup>2</sup>Department of Pathology, Saitama Children's Medical Center, Saitama, Japan*

*<sup>3</sup>Department of Pediatric Surgery, Nagoya University Graduate School of Medicine, Nagoya, Japan*

### ABSTRACT

Midgut volvulus is a highly life-threatening condition that carries a high risk of short gut syndrome. We report a case of catastrophic neonatal midgut volvulus in which second-look laparotomy revealed apparently non-viable remnant small intestine but with a moderate blood supply. Full-thickness small intestine necrosis was distributed in a patchy fashion, with non-viable and necrotic areas distributed so widely that no portion of the intestine could be resected. A section of full-thickness necrotic intestine preserved at surgery was able to regenerate, and normal function was restored over a period of 1 month. This case indicated that intestinal resumption may be dependent on blood flow. Even when intestinal viability is questionable, preservation enables the chance of regeneration if moderate blood flow is present.

Key Words: neonate, midgut volvulus, necrosis, viability, second look operation

### INTRODUCTION

Intestinal malrotation is a congenital abnormal position of the bowel within the peritoneal cavity. In cases of midgut volvulus, it is critical to make a diagnosis and to intervene immediately to avoid the potentially life-threatening consequence of intestinal necrosis, which in severe cases may lead to short bowel syndrome. There is currently no gold standard for treatment of massive intestinal necrosis detected at laparotomy. In cases of midgut volvulus with extensive areas of bowel ischemia that did not recover after derotation, a second-look operation can be attempted to identify viable intestine;<sup>1,2)</sup> however, the basis for predicting intestinal viability has yet to be described, and viability is difficult to define.<sup>3)</sup>

---

Received: July 7, 2014; accepted: July 31, 2014

Corresponding author: Hiroo Uchida, M.D.

Department of Pediatric Surgery, Nagoya University Graduate School of Medicine,  
65 Tsurumai, Showa, Nagoya 466-8550, Japan

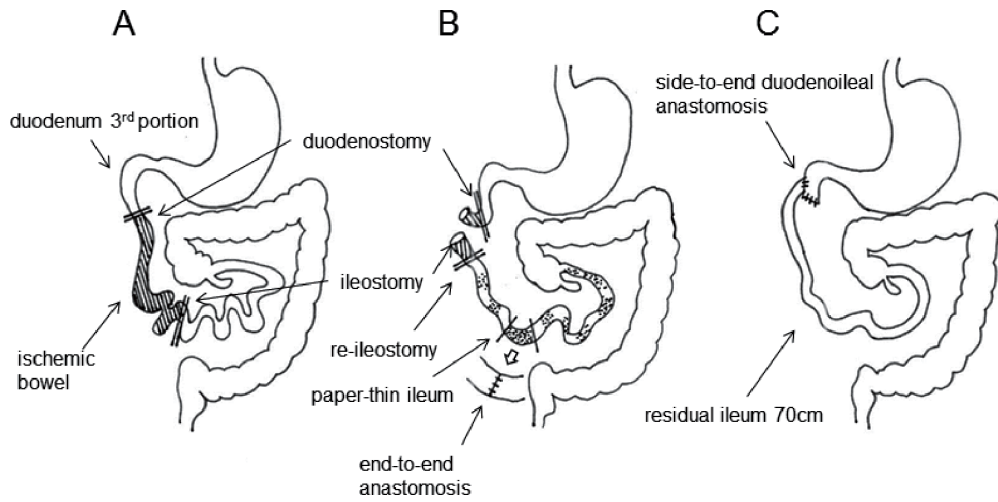
Tel: +81-52-744-2959, E-mail: hiro2013@med.nagoya-u.ac.jp

We report a case of neonatal malrotation with midgut volvulus in which necrotic, not ischemic, bowel was preserved in second-look laparotomy. The preserved intestine, which appeared to be non-viable but had a moderate blood supply, was pathologically shown as full-thickness small bowel necrosis, distributed in a patchy fashion. Fortunately, the preserved necrotic intestine was able to regenerate; the patient survived and performs normal daily activities. We discuss issues regarding the management of non-viable small bowel with midgut volvulus.

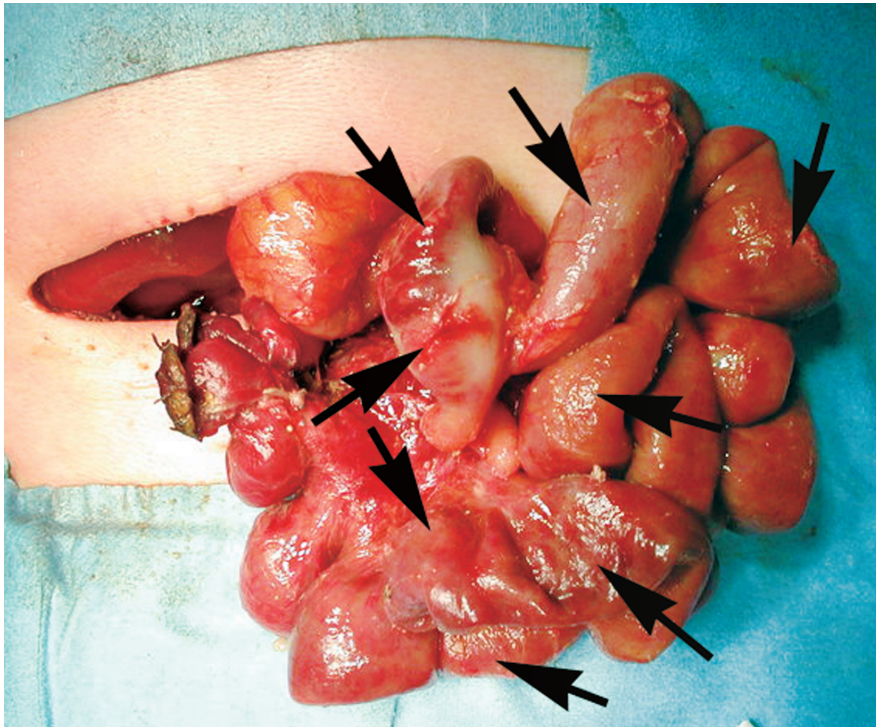
## CASE REPORT

A baby boy was born at term, weighing 3136 g. He did well for the first ten days of life; feeding was begun at 8 hours of age, and was well tolerated. He vomited several times on the tenth day, presenting the next day with persistent bilious vomiting at the emergency room of the municipal hospital. He was immediately intubated and resuscitated for pre-shock status, with initial laboratory findings of profound dehydration and marked metabolic acidosis (pH 6.879, BE -25.8). He was transferred to the neonatal surgical unit. His abdomen was markedly distended, but no peritoneal signs were exhibited. Abdominal ultrasonography and computed tomography suggested midgut volvulus with ischemic bowel. At emergent laparotomy (Fig. 1A), a 630° clockwise volvulus of the midgut was found with an extensive area of ischemic and dusky-black bowel from the duodenum to the transverse colon. After derotation and Ladd procedure, ischemic bowel between the distal part of the duodenum and the jejunum showed no improvement and was resected. The distal 75 cm of the terminal ileum, which was considered to have questionable recovery of blood flow, was preserved in the hope of regenerating viable intestine. Duodenostomy and ileostomy were performed. On post-operative day (POD) 2, a second-look operation (Fig. 1B) was performed. The duodenostomy was completely necrotized but the proximal portion had maintained blood flow, and was divided, lying as a blind end in the sub-hepatic position. Blood flow in the bowel between the ileum and transverse colon was markedly improved; however, the ileum had many necrotic areas, identifiable as paper-thin intestine, distributed in a patchy and circumferential manner (Fig. 2), and appearing to be necrotic and non-viable. A portion of paper-thin ileum was resected circumferentially by approximately 3 cm in width as specimen or intraoperative rapid histological diagnosis in order to determine the appropriate surgical plan. The intestine had the appearance of partial full-thickness necrosis (Fig. 3). The distribution of these apparently non-viable and necrotic areas with a moderate blood supply was so widespread that we could not resect any other part of the intestine, and made the decision to wait and see. The resected ileum was anastomosed in an end-to-end manner and ileostomy was performed. The total length of residual ileum measured 70 cm, including the ileocecal valve. After the second operation, ileostomy appeared viable and the patient's general condition had improved. He was extubated at POD 4. Meticulous nasogastric drainage was performed over the next few weeks. On POD 14, aspirated gastric and bile juice to which was added a large amount of L-glutamine was administered through the ileostomy to the residual ileum and colon to confer mucosal immunity and reformation. Contrast study of the gastrointestinal tract through the ileostomy on POD 25 showed poor peristalsis and varying ileal caliber. A small quantity of milk was then introduced through the ileostomy in addition to transparenteral nutrition (TPN); however, his body weight did not increase successfully. On POD 43, closure of the ileostomy was performed by side-to-end duodenoileal anastomosis (Fig. 1C). Pathological study showed that the appearance of the ileal mucosa had returned to normal, although the muscle layers were damaged locally. On the fourth day after closure, oral intake and probiotics were started in addition to TPN; there were no problems with the nutrient intake and the patient's body weight increased. He was discharged

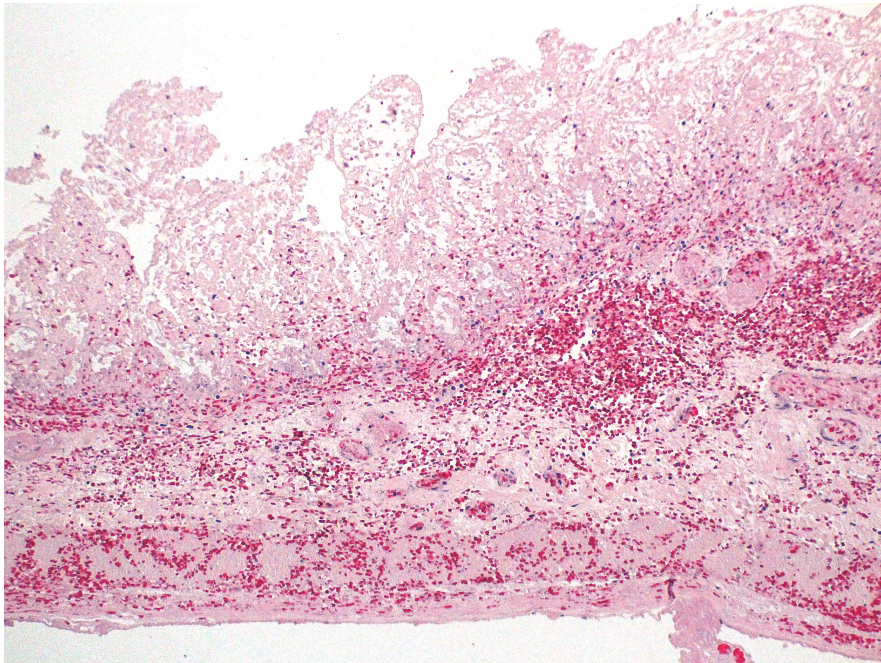
## REGENERATION OF NON-VIABLE INTESTINE



**Fig. 1** Schematic images for the operative procedures.  
 A The first operative procedure.  
 B The second-look operative procedure.  
 C The third operative procedure.



**Fig. 2** Appearance of remaining bowel as seen at second laparotomy. The appearance of the bowel is markedly improved compared with that after the first operation, suggesting a sufficient blood supply. The intestine is paper-thin and distributed in a patchy and circumferential manner (arrows), appearing necrotic and non-viable.



**Fig. 3** Pathological findings of the paper-thin intestine (H/E stain) at second laparotomy showing full-thickness necrosis with hemorrhage.

from the hospital at 3 months of age, weighing 4626 g and tolerating oral feeding. The patient is now 4.5 years old and has normal psychomotor development. He has shown marked physical growth in the last two years.

## DISCUSSION

The survival rate of children with malrotation due to midgut volvulus is greater than 80%; however, high mortality is still observed in patients with extensive necrotic bowel due to malrotation.<sup>4)</sup> The high mortality is due to the conventional management of patients with significant non-viable bowel by extensive resection, which may lead to life-threatening short bowel syndrome. Extensive resection of the bowel remains a highly morbid condition, and has poor short- and long-term survival. Our operational goal is to derotate the midgut, perform revascularization, assess bowel viability, and resect necrotic bowel. Detecting bowel viability is crucial for this operation. A second-look operation has been suggested to define areas of nonviable intestine and to improve decision-making. Second-look laparotomy may be justifiable on initial surgery findings that include extensive areas of ischemic bowel, ambiguous margins of demarcation between well-vascularized and necrotic bowel, questionable viability of the bowel, and poor blood supply to the remaining bowel.<sup>5,6)</sup>

We experienced a case of catastrophic neonatal midgut volvulus that underwent a second-look laparotomy. The first assessment showed extensive ischemic bowel, with no further improvement after derotation and division of Ladd's band. At second-look laparotomy, the remaining small bowel appeared to be non-viable but had a moderate blood supply, and was pathologically shown

to exhibit full-thickness small bowel necrosis with patchy distribution. Resection of all of the necrotic intestine would have left very little remaining small bowel. The decision was made not to resect any intestine in the hope that the tissue would regenerate.

On inspection, it was difficult to identify viable bowel. We concluded that the bowel was non-viable and necrotic based on its paper-thin appearance. This diagnosis was confirmed by pathological examination; however, the preserved intestine was able to regenerate, and normal function was restored over a period of 1 month. The necrotic bowel had resumed function because it had received an adequate blood supply. Necrotic bowel with a patchy distribution may offer an ideal scaffold for intestinal regeneration if there is a sufficient blood supply.<sup>7,8)</sup> From this viewpoint, intestinal resumption is dependent mainly on blood flow. Even when intestinal viability is questionable, preservation is worthwhile in the hope of regeneration, if there is sufficient blood flow.

A previous report showed that extensive non-viable bowel recovered to some extent after withholding resection and waiting for normal function to return.<sup>9)</sup> Non-viable intestine may recover with adequate blood flow and may change a fibrous band without lumen with the absence of blood flow. The preservation of seemingly non-viable intestine, however, represents a great challenge. Ischemic reperfusion injury and necrotic change can induce severe systemic damage that cannot always be regulated by intensive care and may even be fatal.<sup>10)</sup> The clinical course could possibly be dependent on the degree of involvement. There may be no gold standard for treating extensive necrotic bowel with midgut volvulus. Preservation of involved bowel may offer a possible treatment method for catastrophic midgut volvulus in the case that the extensive areas of apparently non-viable intestine have moderate blood supply. Now, we have no objective scientific criteria for judgment with regard to sufficient blood flow to recover from the necrotic bowel.<sup>11)</sup> We mainly decide whether the necrotic bowel is resected or not, dependent on the macroscopic or pathological appearance of it. Many scientific data on the sufficient blood flow for regeneration of non-viable intestine need be accumulated.

## CONCLUSION

Intestinal resumption may be dependent on blood flow. Even when intestinal viability is questionable, preservation enables the chance of regeneration if there is macroscopic sufficient blood flow.

Conflict of interest: The authors have declared no conflicts of interest.

## REFERENCES

- 1) Hoffman MA, Johnson CL, Moore T, Pearl RH. Management of catastrophic neonatal midgut volvulus with a silo and second-look laparotomy. *J Pediatr Surg*, 1992; 27: 1336–1339.
- 2) McCullagh M, Garvie DC, Dykes EH. A new method of intestinal salvage for severe small bowel ischemia. *J Pediatr Surg*, 1994; 29: 1231–1233.
- 3) Erikoglu M, Kaynak A, Beyatli EA, Toy H. Intraoperative determination of intestinal viability: a comparison with transserosal pulse oximetry and histopathological examination. *J Surg Re*. 2005; 128: 66–69.
- 4) Strouse PJ. Disorders of intestinal rotation and fixation (“malrotation”). *Pediatr Radio*, 2004; 34: 837–851.
- 5) Yanar H, Taviloglu K, Ertekin C, Ozcinar B, Yanar F, Guloglu R, Kurtoglu M. Planned second-look laparoscopy in the management of acute mesenteric ischemia. *World J Gastroenterol*, 2007; 13: 3350–3353.
- 6) Meng X, Liu L, Jiang H. Indications and procedures for second-look surgery in acute mesenteric ischemia. *Surg Today*, 2010; 40: 700–705.

- 7) Udassin R, Vromen A, Haskel Y. The time sequence of injury and recovery following transient reversible intestinal ischemia. *J Surg Res*, 1994; 56: 221–225.
- 8) Zmora O, Khaikin M, Rosin D, Shabtai M, Bar-Zakai B, Ayalon A. Late regeneration of infarcted small bowel mucosa: a case report. *J Parenter Enteral Nutr*, 2005; 29: 131–133.
- 9) Houben CH, Mitton S, Capps S. Malrotation volvulus in a neonate: a novel surgical approach. *Pediatr Surg Int*, 2006; 22: 393–394.
- 10) Kaminsky O, Yampolski I, Aranovich D, Gnessin E, Greif F. Does a second-look operation improve survival in patients with peritonitis due to acute mesenteric ischemia? A five-year retrospective experience. *World J Sur*, 2005; 29: 645–648.
- 11) Horgan PG, Gorey TF. Operative assessment of intestinal viability. *Surg Clin North Am*, 1992; 72: 143–155.