

Imaging of endolymphatic hydrops on a vertigo attack of Meniere's disease

Takafumi Nakada^{1,2}, Masaaki Teranishi³, Saiko Sugiura², Yasue Uchida^{2,4},
Shinji Naganawa⁵ and Michihiko Sone³

¹Department of Otorhinolaryngology, Nishichita General Hospital, Tokai, Japan

²Department of Otorhinolaryngology, National Center for Geriatrics and Gerontology, Obu, Japan

³Department of Otorhinolaryngology, Nagoya University, Nagoya, Japan

⁴Department of Otorhinolaryngology, Aichi Medical University, Nagakute, Japan

⁵Department of Radiology, Nagoya University, Nagoya, Japan

ABSTRACT

Meniere's disease (MD) characteristically presents with endolymphatic hydrops (EH), which can be visualized with gadolinium-enhanced inner ear magnetic resonance imaging (MRI). Inner ear membrane rupture has been suspected to cause MD attacks, but this remains controversial. We report a case of MD coincidentally evaluated the EH using 3-Tesla MRI during a vertigo attack. A 78-year-old man with bilateral definite MD visited the hospital outpatient department due to a vertigo attack. To evaluate of endolymphatic hydrops on the attack, inner ear MRI was obtained 4 hours after intravenous injection of gadolinium agent. Vestibular EH in each ear occupied almost all vestibular endolymphatic space in contact with the oval window and herniated into the horizontal semi-circular canal. The endolymphatic space was enlarged, without collapse or mixture of contrast agent. No difference was found between ears. EH on a vertigo attack was associated with significant swelling, without obvious evidence of membranous ruptures on magnetic resonance images.

Keywords: endolymphatic hydrops, magnetic resonance imaging, Meniere's disease, vertigo

Abbreviations:

EH: endolymphatic hydrops

MD: Meniere's disease

MRI: magnetic resonance imaging

This is an Open Access article distributed under the Creative Commons Attribution-NonCommercial-NoDerivatives 4.0 International License. To view the details of this license, please visit (<http://creativecommons.org/licenses/by-nc-nd/4.0/>).

INTRODUCTION

Meniere's disease (MD) is characterized by symptoms of episodic vertigo, fluctuating hearing loss, tinnitus, and aural fullness. Endolymphatic hydrops (EH) is a characteristic sign of MD. Magnetic resonance imaging (MRI) now allows visualization of EH.¹ Membranous rupture and potassium intoxication theory were proposed to cause the attacks, but these hypotheses remain

Received: July 6, 2020; accepted: July 29, 2020

Corresponding author: Takafumi Nakada, MD, PhD

Department of Otorhinolaryngology, Nishichita General Hospital, 3-1-1 Nakanoike, Tokai 477-8522 Japan

Phone: +81-562-33-5500, Fax: +81-562-33-5900, E-mail: tnakada@med.nagoya-u.ac.jp

controversial. According to this theory, Reisner's membrane or the membranous labyrinth collapses, hence the inflow of high-potassium endolymph into the perilymph, resulting in MD attacks.²⁻⁴ Histological findings have shown distinct ruptured membranes of MD patients in post-mortem studies of the temporal bone and inner ear, with a rupture incidence rate of 38%.⁵ An enlarged vestibular EH can herniate into the horizontal semi-circular canal in patients with MD, which has been demonstrated by both histological and imaging studies.^{6,7} Imaging studies have never described the evidence of membranous rupture in the inner ear of MD patients, although MRI is being widely used to investigate MD.

Detection of EH conditions while on vertigo attacks of MD could provide insights on the mechanism of the attacks. In our experience of MRI evaluation of more than 1,600 subjects, several patients have undergone MRI scanning a few days after their MD attacks; the images did not show membranous ruptures. However, none of these patients underwent MRI during the MD attack. This case report demonstrated MR images of EH obtained on a vertigo attack in an MD patient.

CASE REPORT

A 78-year-old man first experienced an episode of rotatory vertigo which started 20 years earlier. His symptoms subsequently spontaneously recurred a few times per year. Acute sensorineural hearing loss occurred in the left ear when the patient was 63 years old, and in the right ear 2 years after. This gradually progressed, resulting in a recent average threshold of 50.0 dB in the right and 55.0 dB in the left ear. The patient was then diagnosed with bilateral definite Meniere's disease.⁸

On the day of the patient's schedule to undergo MRI evaluation of EH, he visited the hospital outpatient department before noon due to a vertigo attack that had developed a few hours prior. The patient had spontaneous nystagmus toward the right side, but did not exhibit acute hearing loss, or increased tinnitus or aural fullness. A standard dose of gadodiamide hydrate was injected intravenously at noon, and a 3-T MRI scan was performed while on the attack.^{9,10} Saccular function was evaluated using cervical vestibular evoked myogenic potentials (cVEMP) on the day of the attack; this was repeated 50 days later. Pure tone audiometry was also performed.

MRI

MR images are shown in Fig. 1. A radiologist who did not know the clinical symptoms classified the degree of EH in the vestibule and cochlea into three grades: none, mild, and significant.¹¹ Significant EH was observed bilaterally in the vestibule and cochlea. Vestibular EH of both ears occupied almost all vestibular endolymphatic space in contact with the oval window and herniated into the horizontal semi-circular canal. The endolymphatic space was enlarged, without collapse or mixture of contrast agent. There is also no difference found between ears.

cVEMP and pure tone audiometry

The cVEMP examinations were performed on the day of attack then 50 days later (Fig. 2). The amplitude of the left ear was smaller than that of the right ear on the day of the attack with the asymmetry ratio of 47.2%, whereas, 50 days later, the asymmetry ratio became 1.5%. (The asymmetry ratio was obtained by the following formula: $\frac{\text{left amplitude} - \text{right amplitude}}{(\text{left amplitude} + \text{right amplitude})} \times 100$.)

The average hearing levels at three frequencies (500 Hz, 1 kHz, 2 kHz) was 50.0 dB on the left side and 55.0 dB on the right side, which were not markedly different from those performed 1 year before the attack (Fig. 3).

Imaging of hydrops on a Meniere's attack

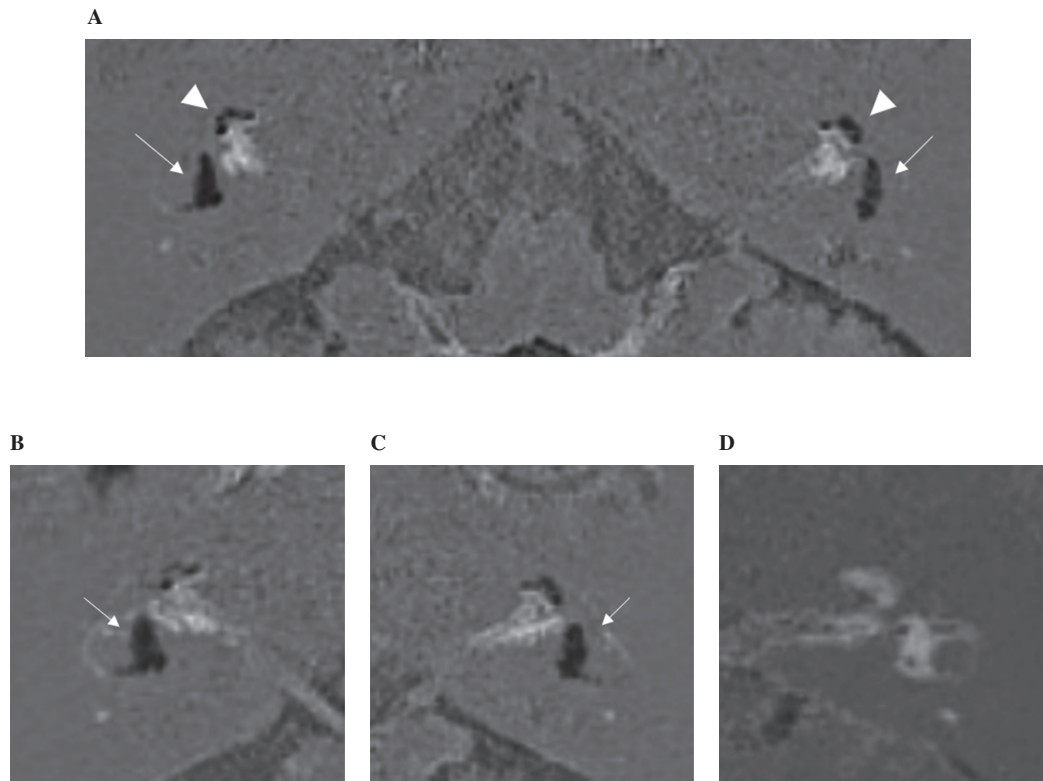


Fig. 1 Magnetic resonance images of endolymphatic hydrops (black areas) in the patient

Fig. 1A: Bilateral significant endolymphatic hydrops is shown in the cochlea (arrowheads) and the vestibule (arrows).

Fig. 1B: Vestibular endolymphatic hydrops in the right ear (contralateral side) were enlarged significantly and herniated into the horizontal semi-circular canal.

Fig. 1C: In the left ear (ipsilateral side), vestibular endolymphatic hydrops was similar on the right side. No suspicious features indicating clear membranous ruptures were found in the images taken on the vertigo attack.

Fig. 1D: Normal endolymphatic space in both the cochlea and the vestibule (left ear), shown for reference.

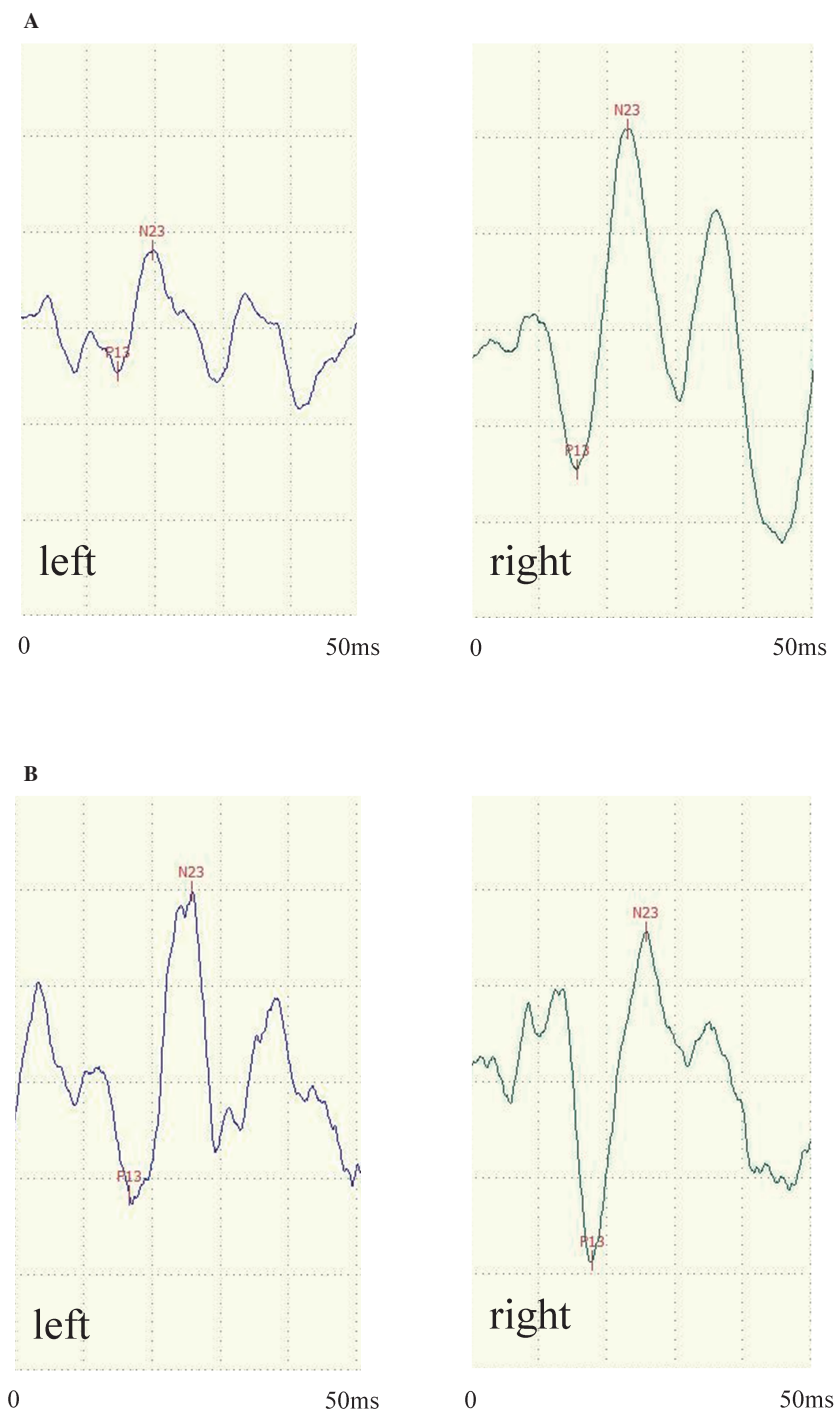


Fig. 2 The results of cervical vestibular myogenic potentials

Fig. 2A: The amplitude of the left ear was smaller than that for the right ear on the day of the vertigo attack. The asymmetry ratio was calculated to be 47.2%.

Fig. 2B: After 50 days, the asymmetry ratio was calculated to be 1.5%.

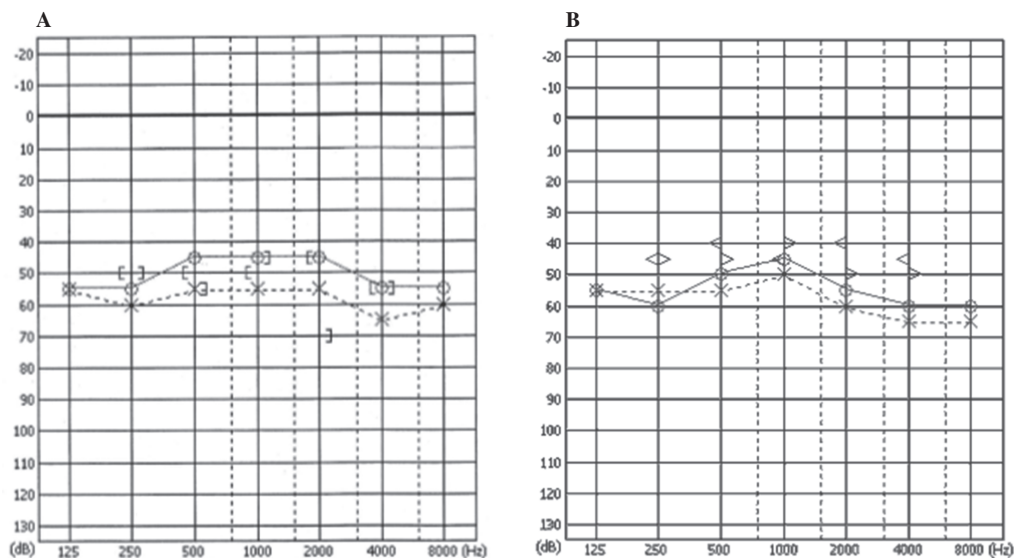


Fig. 3 The results of pure tone audiometry

Fig. 3A: Pure tone audiometry measurements taken 1 year before the vertigo attack of interest

Fig. 3B: On the day of this vertigo attack.

These measurements did not change markedly. The patient had no change in cochlear symptoms during these examinations.

DISCUSSION

We obtained 3-T MR images of EH on a vertigo attack of MD. The MR images revealed significant EH in the bilateral vestibule and cochlea, which was consistent with the clinical diagnosis of bilateral definite MD of the patient. Vestibular EH in each ear occupied almost all the vestibular endolymphatic space, herniating into the horizontal semi-circular canal, with no laterality revealed on the images. During the vertigo attack, the scala media remained swollen, without obvious evidence of ruptured membranes, though MRI could not visualize fine fissures in the membranes.

The left ear was the affected side during the vertigo attack in the present case. The cVEMP described a relative saccule dysfunction of the left ear on the day of the attack, which had resolved 50 days later. The spontaneous nystagmus, beating toward the right side, observed on the patient's arrival, a few hours after onset of the attack, appeared to be paralytic nystagmus.¹² Significant vestibular EH was also observed in the contralateral ear, herniating into the horizontal semi-circular canal, and in contact with the oval window. There was no clear difference between the ears on MRI, unlike in the cVEMP. The patient did not exhibit auditory symptoms despite the EH in the cochlea. This lack of simultaneous auditory symptoms during the time of attack is a frequent finding in MD.¹³

If obvious membranous rupture develops, as shown in past histological studies,^{2,4,5} the endolymphatic space may be invisible due to the contamination with contrast agent of the MRI method. The contamination of the perilymph by endolymph increases the concentration of potassium in the perilymph, resulting in a vertigo attack by depolarization of the vestibular hair cells.¹⁴ However, the EH of the affected ear was clearly enlarged, herniating into the horizontal semi-circular canal, which suggested that the membranes were only distended not ruptured. The

endolymphatic space in this case did not collapse. On the other hand, there was no evidence to counter the possibility of fine membranous fistulas.

Water or substance movements are thought to be requisite for vertigo attacks in the absence of ruptures. The vasopressin-aquaporin system regulates water reabsorption in the kidney and inner ear, and aquaporins are essential in mediating water transport through membranes and the subtypes of the aquaporins identified in the inner ear are involved in the pathogenesis of EH.¹⁵ Egami et al. explained the induction of vestibular disorders by desmopressin (a synthetic analog of 8-arginine vasopressin) in relation to EH, using animal models; MD attacks show rapid progression, in addition to chronic EH.¹⁶ EH itself did not cause MD symptoms in the right ear in the present case, or in a previous report.¹⁷ The endolymphatic sac is important in the regulation of endolymph volume. A previous study reported that the EH volume decreased after endolymphatic sac drainage in MD patients in whom the surgery was effective,¹⁸ which suggested that endolymph volume is increased or exceed the permissible level in the sac in MD, resulting in symptoms. Endolymph pressure is higher than perilymph pressure in EH models.¹⁹ Increased hydrostatic pressure with EH is speculated to change the membrane permeability for potassium, which could cause potassium to flow toward the perilymph, in molecular biological “membranous fistulas”. Moreover, the utriculo-endolymphatic valve is thought to separate the pars superior (utricle and semicircular canals) from the pars inferior (sacculle and cochlea) and to regulate the intra-utricular volume. This valve is normally closed, but is opened by excessive accumulation of endolymph, allowing excessive endolymph in the utricle to flow out and to be processed in the endolymphatic duct.^{20 21} However, the valve may be closed by highly excessive intra-utricular endolymph and/or perilymph pressure,²² suggesting a possibility that increases in EH and atmospheric pressure can increase force, closing the utriculo-endolymphatic valve. Gurkov et al. described that MD episodes were increased after exposure to heightened atmospheric pressure, but not after exposure to lowered atmospheric pressure.²³ The closed valve would further increase the pressure in the pars superior, which may play a role in MD-related vertigo attacks without auditory symptoms. Gibson also explained the vertigo attacks in the absence of ruptures and emphasized on the importance of the utriculo-endolymphatic valve.²⁴ In his theory, endolymph may build up excessively in the sinus of the endolymphatic duct during longitudinal flow, and overflow occurs opening the valve so endolymph enters the pars superior. Then the increase of endolymph in the utricle distorts the cristae in one direction, causing the attack of vertigo. Hornibrook have added a relation of detached otoconia to Gibson’s theory to explain the vertigo attack of MD.²⁵ Alternative concepts against the rupture hypothesis are spreading.

The present report suggests that MD attacks occur without large ruptures in the inner ear membrane. Clinical imaging of EH was reported by Nakashima and Naganawa et al for the first time in 2007.¹ Thereafter, many studies have focused on the MR imaging of EH and speculated on the mechanisms involved in MD. However only few reports directly show the condition of EH on vertigo attacks of MD to date. The present report is a single case study, further cases should be evaluated during an attack to clarify its mechanism.

ACKNOWLEDGMENT

We would like to thank ST. Erina Asai, ST. Anna Kogure, and ST. Emiko Shimizu for their assistance.

CONFLICT OF INTEREST

The authors declare no conflicts of interest associated with this manuscript.

FUNDING

This work was supported by JSPS KAKENHI (Grant Number JP18K16914).

ETHICAL CONSIDERATIONS

This clinical report was approved by the Ethical Standards Committee of National Center for Geriatrics and Gerontology (No.1254). Written informed consent was obtained from the patient for the publication.

REFERENCES

- 1 Nakashima T, Naganawa S, Sugiura M, et al. Visualization of endolymphatic hydrops in patients with Meniere's disease. *Laryngoscope*. 2007;117(3):415–420. doi:10.1097/MLG.0b013e31802c300c.
- 2 Schuknecht HF. Pathophysiology of endolymphatic hydrops. *Arch Otorhinolaryngol*. 1976;212(4):253–262. doi:10.1007/BF00453673.
- 3 Koskas HJ, Linthicum FH, Jr., House WF. Membranous ruptures in Meniere's disease: existence, location, and incidence. *Otolaryngol Head Neck Surg*. 1983;91(1):61–67. doi:10.1177/019459988309100111.
- 4 Kingma CM, Wit HP. The effect of changes in perilymphatic K⁺ on the vestibular evoked potential in the guinea pig. *Eur Arc Otorhinolaryngol*. 2010;267(11):1679–1684. doi:10.1007/s00405-010-1298-8.
- 5 Sperling NM, Paparella MM, Yoon TH, Zelterman D. Symptomatic versus asymptomatic endolymphatic hydrops: a histopathologic comparison. *Laryngoscope*. 1993;103(3):277–285. doi:10.1288/00005537-199303000-00007.
- 6 Okuno T, Sando I. Localization, frequency, and severity of endolymphatic hydrops and the pathology of the labyrinthine membrane in Meniere's disease. *Ann Otol Rhinol Laryngol*. 1987;96(4):438–445. doi:10.1177/000348948709600418.
- 7 Gürkov R, Flatz W, Louza J, Strupp M, Ertl-Wagner B, Krause E. Herniation of the membranous labyrinth into the horizontal semicircular canal is correlated with impaired caloric response in Meniere's disease. *Otol Neurotol*. 2012;33(8):1375–1379. doi:10.1097/MAO.0b013e318268d087.
- 8 Lopez-Escamez JA, Carey J, Chung WH, et al. Diagnostic criteria for Meniere's disease. *J Vestib Res*. 2015;25(1):1–7. doi:10.3233/VES-150549.
- 9 Naganawa S, Satake H, Kawamura M, Fukatsu H, Sone M, Nakashima T. Separate visualization of endolymphatic space, perilymphatic space and bone by a single pulse sequence; 3D-inversion recovery imaging utilizing real reconstruction after intratympanic Gd-DTPA administration at 3 Tesla. *Eur Radiol*. 2008;18(5):920–924. doi:10.1007/s00330-008-0854-8.
- 10 Naganawa S, Yamazaki M, Kawai H, Bokura K, Sone M, Nakashima T. Imaging of Meniere's disease by subtraction of MR cisternography from positive perilymph image. *Magn Reson Med Sci*. 2012;11(4):303–309. doi:10.2463/mrms.11.303.
- 11 Nakashima T, Naganawa S, Pyykko I, et al. Grading of endolymphatic hydrops using magnetic resonance imaging. *Acta Otolaryngol Suppl*. 2009;560:5–8. doi:10.1080/00016480902729827.
- 12 Kuo SW, Yang TH, Young YH. Changes in vestibular evoked myogenic potentials after Meniere attacks. *Ann Otol Rhinol Laryngol*. 2005;114(9):717–721. doi:10.1177/000348940511400911.
- 13 Gürkov R, Jerin C, Flatz W, Maxwell R. Clinical manifestations of hydropic ear disease (Menière's). *Eur Arch Otorhinolaryngol*. 2019;276(1):27–40. doi:10.1007/s00405-018-5157-3.
- 14 Meissner R. Behavior of the nystagmus in Meniere's attack. *Arch Otorhinolaryngol*. 1981;233(2):173–177.
- 15 Takumida M, Takumida H, Kakigi A, Egami N, Nishioka R, Anniko M. Localization of aquaporins in the mouse vestibular end organs. *Acta Otolaryngol*. 2013;133(8):804–813. doi:10.3109/00016489.2013.783717.
- 16 Egami N, Kakigi A, Sakamoto T, Takeda T, Hyodo M, Yamasoba T. Morphological and functional changes in

- a new animal model of Ménière's disease. *Lab Invest.* 2013;93(9):1001–1011. doi:10.1038/labinvest.2013.91.
- 17 Yoshida T, Sugimoto S, Teranishi M, et al. Imaging of the endolymphatic space in patients with Ménière's disease. *Auris Nasus Larynx.* 2018;45(1):33–38. doi:10.1016/j.anl.2017.02.002.
 - 18 Ito T, Inui H, Miyasaka T, et al. Three-Dimensional Magnetic Resonance Imaging Reveals the Relationship Between the Control of Vertigo and Decreases in Endolymphatic Hydrops After Endolymphatic Sac Drainage With Steroids for Meniere's Disease. *Front Neurol.* 2019;10:46. doi:10.3389/fneur.2019.00046.
 - 19 Böhmer A. Hydrostatic pressure in the inner ear fluid compartments and its effects on inner ear function. *Acta Otolaryngol Suppl.* 1993;507:3–24.
 - 20 Schuknecht HF, Belal AA. The utriculo-endolymphatic valve: its functional significance. *J Laryngol Otol.* 1975;89(10):985–996. doi:10.1017/s0022215100081305.
 - 21 Hofman R, Segenhout JM, Buytaert JA, Dirckx JJ, Wit HP. Morphology and function of Bast's valve: additional insight in its functioning using 3D-reconstruction. *Eur Arch Otorhinolaryngol.* 2008;265(2):153–157. doi:10.1007/s00405-007-0424-8.
 - 22 Konishi S. The ductus reuniens and utriculo-endolymphatic valve in the presence of endolymphatic hydrops in guinea-pigs. *J Laryngol Otol.* 1977;91(12):1033–1045. doi:10.1017/s0022215100084747.
 - 23 Gürkov R, Strobl R, Heinlin N, et al. Atmospheric Pressure and Onset of Episodes of Ménière's Disease - A Repeated Measures Study. *PLoS One.* 2016;11(4):e0152714. doi:10.1371/journal.pone.0152714.
 - 24 Gibson WPR. Hypothetical mechanism for vertigo in Meniere's disease. *Otolaryngol Clin North Am.* 2010;43(5):1019–1027. doi:10.1016/j.otc.2010.05.013.
 - 25 Hornibrook J. Saccular otoconia as a cause of Meniere's disease: hypothesis based on two theories. *J Laryngol Otol.* 2018;132(9):771–774. doi:10.1017/S0022215118001366.