

An intraoperative small distractor for non-open reduction and intramedullary fixation of pediatric displaced diaphyseal forearm fractures

Shinsuke Takeda^{1,2}, So Mitsuya^{1,2}, Katsuyuki Iwatsuki³, Miku Mitsuya^{1,2}, Ken-ichi Yamauchi² and Hitoshi Hirata³

¹*Trauma and Microsurgery Center, Toyohashi Municipal Hospital, Toyohashi, Japan*

²*Department of Orthopedic Surgery, Toyohashi Municipal Hospital, Toyohashi, Japan*

³*Department of Hand Surgery, Nagoya University Graduate School of Medicine, Nagoya, Japan*

ABSTRACT

This report describes technical tools for the treatment of pediatric displaced and unstable diaphyseal forearm fractures, which are difficult to treat by manual closed reduction. During intramedullary fixation with Kirchner wires, we propose our original small distractor as an intraoperative distraction apparatus without open reduction. This apparatus is made using parts of the Ilizarov external fixator. Apart from general external fixation devices, our apparatus is adequate for the effective shortening and lateral dislocation of the fracture site. This adequacy is not only because of the three-dimensional control by ball joints but also owing to the gradual adjustment structure of the Quick adjust strut (Orthofix, Verona, Italy), which allows tight and fine stretching, thus making the distractor an effective reduction tool. Our findings show the feasibility and usefulness of our reduction technique and small distractor. Our small distractor is a useful intraoperative distraction apparatus without open reduction for pediatric displaced and unstable diaphyseal forearm fractures that cannot be treated by manual closed reduction. In this report, we describe the distractor, the closed reduction technique, and the clinical results of four representative cases.

Keywords: small distractor, pediatric, displaced diaphyseal forearm fractures

Abbreviations:

IM: Intramedullary

K-wires: Kirchner wires

This is an Open Access article distributed under the Creative Commons Attribution-NonCommercial-NoDerivatives 4.0 International License. To view the details of this license, please visit (<http://creativecommons.org/licenses/by-nc-nd/4.0/>).

BACKGROUND

Intramedullary (IM) fixation with Kirchner wires (K-wires) or titanium elastic nails has emerged as the most common method for the fixation of pediatric displaced and unstable diaphyseal forearm fractures.^{1,2} However, not all patients can be treated by manual closed reduction and IM fixation. Although delayed union and pseudoarthrosis are uncommon in patients with

Received: October 22, 2020; accepted: December 3, 2020

Corresponding Author: Katsuyuki Iwatsuki, MD, PhD

Department of Hand Surgery, Nagoya University Graduate School of Medicine, 65 Tsurumai-cho, Shouwa-ku, Nagoya 466-0065, Japan

Tel: +81-52-744-2957, Fax: +81-52-744-2964, E-mail: kiwatsuki@med.nagoya-u.ac.jp

skeletal immaturity, an initial open reduction can increase the risk of these complications in such patients.^{3,4} Delayed union is mainly observed in pediatric middle-third forearm fractures and may increase the risk of refracture.^{3,4}

Mitsuya et al developed the original small distractor, made using parts of the Ilizarov external fixator, in Japan.^{5,6} This small distractor is useful as an intraoperative distraction apparatus for open reduction, especially for the small bones such as the forearm (radius and ulna) or the lower leg (fibula, talus, and calcaneus). They also reported the usefulness of this apparatus for closed reduction and IM fixation of pediatric displaced and unstable diaphyseal forearm fractures.

We describe a useful closed reduction technique by using the small distractor for pediatric diaphyseal forearm fractures that could not be treated by manual closed reduction. We also provide a description of the distractor and clinical results of four representative cases.

METHODS

Patient data

We conducted an institutional review board-approved retrospective study of the medical records at Toyohashi Municipal Hospital from October 2013 to September 2019. This study was approved by the institutional review board of Toyohashi Municipal Hospital. Patients were provided the opportunity to opt out of the study. We investigated patients with skeletal immaturity aged between 6 and 15 years at the time of injury who were diagnosed and treated operatively for middle-third both-bone forearm fractures. “Middle third” was defined as the distance between both ossified ends of the affected bone. Thirteen patients underwent IM fixation with K-wires for pediatric middle-third both-bone forearm fractures. Attempts of close manual reduction were unsuccessful in 4 of these 13 patients; therefore, they underwent reduction through our small distractor without open reduction (Table 1).

Table 1 Details and results of four cases

Case	Sex	Age (y)	Fracture side	Bone reduced by small distractor	Duration of cast immobilization (days)	Interval from surgery to K-wire removal (months)	Interval from surgery to union (weeks)	Residual axis deviation at consolidation (degrees)
1	Male	11	Left	Ulna	28	6	10	4
2	Female	11	Right	Radius	28	9	20	2
3	Male	7	Left	Radius	14	3	7	4
4	Male	10	Right	Radius	28	12	14	3

Description of the apparatus

Spring washers, Rancho cube (Smith and Nephew, Memphis, USA), and connection bolts are set at both ends of the Quick adjust strut (Orthofix, Verona, Italy) (Fig. 1A). This Quick adjust strut has two ball joints and two adjustment structures. This apparatus has three advantages. First, the Quick adjust strut has two different adjustment structures: acute adjustment structure for stretching at one time and gradual adjustment structure for tight and fine stretching (Fig. 1B). Second, the Quick adjust strut is controlled three-dimensionally by ball joints on both sides. Third, many sizes of pins such as K-wire, Steiman pin, and half pin are available for the rancho cubes.




Fig. 1 Structure of our small distractor

Fig. 1A: Spring washers, Rancho cube (Smith and Nephew, Memphis, USA), and connection bolts are set at both ends of the Quick adjust strut (Orthofix, Verona, Italy).

Fig. 1B: The Quick adjust strut has two different adjustment structures: acute adjustment structure (for stretching at one time) and gradual adjustment structure (for tight and fine stretching).

CASE EXAMPLE AND SURGICAL TECHNIQUE

Case 4

A 10-year-old boy with no medical history fell onto his right outstretched arm and presented to our hospital with complaints of pain and deformity of his right forearm. Radiography revealed complete and dislocated middle-third fractures of both the radius and ulna. Manual closed reduction under axillary block anesthesia was conducted in the operating room. However, manual closed reduction failed because of the shortening and lateral dislocation of the fracture site of the radius (Fig. 2A).

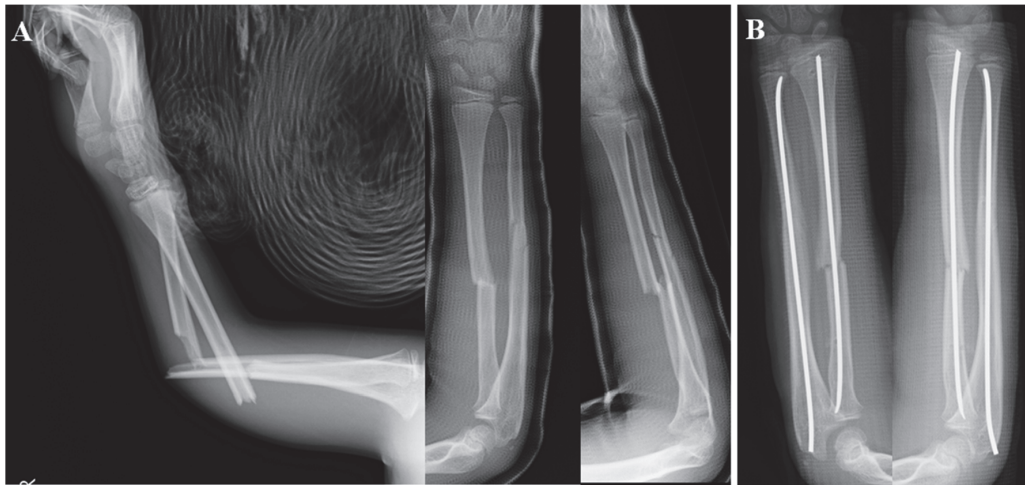


Fig. 2 Radiographs of case 4

Fig. 2A: Left radiograph shows the middle-third both-bone forearm fractures and right anteroposterior and lateral radiographs show shortening and lateral dislocation of the fracture site of the radius.

Fig. 2B: Postoperative radiographs.

Surgical technique

After the failure of manual closed reduction, we chose our closed reduction technique using the small distractor without skin incision in the fracture site for reduction. K-wires of 2.4 mm diameter were used for IM fixation of each forearm bone. A K-wire of 1.8 to 2.4 mm diameter is recommended, and a large-diameter K-wire should be used, if possible. The radial fracture was fixed retrogradely. K-wire in the radius was inserted just proximal to the physis, adjacent to Lister's tubercle. K-wire in the ulna was inserted just distal to the physis on the posterolateral part of the olecranon. The tips of the K-wires were bent by the surgeon with an angulation of approximately 20°.

In this case, we primarily performed IM fixation of the ulna with K-wire to avoid shortening and dislocation of its fracture site. Similarly, the radius underwent IM fixation with K-wire. Figure 3A shows the insertion of the 3-mm-diameter threaded wires (Mizuho Ika Kogyo, Tokyo, Japan). These two wires were inserted through the skin into the radius and held both just proximal to the physis of the distal radius and distal to the physis of the proximal radius. Two wires were inserted into the outer side holes of the Rancho cube of the small distractor and connection bolts were set firmly for the stability of these wires (Fig. 3B). K-wire was advanced into the medullary cavity carefully until reaching the proximal end of the distal fragment of the radius. Under fluoroscopy, we reduced the shortening and lateral dislocation of the fracture site as anatomically as possible. Distraction adjustment (acute adjustment followed by gradual adjustment) and three-dimensional control by ball joints of the Quick adjust strut facilitated this reduction. After reduction, K-wire was advanced into the proximal fragment of the radius (Fig. 3C). When the proximal threaded wire disturbed the advancement of the K-wire, we removed the small distractor and two threaded wires. K-wires were cut and buried beneath the skin (Fig. 2B). The cast was immobilized at 4 weeks postoperatively. The time between surgery and radiographic union was 14 weeks. At 12 months post-surgery, we removed the K-wire. At 18 months post-surgery, the patient showed no limitation of range of motion and no refracture.

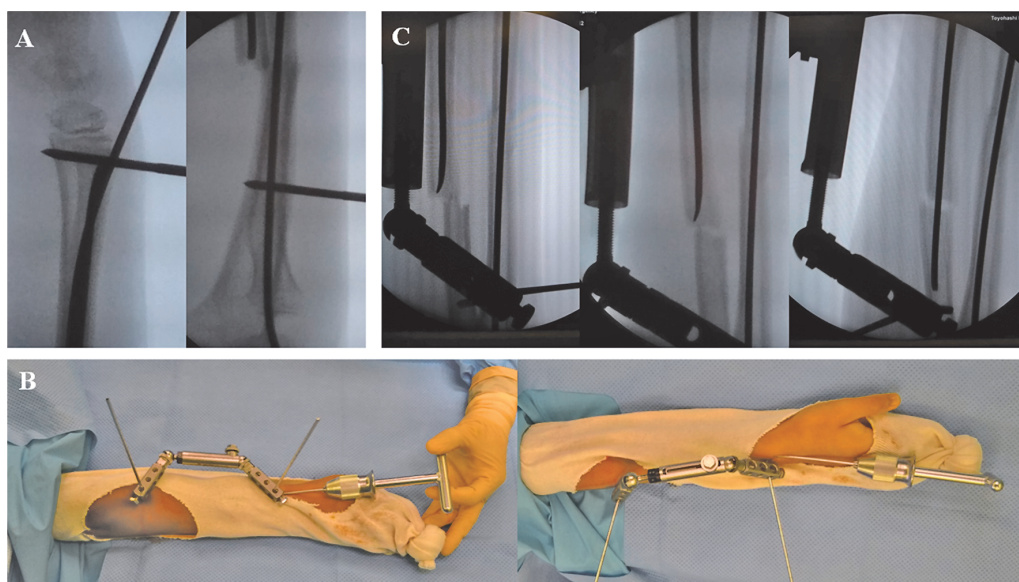


Fig. 3 Radiographs and images of intraoperative technique

Fig. 3A: Radiographs showing the insertion of the 3-mm-diameter threaded wires.

Fig. 3B: Images from two different angles showing the small distractor settings.

Fig. 3C: Left radiograph shows acute adjustment and middle radiograph shows gradual adjustment of the Quick adjust strut. Right radiograph shows K-wire advancement into the proximal fragment of the radius.

RESULTS

Table 1 shows the details and results of the four cases. All four cases had complete radial and ulnar fractures; 2.4-mm-sized K-wires were used for the radius and ulna in all four cases. All cases underwent an 18-month follow-up and had no complications, no limitation of range of motion, and no refracture. Case 2 had Gustilo-Anderson type I open fractures with a clean minimum pinhole skin injury at the ulna. Residual axis deviation at radiographic union was calculated for both bones, and a larger deviation was chosen. Radiographic union was defined as the absence of the fracture line (complete and circular consolidation) on four radiographic views: anteroposterior, lateral, and both obliques.

DISCUSSION

IM fixation is an effective treatment technique for unstable diaphyseal forearm fractures. The need for open reduction should be decided promptly following failed attempts of manual closed reduction. Makki et al reported that 33% patients undergo open reduction.⁷ Our reduction technique may help reduce the number of open reductions. Lobo-Escobar et al revealed that open reduction was the strongest predictor of delayed union because all their study patients with delayed healing had undergone surgery for reduction and stabilization of the fracture.³

The use of the small distractor is not limited by the patient's age, physical constitution, or fracture type. We have not experienced any complications related to this apparatus. In inserting the 3-mm-diameter threaded wires, it is necessary to prevent peripheral nerve injuries such as the posterior interosseous nerve of the proximal radius and the ulnar nerve of the proximal ulna.

Initial manual reduction is difficult because of the shortening and lateral dislocation of the fracture site. Although general external fixation devices have been used for several years for setting and stabilizing fractured bones with acute adjustment structure, they are not adequate for the effective reduction of the shortening and lateral dislocation of the fracture site. The gradual adjustment structure of our small distractor, which allows tight and fine stretching, makes it an effective reduction tool. Furthermore, preparation of the parts of the Ilizarov external fixator and the operative technique are not difficult.

CONCLUSION

We believe that our small distractor is a useful intraoperative distraction apparatus without open reduction for pediatric displaced and unstable diaphyseal forearm fractures that cannot be treated by manual closed reduction.

ACKNOWLEDGEMENTS

We are grateful to all the subjects who participated in this study.

We would also like to take this opportunity to thank Ichiro Takeda for advice.

CONFLICT OF INTEREST

None.

REFERENCES

- 1 Schmittbecher PP, Fitze G, Gödeke J, Kraus R, Schneidmüller D. Delayed healing of forearm shaft fractures in children after intramedullary nailing. *J Pediatr Orthop*. 2008;28(3):303–306. doi:10.1097/BPO.0b013e3181684cd6.
- 2 Calder PR, Achan P, Barry M. Diaphyseal forearm fractures in children treated with intramedullary fixation: outcome of K-wire versus elastic stable intramedullary nail. *Injury*. 2003;34(4):278–282. doi:10.1016/s0020-1383(02)00310-8.
- 3 Lobo-Escolar A, Roche A, Bregante J, Gil-Alvaroba J, Sola A, Herrera A. Delayed union in pediatric forearm fractures. *J Pediatr Orthop*. 2012;32(1):54–57. doi:10.1097/BPO.0b013e31823832ea.
- 4 Fernandez FF, Eberhardt O, Langendörfer M, Wirth T. Nonunion of forearm shaft fractures in children after intramedullary nailing. *J Pediatr Orthop B*. 2009;18(6):289–295. doi:10.1097/BPB.0b013e32832f5b20.
- 5 Mitsuya S, Mitsuya M, Hasegawa J, Fukui J, Yamauchi K, Mieno T. Reduction method during osteosynthesis using the small distractor manufactured with a rapid adjust strut [in Japanese]. *Cent Jpn J Orthop Traumat*. 2016;59(5):1023–1024. doi:10.11359/chubu.2016.1023.
- 6 Mitsuya S, Miyatsu Y, Haga T, Morozumi M, Watanabe M, Ogura A. Application to ESIN for fibular shaft fracture of reduction device" Small Distractor" operated on using an external fixator for wrists [in Japanese]. *Orthop Surg Traumatol*. 2013;56(1):91–95.
- 7 Makki D, Matar HE, Webb M, Wright DM, James LA, Ricketts DM. Elastic stable intramedullary nailing in paediatric forearm fractures: the rate of open reduction and complications. *J Pediatr Orthop B*. 2017;26(5):412–416. doi:10.1097/BPB.0000000000000408.