

## Examination of the effectiveness of bedside nasojejunal tube placement using a portable imaging device with a flat panel detector

Naohiro Takamoto<sup>1</sup>, Shinya Takazawa<sup>1</sup>, Yuki Yoshida<sup>2</sup>,  
Tamotsu Sasaki<sup>2</sup> and Akira Nishi<sup>1</sup>

<sup>1</sup>*Department of Pediatric Surgery, Gunma Children's Medical Center, Shibukawa, Japan*  
<sup>2</sup>*Department of Radiology, Gunma Children's Medical Center, Shibukawa, Japan*

### ABSTRACT

Transporting pediatric patients with severe cardiovascular complications to the fluoroscopy room can be difficult. Therefore, we started using a portable imaging device with a flat panel detector (FPD) for nasojejunal tube (NJT) placement. The purpose of this study was to investigate the differences in length of time of NJT placement and dosage of radiation exposure using a portable imaging device with FPD versus fluoroscopy. Pediatric patients who underwent NJT placement between April 2016 and December 2018 were identified retrospectively from the clinical records. The age, sex, body weight, and height of each child at the time of the procedure as well as the procedure time, outcomes of the procedure, and dosage of radiation exposure was compared between the two groups. In 76 cases of NJT placement (41 patients), there was no significant difference in the success rate of NJT placement between the FPD (90%) and fluoroscopy groups (95%). However, the NJT placement time was significantly longer in the FPD group than in the fluoroscopy group (488 s vs 291 s). According to our calculations, the radiation dosage was lower in the FPD group than in the fluoroscopy group (136  $\mu$ Gy per procedure vs 2819  $\mu$ Gy per procedure). These results suggest that NJT placement using a portable imaging device with an FPD can be an effective method for children who are difficult to transport with an equal success rate and lower dosage of radiation exposure compared with conventional fluoroscopy.

Keywords: nasojejunal tube, portable imaging device, fluoroscopy, entrance surface dosage

#### Abbreviations:

FPD: flat panel detector

NJT: nasojejunal tube

GERD: gastroesophageal reflux disease

This is an Open Access article distributed under the Creative Commons Attribution-NonCommercial-NoDerivatives 4.0 International License. To view the details of this license, please visit (<http://creativecommons.org/licenses/by-nc-nd/4.0/>).

---

Received: June 4, 2021; accepted: January 4, 2022

Corresponding Author: Akira Nishi, MD

Department of Pediatric Surgery, Gunma Children's Medical Center, 779 Shimohakoda, Hokkitsu-cho, Shibukawa 377-8577, Japan

Tel: +81-279-52-3551, Fax: +81-279-52-7333, E-mail: anishi@gcmc.pref.gunma.jp

## INTRODUCTION

The estimated prevalence of gastroesophageal reflux disease (GERD) in infants (0–23 months), children (2–11 years), and adolescents (12–17 years) are 2.2–12.6%, 0.6–4.1%, and 0.8–7.6%, respectively.<sup>1</sup> Symptoms of GERD usually improve as the child grows older; however, pediatric patients with severe cardiovascular complications grow slowly. This results in symptoms of GERD lasting for a prolonged period. In Japan, we use an anti-regurgitation formula or medication [proton pump inhibitors, H<sub>2</sub> receptor antagonists, or serotonin receptor antagonists] to initially treat pediatric patients with GERD. When symptoms of GERD do not improve, nasojejun tube (NJT) placement is generally performed to improve nutrition and promote weight gain.

Out of convenience, NJT placement is normally performed under fluoroscopy. Nevertheless, patients with severe cardiovascular complications who are intubated and connected to many syringe pumps are difficult to transport to the fluoroscopy room. Therefore, NJT insertion has not been performed in those patients. Recently, we introduced the use of a portable imaging device with a flat panel detector (FPD), which can be used at the bedside of the patient. An FPD is a thin sensor that converts an input X-ray image into a digital signal and outputs it as image data. Image generation with an FPD is almost a real-time process, with a time lapse between exposure and image display of <10 s. Several clinical studies have shown that a newer-generation flat-panel system provided superior image quality compared with a conventional image intensifier.<sup>2</sup> After converting to the use of a portable FPD device, the burden on surgeons appears to be reduced due to the ease and rapid detection of the position of the NJT tip.

NJT placement in pediatric patients with critical conditions using the portable imaging device with FPD has been performed at our hospital since April 2016. However, the advantages of this procedure over conventional placement under fluoroscopy have not been elucidated.

The purpose of this study was to investigate the differences in length of time of NJT placement and dosage of radiation exposure using the portable imaging device with FPD versus fluoroscopy.

## METHODS

### *Study design*

A retrospective review of pediatric patients who underwent NJT placement was performed. The institutional review board of our institution approved this retrospective review. Informed consent was obtained in the form of an opt-out through our hospital website.

Pediatric patients at our hospital weighing 1–8 kg who underwent NJT placement between April 2016 and December 2018 were included in this study. The participants were restricted by weight because our method of measuring the entrance surface dosage can only be applied to patients weighing 1–8 kg. If the tube broke or became obstructed, a new NJT was inserted.

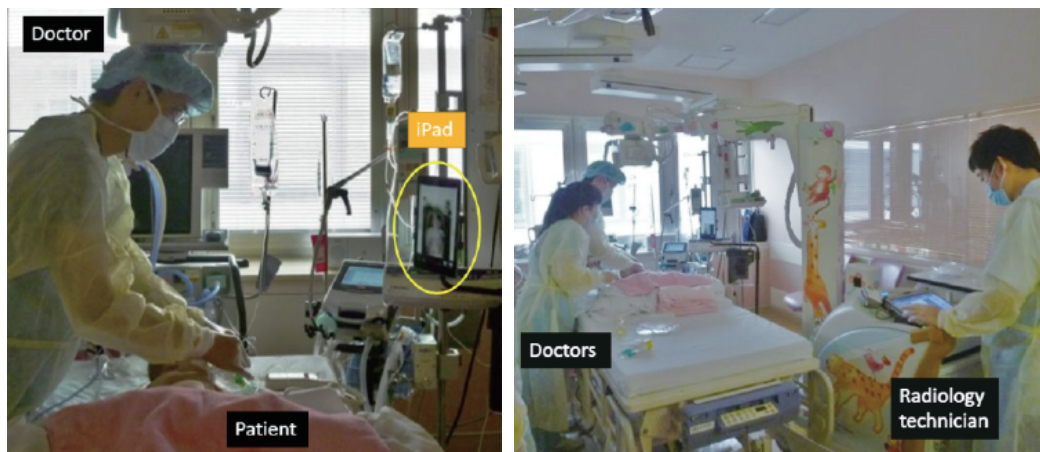
We recorded each pediatric patient's sex, age, body weight, and height at the time of NJT placement and noted any severe cardiovascular complications (single ventricle, hypoplastic left heart syndrome, coarctation of the aorta, complete atrioventricular septal defect, double-outlet right ventricle, complete transposition of the great arteries, truncus arteriosus, total anomalous pulmonary venous connection, anomalous origin of the left coronary artery from the pulmonary artery, Tetralogy of Fallot, ventricular septal defect, mitral regurgitation, and aortic stenosis).

We divided the patients into two groups according to whether they underwent NJT placement using a portable imaging device with FPD (FPD group) or fluoroscopy (fluoroscopy group). We compared the time taken for NJT placement between these two groups.

### Portable imaging device with FPD

The devices that we used were a portable imaging device (Mobile Art Evolution®, SHIMADZU, Kyoto, Japan), tablet device (iPad Air®, Apple Inc, Cupertino, California USA), and FPD (Aero DR®, KONICA MINOLTA, Tokyo, Japan). The tablet device was linked with the FPD app (cs-7®, KONICA MINOLTA, Tokyo Japan). It is easy to transport these devices to anywhere throughout the hospital.

Before a radiograph was taken, the FPD was inserted under the patient's body, the irradiation field of the portable imaging device was adjusted, and the tablet device was placed in front of the doctors. We normally place the tablet device to the left of the patient to reproduce the same setup used in the fluoroscopy room (Figure 1). When a radiograph is taken with the portable imaging device, the image will appear on the tablet after about 4 s. The X-ray machine's preparation time between each image acquisition was 14 s.



**Fig. 1** Photographs showing the set-up of the portable imaging device with a flat panel detector. We usually place the tablet device to the left of the patient and reproduce the same arrangement as in the fluoroscopy room.

### Tube placement

A non-weighted 120-cm enteral feeding tube made of radiopaque polyvinyl chloride (New enteral feeding tube®, Cardinal Health Inc, Dublin, Ohio USA) was used. The tube was inserted through the nostril with the patient in the supine position. This insertion method involved four phases: esophageal, gastric, duodenal, and jejunal. During each phase, the tube's position was assessed using either the FPD or fluoroscopy. The target of the tip of the tube was the jejunum, beyond the Treitz ligament. Finally, we used a contrast agent to confirm whether the tube placement was appropriate.

There were two points that required repeated X-ray imaging while inserting the NJT using the FPD. The first was to check whether the tip of the NJT was beyond the pylorus. In cases where difficulty was encountered while inserting the tube, we noted the length of the NJT from the nostril to the pylorus and attempted repeated insertion of the tube at that position. The second point was during insertion of the NJT beyond the pylorus while pulling out the guidewire. When advancing the tip, it was important to maintain optimal tension throughout the insertion procedure. Therefore, the NJT placement procedure was performed by two or more doctors with more than five years of clinical experience.

The tube can occasionally become clogged after it is in place for  $\geq 3$  months; to avoid this, we exchanged the tube every 3 months or when it was likely to be clogged.

#### Procedure time

We did not measure the precise procedure time of NJT insertion. In the FPD group, the procedure time was defined as the time between the first and last radiographs. In the fluoroscopy group, the procedure time was defined as the fluoroscopy time.

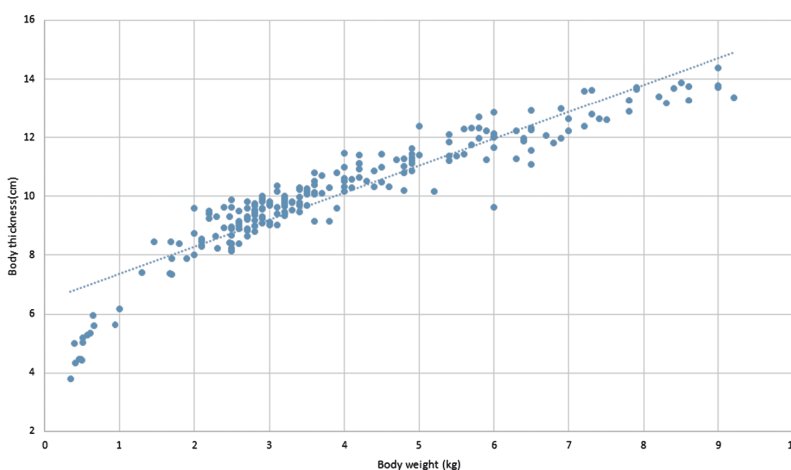
#### Radiation dosage

A preliminary experiment was conducted to measure the amount of radiation exposure in both the FPD group and fluoroscopy group using the original phantom model matched to this study population.

The department of radiology of our institution had previously reported the presence of a correlation between body weight and body thickness in pediatric patients and showed that a body weight of 1 kg to 8 kg corresponded to a body thickness of 6 cm to 14 cm (Figure 2).<sup>3</sup> The entrance surface dosage is commonly measured using a phantom model with a body thickness of 16 cm, but this model is too large for this study. We used a phantom model with a body thickness of 10 cm, because it is the middle value between 6 cm and 14 cm, to measure the entrance surface dosage in each group. The distance between the X-ray generator and the model was 100 cm. The entrance surface dosage for the model was measured five times each by a dosimeter placed on the model in both settings.

The mean surface dosage per irradiation of the FPD was 13.68  $\mu\text{Gy}$  (55 kV, 0.5 mAs), and the mean surface dosage per second under fluoroscopy was 9.69  $\mu\text{Gy}$  (70 kV, 0.4 mAs, pulsed 7.5 f/s).

Therefore, we defined the total radiation dosage as the product of 13.68  $\mu\text{Gy}$  and the number of images in the FPD group, and the product of 9.69  $\mu\text{Gy}$  and the procedure time in the fluoroscopy group. The dosage of some pictures taken during the fluoroscopy was ignored as lower than continuous exposure.



**Fig. 2** Association between body thickness and body weight

The department of radiology in our institution had previously conducted a study to measure the body thickness of 217 patients aged 0 to 12 months by computed tomography. The association between body thickness and body weight among the 217 patients is shown.

*Statistical analysis*

All statistical analyses were performed using EZR software version 1.37 (Saitama Medical Center, Jichi Medical University, Saitama, Japan). We used Student's t-test to compare the means of normally distributed continuous variables, the Mann-Whitney U test to compare the medians of non-normally distributed continuous variables, and Fisher's exact test to compare the proportions of categorical variables.  $P < 0.05$  was considered statistically significant.

## RESULTS

We collected the details of 110 cases (54 patients) who underwent NJT placement between April 2016 and December 2018. Among the 110 cases, 12 cases were excluded because the patients weighed  $>8$  kg, 14 cases were excluded because they underwent NJT placement for either postoperative ileus or adhesive small bowel obstruction, and 8 cases (1 patient) were excluded because there was no success in inserting the NJT due to abnormal form of the duodenum. Contrast radiography of the upper gastrointestinal tract of this last patient who was excluded showed that the abnormality was the presence of an acute angle between the descending part and the horizontal part of the duodenum.

Of the remaining 76 cases (41 patients), 30 cases (39%) underwent NJT placement by the FPD method (FPD group) and 46 cases (61%) underwent the procedure under fluoroscopy (fluoroscopy group). Four patients underwent both procedures. Table 1 shows the characteristics of the two groups.

There were no significant differences in sex, age, body weight, and height at the time of NJT placement between the two groups. However, the cardiovascular complication rate was significantly higher in the FPD group (97%) than in the fluoroscopy group [69%;  $p = 0.003$ ; odds ratio (OR): 12.37; 95% confidence interval (CI): 1.68–553.06; Table 1], and the rate of admission in the pediatric intensive care unit (PICU) was significantly higher in the FPD group (97%) than in the fluoroscopy group [20%;  $p < 0.001$ ; OR: 108.85; 95% confidence interval (CI): 14.54–4826.70; Table 1].

There was no significant difference in the success rate of NJT placement between the two

**Table 1** Characteristics and complications in the FPD and fluoroscopy groups

	FPD (N=30 cases)	Fluoroscopy (N=46 cases)	P-value
<b>Sex (male) [number (percentage)]</b>	18 (60%)	19 (41%)	0.16
<b>Age (months)*</b>	8.5 (5–20)	14.0 (5.25–22)	0.44
<b>Body weight (kg)**</b>	5.32 (1.66)	5.68 (1.44)	0.32
<b>Height (cm)**</b>	65.37 (10.16)	63.90 (6.82)	0.45
<b>Cardiovascular complication (Yes)</b>	29 (97%)	32 (69%)	$< 0.01$
<b>Admission in PICU</b>	29 (97%)	9 (20%)	$< 0.01$

Seventy-six cases of NJT placement performed in 41 patients were included in this study.

\*Data are shown as median (interquartile range).

\*\*Data are shown as mean (standard deviation).

FPD: flat panel detector

PICU: pediatric intensive care unit

groups [90% (FPD) vs 96% (fluoroscopy)]. However, the procedure time for tube insertion was significantly longer in the FPD group [median time, 488 s (8 min 8 s)] than in the fluoroscopy group [median time, 291 s (4 min 51 s;  $p = 0.04$ )]. In the FPD group, the median number of images was 11 (Table 2).

We calculated the approximate entrance surface dosage in the two groups. Based on the data of a previous study,<sup>3</sup> a body weight of 1 kg to 8 kg corresponds to a body thickness of 6 cm to 14 cm, and we defined the patient's body thickness in this study to be approximately 10 cm. The entrance surface dosage per procedure in the FPD group was vastly lower than that in the fluoroscopy group (136.80  $\mu$ Gy vs 2819.79  $\mu$ Gy, median;  $p < 0.001$ ; Table 2).

We experienced some complications during NJT placement. There were no significant differences in the rates of dislodgment, intussusception, and perforation between the FPD and fluoroscopy groups. However, the rate of clogging was significantly lower in the FPD group than in the fluoroscopy group (6% vs 26%;  $p = 0.038$ ; Table 3). No cardiovascular complications such as hypotension, bradycardia, or new arrhythmias were observed during NJT placement in any patient.

There were three failure cases of NJT placement in the FPD group and two failure cases in the fluoroscopy group. In one failure case in the FPD group, the NJT could not be placed beyond the Treitz ligament; therefore, the patient was moved to the fluoroscopy room for NJT placement. In the second failure case in the FPD group, the NJT was placed in front of the Treitz ligament in the middle of the night and the X-ray obtained the next morning confirmed that it had been placed beyond the Treitz ligament. In the third failure case in the FPD group, we tried to place the NJT in between other procedures, but it was difficult; therefore, we attempted NJT placement by the FPD method again after the other procedures were completed and succeeded.

**Table 2** Placement time, radiation exposure, and success rate in nasojejunal tube placement in the FPD and fluoroscopy groups

	<b>FPD (N=30 cases)</b>	<b>Fluoroscopy (N=46 cases)</b>	<b>P-value</b>
<b>Nasojejunal tube placement time (s)*</b>	488 (317–915)	291 (219–479)	0.04
<b>Number of images*</b>	11 (8–14)	—	—
<b>Radiation exposure (<math>\mu</math>Gy)*</b>	136.80 (109.44–164.16)	2819.79 (2122.11–4646.35)	<0.01
<b>Number of successful cases (percentage)</b>	27 (90%)	44 (96%)	0.72

\*Data are shown as median (interquartile range).

FPD: flat panel detector

**Table 3** Number and rate of complications with nasojejunal tube placement in the FPD and fluoroscopy groups

	<b>FPD (N=30)</b>	<b>Fluoroscopy (N=46)</b>	<b>P-value</b>
<b>Clogging</b>	2 (6%)	12 (26%)	0.04
<b>Dislodgement</b>	6 (20%)	5 (11%)	0.33
<b>Intussusception</b>	1 (3%)	2 (4%)	1.00
<b>Perforation</b>	0 (0%)	0 (0%)	1.00

FPD: flat panel detector

The two failure cases in the fluoroscopy group were due to difficulties in placing the NJT. Therefore, we attempted NJT placement under fluoroscopy again at a later date and succeeded in both cases.

We excluded these five failure cases of NJT placement and performed the statistical analysis again because we thought that there was a possibility that the failures in these five cases prolonged the procedure time. Of the remaining 71 cases (41 patients), 27 cases (38%) underwent NJT placement by the FPD method (FPD group) and 44 cases (62%) underwent the procedure under fluoroscopy (fluoroscopy group). Three patients underwent both procedures. Table 4 summarizes the characteristics of the two groups, while Table 5 shows the placement time, radiation exposure, and success rate of the two groups. There were no clear differences in the results of the analyses between the original data and the data in which the five failure cases were excluded.

**Table 4** Characteristics and complications in the FPD and fluoroscopy groups excluding the five failure cases of nasojejunal tube placement

	<b>FPD</b> (N=27 cases)	<b>Fluoroscopy</b> (N=44 cases)	<b>P-value</b>
<b>Sex (male) [number (percentage)]</b>	16 (59%)	18 (41%)	0.15
<b>Age (months)*</b>	9 (5–20)	14 (5–22)	0.44
<b>Body weight (kg)**</b>	5.31 (1.70)	5.68 (1.47)	0.34
<b>Height (cm)**</b>	65.28 (10.12)	63.91 (6.94)	0.50
<b>Cardiovascular complication (Yes)</b>	26 (96%)	31 (70%)	0.012
<b>Admission in PICU</b>	26 (96%)	9 (20%)	<0.01

Seventy-one cases of NJT placement performed in 41 patients were included in this analysis.

\*Data are shown as median (interquartile range).

\*\*Data are shown as mean (standard deviation).

FPD: flat panel detector

PICU: pediatric intensive care unit

**Table 5** Placement time, radiation exposure, and success rate in nasojejunal tube placement in the FPD and fluoroscopy groups excluding the five failure cases of nasojejunal tube placement

	<b>FPD</b> (N=27 cases)	<b>Fluoroscopy</b> (N=44 cases)	<b>P-value</b>
<b>Nasojejunal tube placement time (s)*</b>	480 (316–861)	284 (214–456)	<0.01
<b>Number of images*</b>	10 (8–13)	—	—
<b>Radiation exposure (μGy)*</b>	136.80 (109.44–164.16)	2756.80 (2076.08–4421.06)	<0.01
<b>Number of successful cases (percentage)</b>	27 (100%)	44 (100%)	1.00

\*Data are shown as median (interquartile range).

FPD: flat panel detector

## DISCUSSION

Pediatric patients at our hospital weighing 1–8 kg who underwent NJT placement were divided into two groups according to whether they underwent NJT placement by the FDP method or under fluoroscopy in this study. There was no significant difference in age, body weight and height between the FPD and fluoroscopy groups. Hence, we deduced that physical differences did not contribute to the difficulty of NJT placement. In this study, the cardiovascular complication rate was significantly higher in the FPD group than in the fluoroscopy group. Typically, it is difficult to transport a child admitted to the PICU due to the child having intravenous lines or being intubated. The number of children admitted to the PICU before and after surgery for cardiovascular disease is high in our hospital; hence, the rates of cardiovascular complications and PICU admissions were higher in the FPD group.

The success rate of NJT placement under fluoroscopy varied from 92.4–100% across various studies, and the procedure time varied from 5–10 min.<sup>4,7</sup> In the present study, the success rate of NJT placement was 90% in the FPD group and 96% in the fluoroscopy group. While there was no significant difference in the success rate of NJT placement between the two groups, the success rates were slightly lower than in other studies. In the present study, the median procedure time was 488 s (8 min 8 s) in the FPD group and 291 s (4 min 51 s) in the fluoroscopy group, showing a significant difference. However, the procedure time in the FPD group in the present study was comparable to the procedure time under fluoroscopy in previous studies.<sup>4,7</sup>

The Society for Pediatric Radiology has raised some concerns over fluoroscopy dose optimization and dosage reduction in pediatric patients. Last image hold, or fluoro save, is the display of the last fluoroscopic image on the display monitor when the fluoroscopy pedal is released to terminate the fluoroscopic run. By using this function, the operators can spend as much time as necessary studying the anatomy and other findings without incurring any additional radiation dosage to the patient.<sup>8</sup> Hoffer et al reported that the mean fluoroscopic time for NJT placement was 6.2 min.<sup>4</sup> In contrast, Rao et al showed that it was possible to reduce the fluoroscopic radiation time using the fluoro save technique, resulting in a median fluoroscopy time of 1.25 min (75 s) for nasoenteral tube placement.<sup>9</sup> We often tended to overuse fluoroscopic imaging to follow the tip of the NJT under fluoroscopy; in contrast, it was easier to prevent overuse of radiation when using a portable imaging device with FPD because it took about 14 s to be able to irradiate again after the initial irradiation procedure; thus, the fluoro save technique was automatically instituted. This may be the reason for the lower entrance surface dosage in the FPD group than in the fluoroscopy group.

Many attempts have been made to reduce the radiation exposure of children under fluoroscopy, such as through the use of pulsed fluoroscopy or the fluoro save technique. However, there is no optimal method of NJT placement in children who are difficult to transport to the fluoroscopy room. Some studies have investigated NJT placement by using ultrasonography; however, the tip of the tube could only be confirmed to pass beyond the pylorus, and procedure times were longer.<sup>10–12</sup> In a study of adults, insertion of a spiral NJT was performed by placing the NJT in the stomach and allowing it to naturally migrate to the duodenum. The patients in that study were divided into three groups according to whether they received metoclopramide, domperidone or no medication. The success rate of post-pyloric placement after 24 hours was 55.0%, 51.5%, and 27.3%, respectively.<sup>13</sup> In a pediatric study, the NJT whose tip had been processed with some silk thread, was inserted into the stomach and was allowed to naturally migrate to the duodenum using metoclopramide. The success rate was 70% after 4 hours, 88% after 24 hours and 94% after 48 hours.<sup>14</sup> In any case, the technique of placing an NJT in the stomach and allowing it to naturally advance to the duodenum is time-consuming and has a low success rate. Comparatively,



the burden on the operator using the FDP method may be reduced because the image during tube placement using an FPD is closer to the image under fluoroscopy, and the position of the tube can be identified accurately.

Pediatric GERD guidelines showed that NJT placement was associated with high rates of complications including clogging (29%), dislodgment (66%), intussusception (20%), and perforation (2–3%).<sup>2</sup> In our study, there were no significant differences in the rates of dislodgment (20% vs 11%), intussusception (3% vs 4%), and perforation (0% vs 0%) between the FPD and fluoroscopy groups. However, the rate of clogging was significantly lower in the FPD group than in the fluoroscopy group (6% vs 26%;  $p = 0.038$ ). We believe that this was because the number of patients whose NJT was placed for a long period of time or who required a new NJT due to a broken or obstructed tube was higher in the FPD group.

None of the five failure cases of NJT placement in the present study was due to complications that interrupted NJT placement. In one case, NJT placement by the FDP method was difficult, and the patient was transported to the fluoroscopy room for NJT placement under fluoroscopy. In the other four cases, NJT placement could not be performed in the allotted time due to time constraints.

We were concerned about excessive pressure to the intestine during the blind insertion procedure in the FPD group. However, we discovered that we felt more tension in the tube during NJT placement using an FPD than during NJT placement with fluoroscopy. There were no recorded cases of perforation.

The department of radiology in our institution had studied extra-radiation exposure on patients who were near the patient being irradiated.<sup>3</sup> Per irradiation, the exposure dosage using a portable imaging device with an FPD 50, 100, and 200 cm away from the X-ray generator was 0.037, 0.008, and 0.004  $\mu\text{Sv}$ , respectively. In our PICU, the distance between other patients and the FPD was more than 200 cm. Therefore, we believe that there was minimal extra-radiation exposure to other patients in the FPD group.

There were some limitations in our study. First, the number of cases was small. Second, we could not measure the precise procedure time of NJT placement or entrance surface dosage in either group because of the retrospective nature of the study. Third, the cardiovascular complication rate and the rate of admission in the PICU were significantly higher in the FPD group than in the fluoroscopy group. This may have been a selection bias.

In conclusion, NJT placement using a portable imaging device with an FPD can be an effective method for children who are difficult to transport with an equal success rate and lower exposure dosage compared with conventional fluoroscopy.

## CONFLICT OF INTEREST

The authors declare that they have no conflict of interest.

## ETHICS APPROVAL

All procedures performed in studies involving human participants were in accordance with the ethical standards of the institutional and/or national research committee and 1964 Declaration of Helsinki and its later amendments or comparable ethical standards. This study was approved by the Bioethics Committee of Gunma Children's Medical Center (Certification number: GCMC2019-109).

## INFORMED CONSENT

Informed consent was obtained in the form of an opt-out option on our hospital website.

## MEETING PRESENTATION

A part of this article was presented at the 55th Annual Meeting of Japanese Society of Pediatric Radiology; June 21–22, 2019; Kobe Japan.

## REFERENCES

- 1 Mousa H, Hassan M. Gastroesophageal Reflux Disease. *Pediatr Clin North Am.* 2017;64(3):487–505. doi:10.1016/j.pcl.2017.01.003.
- 2 Weis M, Hagelstein C, Diehm T, Schoenberg SO, Neff KW. Comparison of image quality and radiation dose between an image – intensifier system and a newer-generation flat-panel detector system – technical phantom measurements and evaluation of clinical imaging in children. *Pediatr Radiol.* 2016;46(2):286–292. doi:10.1007/s00247-015-3456-z.
- 3 Sasaki T, Kogure Y, Yoshida Y, et al. Examination of optimal CT dosage in pediatric Ai: considering the appearance of artifacts [in Japanese]. *JART.* 2016;63(9):1098.
- 4 Hoffer F, Sandler RH, Kaplan LC, Mandell VS, Haynie M, Leichner A. Fluoroscopic placement of jejunal feeding tubes. *Pediatr Radiol.* 1992;22(4):287–289. doi:10.1007/BF02019862.
- 5 Hwang JY, Shin JH, Lee YJ, et al. Fluoroscopically guided nasojejunal enteral tube placement in infants and young children. *AJR Am J Roentgenol.* 2009;193(2):545–548. doi:10.2214/AJR.08.1341.
- 6 Pobielski RS, Bisset GS 3rd, Pobielski MS. Nasojejunal feeding tube placement in children: four-year cumulative experience. *Radiology.* 1994;190(1):127–129. doi:10.1148/radiology.190.1.8259389.
- 7 Vitta L, Raghavan A, Morrell R, Sprigg A. Fluoroscopy-guided insertion of nasojejunal tubes in children – setting local diagnostic reference levels. *Pediatr Radiol.* 2009;39(11):1203–1208. doi:10.1007/s00247-009-1362-y.
- 8 Hernanz-Schulman M, Goske MJ, Bercha IH, Strauss KJ. Pause and pulse: ten steps that help manage radiation dosage during pediatric fluoroscopy. *AJR Am J Roentgenol.* 2011;197(2):475–481. doi:10.2214/AJR.10.6122.
- 9 Rao AG, Simmons CE Sr, Collins H, Tipnis SV, Hill JG, Ritenour ER. Fluoroscopy-guided placement of nasoenteral tubes in children using intermittent digital pulse fluoroscopy and last image save/grab technique. *Clin Radiol.* 2016;71(9): 939.e9–939.e13 doi:10.1016/j.crad.2016.03.017.
- 10 Dağlı R, Bayir H, Dadali Y, Tokmak TT, Erbesler ZA. Role of ultrasonography in detecting the localisation of the nasenteric tube. *Turk J Anaesthesiol Reanim.* 2017;45(2):103–107. doi:10.5152/TJAR.2017.80269.
- 11 Li G, Pan Y, Zhou J, Tong Z, Ke L, Li W. Enteral nutrition tube placement assisted by ultrasonography in patients with severe acute pancreatitis. *Medicine (Baltimore).* 2017;96(45):e8482. doi:10.1097/MD.0000000000008482.
- 12 Hernández-Socorro CR, Marin J, Ruiz-Santana S, Santana L, Manzano JL. Bedside sonographic-guided versus blind nasenteric feeding tube placement in critically ill patients. *Crit Care Med.* 1996;24(10):1690–1694. doi:10.1097/00003246-199610000-00015.
- 13 Hu B, Ye H, Sun C, et al. Metoclopramide or domperidone improves post-pyloric placement of spiral nasojejunal tubes in critically ill patients: a prospective, multicenter, open-label, randomized, controlled clinical trial. *Crit Care.* 2015;19(1): 61. doi:10.1186/s13054-015-0784-1.
- 14 Kaddah M, El-Mefleh N, Ba’Ath ME. The “Silk Road”: A novel method for inserting transpyloric feeding tubes in low resource settings. *J Pediatr Surg.* 2020;55(3):573–575. doi:10.1016/j.jpedsurg.2019.08.056.