

主論文の要約

**Supernatant from Activated Omentum Accelerates
Wound Healing in Diabetic mice wound model**

〔 活性化大網培養上清を用いた糖尿病潰瘍に与える影響 〕

名古屋大学大学院医学系研究科 総合医学専攻
運動・形態外科学講座 形成外科学分野

(指導：亀井 讓 教授)

李 宇

【Introduction】

Diabetic wounds (DWs) are the most common complications in patients with diabetes mellitus, which is a result of poor glycemic control, narrowed peripheral vessels, underlying neuropathy, and poor immune response. Thus far, the available therapeutic approaches have limitations and none appear adequate to guarantee successful. Hence, there is an urgent need for a therapeutic alternative to currently available treatments.

The omentum is a highly vascularized fibrous fatty layer of tissue located in the abdominal cavity, serving as a layer of coverage and protection. It is known to possess healing potential for over 100 years, mediated by omentum transportation, owing to its angiogenic, immunogenic, and lymphatic properties.

Recently, some studies showed that the activated omentum, with rich of growth factors and characteristics of stem cells, have ability of tissue regeneration. The present work aimed to investigate the effect of supernatant from activated omentum condition medium on diabetic mice skin wound model.

【Methods】

C57BL/6 male mice were randomly divided into three groups: (1) the control group (c), which served as a negative control without any interference; (2) the saline group (s), where 0.5 mL saline was injected intraperitoneally; and (3) the activated group (a), where 0.5 mL polydextran particle slurry was injected intraperitoneally¹⁶. After 2 weeks, the omentum was harvested, weighted and then cultured at 37°C. The omentum conditioned medium (OCM) of three groups were collected after 48 hours culturing, meanwhile, protein density was measured.

Thirty-six 12weeks C57BLKS/J Lepr^{db} (db/db) mice female diabetic mice were randomly divided into four groups, which were injected with medium (M), saline-OCM (sOCM), inactivated-OCM (iOCM), and activated-OCM (aOCM) subcutaneously. Wound closure (%) were evaluated on days 0, 3, 5, 7, 9, 11, 14, 21, 28 post-treatments. As for histology analyses, we performed hematoxylin and eosin staining and Masson's trichrome staining on days 9 and 28 post-treatments for gross observation and collagen volume fraction (CVF) assessment respectively. To investigate newly vessels and nerve fibers regeneration degree on days 9 post-treatments, fluorescent immunostaining and quantification were performed.

【Results】

1. Characteristics of activated omentum and aOCM

The intraperitoneal injection of polydextran particles caused the omentum to spread rapidly and was activated within 2 weeks. Notably, the omentum of group (a) gained significantly more weight and higher protein density than that of groups (c) and (s) (Fig. 1A, 1B).

2. aOCM accelerated re-epithelialization in a diabetic murine wound model

aOCM group showed smaller wound closure (%) than that in the other three groups, thus demonstrating that aOCM significantly accelerated wound closure from day 7 to day 11 compared to that in the M, iOCM, and sOCM (Fig. 2A). Furthermore, the time taken for 50% wound healing in aOCM group was significantly faster than that in the other three groups ($p < 0.0001$) (Fig. 2B)

3. aOCM promoted angiogenesis, nerve regeneration and collagen density in diabetic mice model in early wound healing stage

Newly formed vessels at the wound sites were examined by CD31 and α -SMA co-staining. According to vessel quantification, on day 9 post-treatments, the average vessel number in the aOCM group was significantly higher than other three groups ($p < 0.001$) (Fig. 3A). Additionally, newly formed peripheral nerve fibers were stained with NF-L antibody and quantified in M, iOCM, sOCM, and aOCM groups at day 9 which were 20.67 ± 5.28 , 20.17 ± 4.17 , 20.83 ± 8.70 , and 36.50 ± 11.0 , respectively ($p < 0.05$) (Fig. 3B). As for CVF, aOCM administration significantly enhanced CVF as demonstrated by increased blue-stained, especially on day 9 post-operation. ($p < 0.0001$) (Fig. 3C).

【Discussion】

In clinics, the omentum-free flap has a wide variety of applications in reconstructive surgery and has been shown to be a reliable donor tissue. Further, it has been reported that activated omentum become a rich source for growth factors including fibroblast growth factor and vascular endothelial growth factor. In this study, we demonstrate for the first time that aOCM can accelerate wound healing in the early wound healing process in diabetic mice. Animal experiments indicated that aOCM significantly accelerated the re-epithelialization rate from days 7 to 11 post-operation. In early wound healing process, aOCM tended to promote angiogenesis and peripheral nerve fibers regeneration at the edges of the wound. Moreover, our findings indicate that aOCM can promote collagen deposition in the early stages of wound healing in diabetic mice. Furthermore, according to our mass spectrometry analysis, the aOCM group had abundant proteins, which potentially contributed to re-epithelialization, granulation tissue formation, inflammatory regulation, neovascularization, and peripheral nerve regeneration (Table. 1). Nevertheless, further experiments are necessary to determine the molecular mechanisms underlying these observed effects.

Additionally, despite the fact that the omentum is regarded as a reliable donor site in recent studies, the donor-site morbidity and complications such as intestinal obstruction and herniation remain after omentum harvesting. Our study used conditioned medium from the activated omentum, which is abundant in groups of proteins and potentially contributes to wound healing in a diabetic mouse wound model. Our findings in animals support the potential use of aOCM for wound treatment in patients with diabetes. Taken together, the cocktail gel

or mixture minimizes donor-site morbidity in the future and it may provide a new therapeutic method for treating DWs.

【Conclusions】

The results of our study suggested that administration of supernatant from activated omentum enhance the wound closure in early stage compare with other groups. Meanwhile, activated omentum can obviously promote the angiogenesis, nerve regeneration and collagen deposition in diabetic mouse wound model, which may provide us a new therapy for diabetic ulcer.

Table 1. Protein enrichment in supernatants and their potential contribution to wound healing.

Accession	Description	MW [kDa]	PMS (Peptide spectrum match)			Contribution to wound healing
			iOCM	sOCM	aOCM	
O70370	Cathepsin S	38.45	1	6	53	Angiogenesis; Wound closure
Q61292	Laminin subunit beta-2	196.45	2	8	62	Angiogenesis; Re-epithelization
Q91X72	Hemopexin	51.29	15	12	333	Enhanced peripheral nerve regeneration
P35441	Thrombospondin-1	129.56	6	17	67	Re-epithelization
Q61554	Fibrillin-1	312.08	30	68	259	Formation of granulation
Q8VCM7	Fibrinogen gamma chain	49.36	12	17	98	Angiogenesis; Formation of granulation
Q61001	Laminin subunit alpha-5	403.79	6	13	44	Re-epithelization; Collagen deposition
P11276	Fibronectin	273.36	102	161	512	Re-epithelization, Collagen deposition; angiogenesis

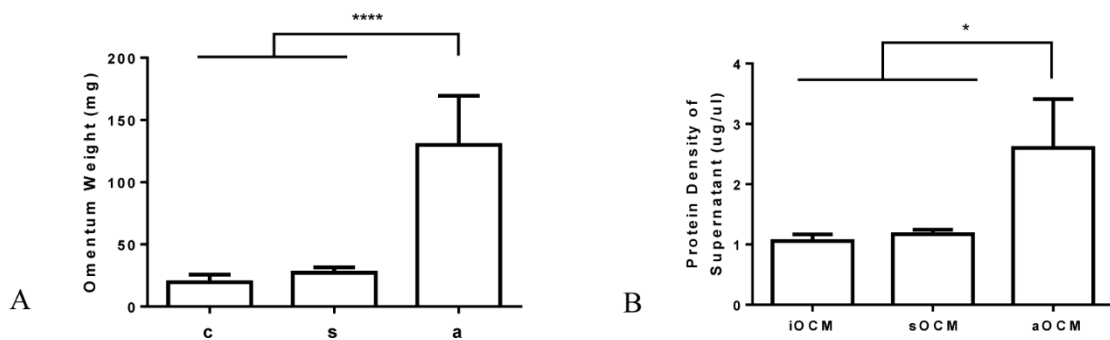


Figure 1. Characteristics of activated omentum and aOCM.

A. Omentum weight in each group. **** $p < 0.0001$.

B. Protein concentration in each group. * $p < 0.05$.

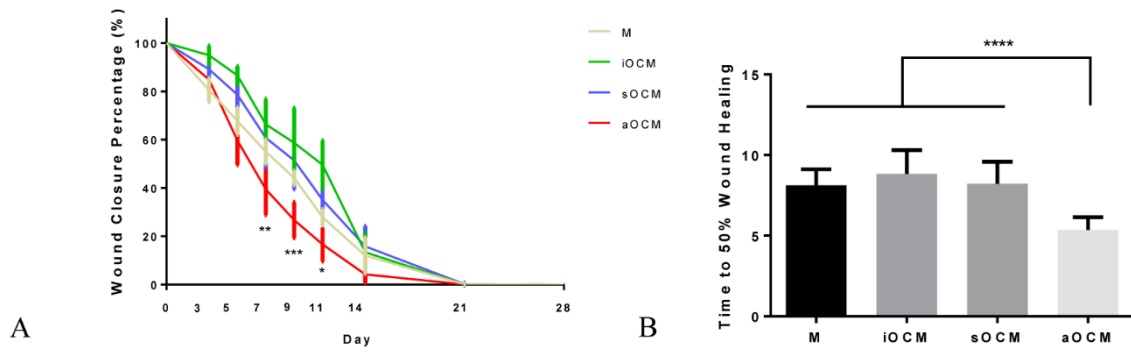


Figure 2. aOCM accelerated re-epithelialization in a diabetic murine wound model.

- A. The wound closure percentage (%) was determined on days 0, 3, 5, 7, 9, 11, 14, 21, 28 post-treatments in each group. * $p < 0.05$; ** $p < 0.01$; *** $p < 0.001$.
- B. Average time taken for 50% wound healing in M, iOCM, sOCM, and aOCM groups. **** $p < 0.0001$.

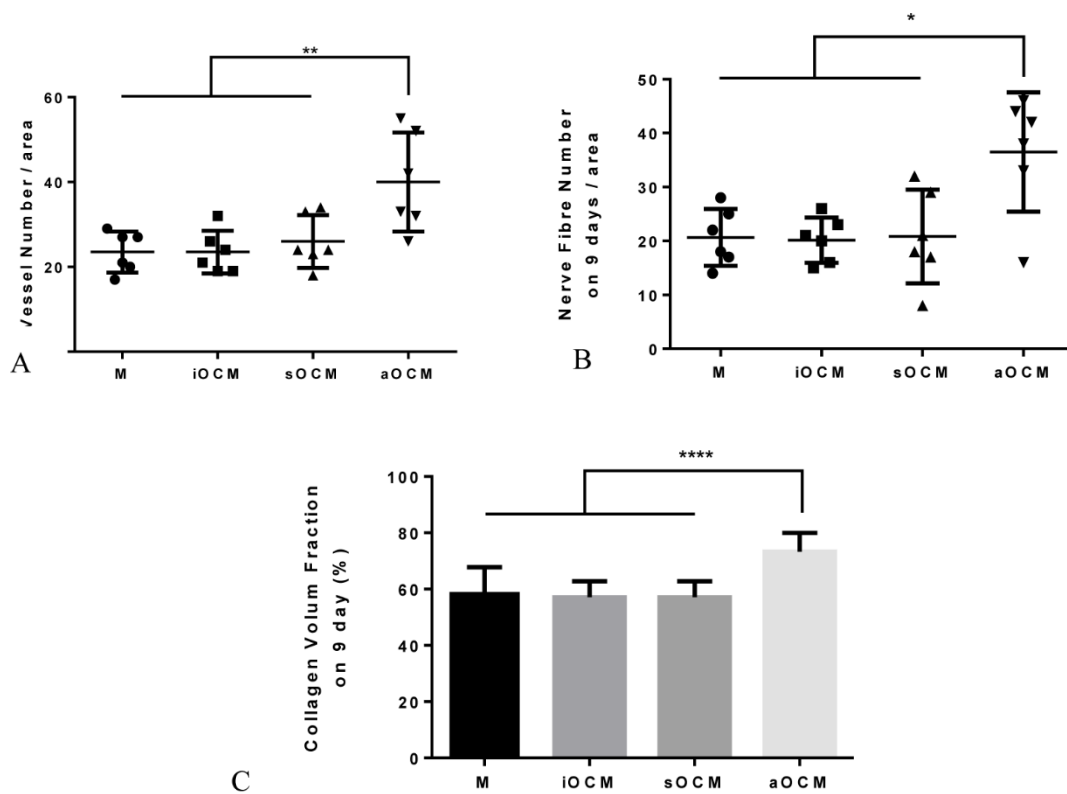


Figure 3. aOCM promoted angiogenesis, nerve regeneration and collagen density in diabetic mice model in early wound healing stage.

- A. Quantitative analysis of angiogenesis assessed by CD31 and α -SMA co-staining. ** $p < 0.01$.
- B. Quantitative analysis of peripheral nerve fiber stained by NF-L on day 9. * $p < 0.05$.
- C. Collagen volume fraction (CVF) against stained section of each group was calculated through collagen-stained area (blue) relative to total stained area on day 9 post-operation. **** $p < 0.0001$.