





Impact of endolymphatic hydrops on DPOAE in subjects with normal to mild hearing loss

Kei Inagaki MD¹ | Tadao Yoshida MD, PhD¹  | Masumi Kobayashi MD, PhD¹  |
Satofumi Sugimoto MD, PhD¹  | Yukari Fukunaga² | Daisuke Hara² |
Shinji Naganawa MD, PhD³ | Michihiko Sone MD, PhD¹ 

¹Department of Otorhinolaryngology, Nagoya University Graduate School of Medicine, Nagoya, Japan

²Department of Rehabilitation, Nagoya University Graduate School of Medicine, Nagoya, Japan

³Department of Radiology, Nagoya University Graduate School of Medicine, Nagoya, Japan

Correspondence

Tadao Yoshida, MD, PhD, Department of Otorhinolaryngology, Nagoya University Graduate School of Medicine, 65 Tsurumai-cho, Showa-ku, Nagoya 466-8550, Japan.
Email: tadaoy@med.nagoya-u.ac.jp

Abstract

Objective: The increased endolymph volume affects a shift in the organ of Corti and basilar membrane in ears with endolymphatic hydrops (EH), which might affect distortion-product otoacoustic emissions (DPOAE) by altering the operating point of the outer hair cells. We investigated how changes in DPOAE are related to the distribution site of EH.

Study Design: Prospective study.

Methods: Among 403 patients with hearing or vestibular symptoms who underwent contrast-enhanced magnetic resonance imaging (MRI) for the diagnosis of EH and subsequent DPOAE testing, subjects whose hearing levels on pure tone audiometry were ≤ 35 dB at all frequencies were included in this study. In patients with EH on MRI, the presence and amplitude of DPOAE were evaluated between groups with hearing levels of ≤ 25 dB at all frequencies versus hearing levels of > 25 dB at one or more frequencies.

Results: There were no differences in the distribution of EH between groups. The amplitude of DPOAE had no clear correlation with the presence of EH. However, in both groups, there was a significantly higher probability of the presence of a DPOAE response from 1001 to 6006 Hz in cases with EH in the cochlea.

Conclusion: Among patients whose hearing levels were ≤ 35 dB at all frequencies, better responses on DPOAE testing were found in subjects with EH in the cochlea. Alteration of DPOAEs in the early stages of hearing impairment could indicate morphological changes in the inner ear with altered basilar membrane compliance due to EH.

Level of Evidence: 4

KEYWORDS

distortion-product otoacoustic emissions, endolymphatic hydrops, magnetic resonance imaging, Meniere's disease

This is an open access article under the terms of the [Creative Commons Attribution-NonCommercial-NoDerivs](https://creativecommons.org/licenses/by-nc-nd/4.0/) License, which permits use and distribution in any medium, provided the original work is properly cited, the use is non-commercial and no modifications or adaptations are made.

© 2022 The Authors. *Laryngoscope Investigative Otolaryngology* published by Wiley Periodicals LLC on behalf of The Triological Society.

1 | INTRODUCTION

In normal ears, otoacoustic emissions (OAEs) occur spontaneously or in response to sound stimuli. Biological activity of outer hair cells (OHCs) help amplify and sharpen traveling waves in the cochlea, contributing to the high sensitivity, high definition, and wide dynamic range of the human cochlea.¹ The OHCs actively contract and relax in response to changes in membrane potential. This active movement amplifies basilar membrane oscillations by up to about 1000 times the amplitude in the absence of the organ of Corti.^{2,3} The distortion-product OAE (DPOAE) measures acoustic emissions when the cochlea is simultaneously stimulated with pure tones of two different frequencies. The resultant changes in hair cells modify basilar membrane vibrations, creating vibrations (with a frequency of $2f_1-f_2$) in the basilar membrane that have a different frequency from those of the incoming sounds (f_1 and f_2). Changing the frequencies makes it possible to measure acoustic emissions at multiple frequencies. In general, the site of origin of $2f_1-f_2$ DPOAE is at or near the cochlear tonotopic site of the f_2 primary.⁴⁻⁶

Endolymphatic hydrops (EH), a hallmark of Meniere's disease (MD), can now be visualized by magnetic resonance imaging (MRI),⁷ and a correlation between its size and electrophysiological signs has been reported.⁸⁻¹¹ However, MRI often identifies EH even in the asymptomatic ear, that is, the ear contralateral to the MD ear.¹² The presence of EH can cause changes in the morphology of the cochlea and the inner ear, resulting in auditory symptoms and electrophysiological changes that might alter the response of the DPOAE. It has been reported that the presence of EH alters the resting position of the organ of Corti due to increased endolymphatic volume and the associated displacement of the basilar membrane, leading to displacement of the operating point of OHCs.^{13,14} Some animal studies have created models of acute and chronic EH. Studies that generated acute EH and examined cochlear function revealed a decrease in DPOAE response and cochlear microphone potential with increased lymphatic fluid volume or pressure.^{15,16} As DPOAE and cochlear microphone potentials recover rapidly following pressure release, partial decompression of the scala media is assumed to be causal. Although, it is difficult to see acute EH formation in humans, we hypothesize that elevated inner ear pressure occurs in the early stages of EH and that DPOAE response may capture micro basal plate deflections. EH causes dysfunction of the cochlea, and since DPOAE measures the specific activity of the cochlea, it might provide insight into the pathogenesis of MD. Specifically, the involvement of OHCs in patients with EH might be detected using DPOAEs. Furthermore, evaluation of DPOAEs is expected to help identify which sites of the cochlea are affected by EH and which parts of the auditory pathway are abnormal. In this study, we investigated the impact of the early stage of EH on DPOAE responses.

2 | MATERIALS AND METHODS

2.1 | Subjects

Among 403 patients who visited our department with symptoms related to hearing or the vestibule from 2018 to 2021, 233 adults

(466 ears) who underwent 3-Tesla MRI examination and DPOAE testing to investigate the presence of EH were included in this study. All cases had symptoms (hearing loss, vertigo, floating sensation, ear fullness, and tinnitus), which suggested the presence of EH. The diagnosis of definite or probable MD was made according to the international consensus diagnostic criteria for MD.¹⁷ Laboratory technicians performed pure-tone audiometry using an AA-79 diagnostic audiometer (Rion Co. Ltd., Tokyo, Japan) in a soundproof chamber. Air-conduction audiometric measurement thresholds at octave intervals from 125 to 4000 Hz using 5 dB steps were used in the assessment. Subjects whose hearing levels on pure tone audiometry were ≤ 35 dB at all frequencies were included in the study, and were divided into two groups: those with hearing levels ≤ 25 dB at all frequencies (Group 1), and those with hearing levels > 25 to ≤ 35 dB at one or more frequencies (Group 2). Hearing levels < 25 dB was chosen as WHO's grade-matched normal hearing group without impairment, and hearing levels > 25 to ≤ 35 dB were chosen as the slight impairment group. In the Global Burden of Disease Expert Group study, all patients matched the normal to mild hearing category.¹⁸ Ears with apparent cochlear damage (i.e., those with a hearing level of > 35 dB at one or more frequencies) were excluded. We also included cases who had fluctuations in hearing level ≤ 35 dB for all frequencies and grouped patients according to their hearing level at the time of DPOAE testing. Informed consent has been obtained from all individuals included in this study.

2.2 | Magnetic resonance imaging

MRI evaluation of the ear was performed using a 3T scanner (Trio or Verio; Siemens, Erlangen, Germany or Vantage Centurian, Canon Medical Systems, Tochigi, Japan) 4 h after intravenous administration of a standard dose (0.2 ml/kg bodyweight; i.e., 0.1 mmol/kg body weight) of gadolinium hydrate (Omniscan; GE Healthcare, Little Chalfont, UK).^{19,20} The presence of EH was investigated using hybrid of reversed image of positive endolymph signal and native image of positive perilymph signal (HYDROPS), hybrid of reversed image of magnetic resonance cisternography and positive perilymph signal by heavily T2 weighted-3D-FLAIR, and 3-D real inversion recovery sequences.²¹ At least two radiologists with more than 20 years of experience who were blinded to the clinical symptoms classified the degree of EH in the cochlea and the vestibule into one of three groups: none, mild and significant, according to previously described criteria.²² Figure 1 shows sample images of the cases included in this study. In this study, patients with EH of mild or greater severity were defined as having EH.

2.3 | Distortion-product otoacoustic emissions

DPOAEs were obtained using an ILO 292-USB (ILO V6) system (Otodynamics, Herts, UK). All measurements were performed in a soundproof room. The acoustic stimuli consisted of paired tones

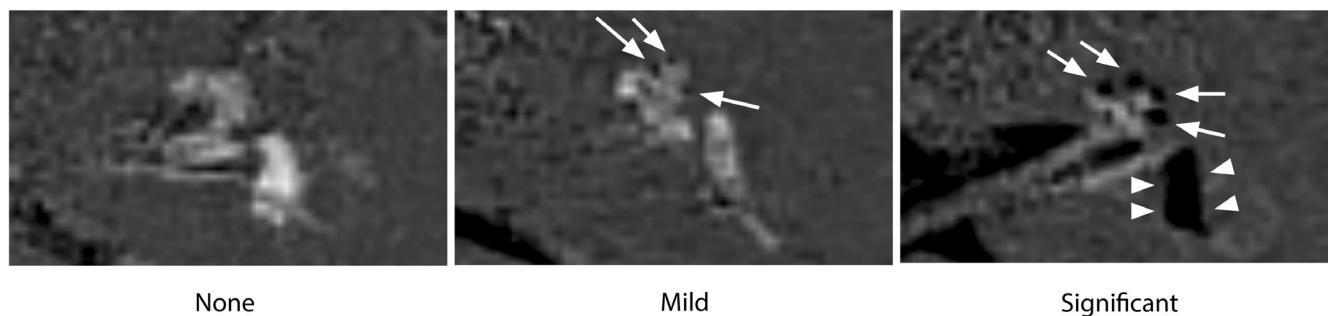


FIGURE 1 Sample images using hybrid of reversed image of positive endolymph signal and native image of positive perilymph signal (HYDROPS) images of the left ears included in this study. From left to right: no hydrops, mild hydrops, and significant hydrops. The arrows indicate endolymphatic hydrops in the cochlea; arrowheads indicate endolymphatic hydrops in the vestibule

TABLE 1 Characteristics of the patients

Variable	Group 1 (≤ 25 dB)			Group 2 (> 25 dB to ≤ 35 dB)			Total		
<i>n</i>	172			67			239		
Age (years)	42.7			47.0			43.9		
Sex (female:male)	66:64			26:31			92:95		
Pure tone average (dB)	10.1			19.7			12.7		
	None	Mild	Significant	None	Mild	Significant	None	Mild	Significant
EH in the cochlea (%)	63 (36.6)	72 (41.9)	37 (21.5)	30 (44.8)	19 (28.4)	18 (26.9)	93 (38.9)	91 (38.1)	55 (23.0)
EH in the vestibule (%)	133 (77.3)	26 (15.1)	13 (7.6)	53 (79.1)	10 (14.9)	4 (6.0)	186 (77.8)	36 (15.1)	17 (7.1)

Diagnosis	Group 1 (≤ 25 dB)	Group 2 (> 25 dB to ≤ 35 dB)	Total
Definite Meniere's disease	6	7	13
Probable Meniere's disease	9	5	14
Asymptomatic ear ^a	49	6	55
Fluctuating hearing loss	2	3	5
Delayed endolymphatic hydrops	8	3	11
Sudden sensorineural hearing loss	6	3	9
Vertigo ^b	41	8	49
Other	51	32	83
Total	172 ears	67 ears	239 ears

TABLE 2 Diagnoses of ears

^aAsymptomatic ears contralateral to all symptomatic ears.

^bThe "Vertigo" includes possible MD based on the American Academy of Otolaryngology-Head and Neck Surgery criteria²³ and other vertigo not classified elsewhere.

delivered simultaneously through the probe. The tones had an intensity of 70 dB sound pressure level (SPL) and an automatically determined ratio between frequencies of f_1 and f_2 (1.22). Six pairs of stimuli were used, corresponding to the following frequency values for f_2 : 1001, 1501, 2002, 3003, 4004, and 6006 Hz. Noise estimates were based on two standard deviations above the mean noise floor. The acceptance criteria used were a level of -20 dB SPL or greater for the DPOAE amplitude, and a difference between the DPOAE and noise floor of 3 dB or greater at 1001 Hz and 6 dB or greater at other frequencies. The presence and amplitude of DPOAEs at the six f_2 test frequencies were used for statistical analysis.

2.4 | Ethics review

The study was approved by the Ethics Review Committee of Nagoya University School of Medicine, Nagoya, Japan (No. 2022-0094).

2.5 | Statistical analyses

IBM SPSS Statistics software (version 28, IBM Corp., Armonk, NY) was used for statistical analyses. The *t*-test and Fisher's exact test were used for comparisons. The significance level was set at 5%.

3 | RESULTS

Table 1 shows the characteristics of the patients. Group 1 included 130 cases (172 ears), and Group 2 included 57 cases (67 ears). The average hearing in both ears was 10.1 dB in Group 1 and 19.7 dB in Group 2. Mean patient age was 42.7 years in Group 1 and 47.0 years in Group 2. There were no sex differences between the groups; Group 1 included 66 females (91 ears) and 64 males (81 ears), respectively,

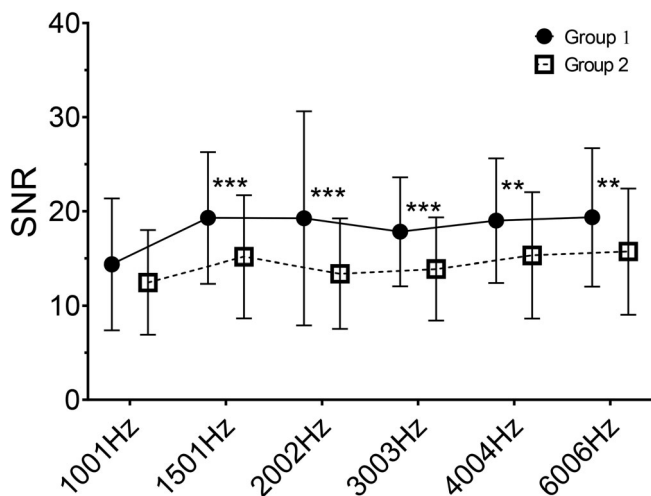


FIGURE 2 SNR of DPOAE by frequency. Comparison of SNR for each frequency between Groups 1 and 2. Group 1 was the group with hearing levels ≤ 25 dB at all frequencies, and Group 2 was the group with hearing levels > 25 to ≤ 35 dB at one or more frequencies. Symbols and thin bars indicate mean and ± 1 standard deviation values, respectively. **Statistical significance (defined as $p < .01$), ***statistical significance (defined as $p < .001$). DPOAE, distortion-product otoacoustic emissions; SNR, signal-to-noise ratio

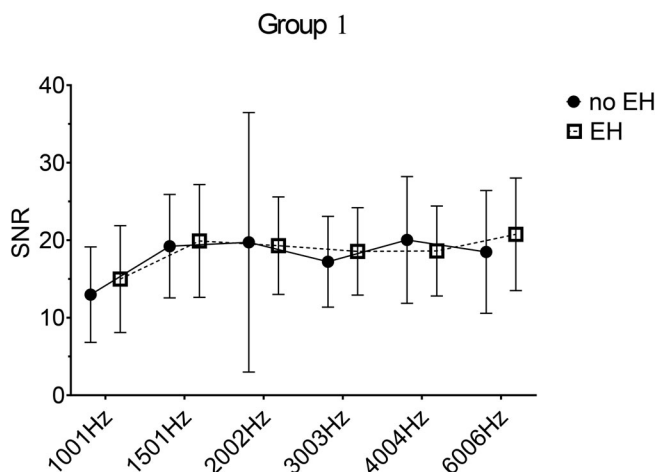


FIGURE 3 SNR of DPOAE by frequency. Comparison of SNR for each frequency with and without endolymphatic hydrops in Group 1. (Hearing levels ≤ 25 dB at all frequencies.) DPOAE, distortion-product otoacoustic emissions; SNR, signal-to-noise ratio

while Group 2 included 26 females (34 ears) and 31 males (33 ears), respectively.

In Group 1, EH was present in the cochlea in 109/172 (63.4%) ears, and significant EH was present in 37/172 (21.5%) ears. EH was present in the vestibule in 39/172 (22.7%) ears, and significant EH was present in 13/172 (7.6%) ears. In Group 2, EH was present in the cochlea in 37/67 (55.2%) ears, and significant EH was present in 18/67 (26.9%) ears. EH was present in the vestibule in 14/67 (21.0%) ears, and significant EH was present in 4/67 (6.0%) ears. Table 2 lists the diagnoses of auditory and vestibular symptoms in each ear of the patients in this study. The contralateral asymptomatic ear was the most common, followed by cases of vertigo. The “Vertigo” includes possible MD based on the American Academy of Otolaryngology-Head and Neck Surgery criteria²³ and other vertigo not classified elsewhere. Figure 2 shows the signal-to-noise ratio (SNR) of DPOAE by frequency. In the overall comparison, Group 1 showed a better SNR than Group 2, with significant differences at frequencies from 1501 to 6006 Hz. When comparing cases with and without EH in the cochlea, there were no differences in SNR in group 1 (Figure 3), although there was a trend toward greater SNR in Group 2 cases with EH (Figure 4). Table 3 shows the presence or absence of EH in the cochlea and vestibule, the presence or absence of DPOAE waveforms at each frequency where the SNR met acceptable criteria, and the average amplitude of the DPOAEs. In Group 1, DPOAE waveforms were significantly observed at the f2 frequency of 4004 Hz in patients with EH in the cochlea ($p < .01$). On the other hand, in Group 2, DPOAE waveforms were significantly observed at 1501 Hz in patients with EH in the cochlea ($p < .05$). There was no association between the presence of DPOAE and EH in the vestibule, nor between the amplitude of DPOAE and EH in the cochlea and vestibule. Overall, the amplitudes of DPOAEs in Group 2 tended to be smaller than those in Group 1.

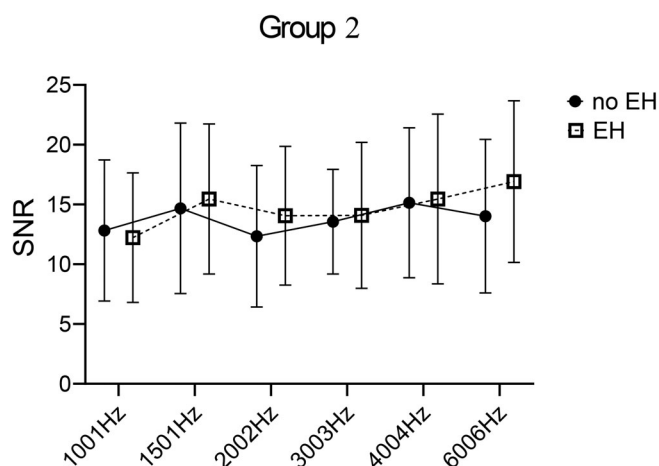


FIGURE 4 SNR of DPOAE by frequency. Comparison of SNR for each frequency with and without endolymphatic hydrops in Group 2. (Hearing levels > 25 to ≤ 35 dB at one or more frequencies.) DPOAE, distortion-product otoacoustic emissions; SNR, signal-to-noise ratio

TABLE 3 Comparison between the presence of endolymphatic hydrops and the presence and amplitude of distortion-product otoacoustic emission

Variable	Group 1 (≤ 25 dB)				Group 2 (> 25 dB to ≤ 35 dB)				Total			
	EH in the cochlea		EH in the vestibule		EH in the cochlea		EH in the vestibule		EH in the cochlea		EH in the vestibule	
	Yes (n = 109)	No (n = 63)	Yes (n = 39)	No (n = 39)	Yes (n = 37)	No (n = 30)	Yes (n = 14)	No (n = 53)	Yes (n = 146)	No (n = 93)	Yes (n = 53)	No (n = 186)
DPOAE present: 1001 Hz (%)	86.2	88.9	89.7	86.5	64.9	50.0	64.3	56.6	80.1	76.3	81.1	78.0
Mean amplitude: 1001 Hz (dB)	7.8	6.8	7.0	7.6	4.1	4.7	4.8	4.2	7.1	6.4	6.6	6.9
DPOAE present: 1501 Hz (%)	92.7	85.7	89.7	90.2	78.4 ^a	53.3	78.6	64.2	89.0 ^b	75.3	86.8	82.8
Mean amplitude: 1501 Hz (dB)	10.7	11.1	10.8	10.8	6.2	5.0	7.2	5.3	9.7	9.7	9.9	9.6
DPOAE present: 2002 Hz (%)	84.4	87.3	76.9	88.0	83.8	66.7	71.4	77.4	84.2	80.6	75.5	84.9
Mean amplitude: 2002 Hz (dB)	8.1	9.4	9.2	8.4	2.3	0.8	3.5	1.2	6.6	7.1	7.8	6.6
DPOAE present: 3003 Hz (%)	89.9	85.7	84.6	89.5	86.5	66.7	85.7	75.5	89.0 ^a	79.6	84.9	85.5
Mean amplitude: 3003 Hz (dB)	4.5	3.8	5.0	4.1	0.3	-0.9	-0.5	-0.1	3.5	2.5	3.5	3.0
DPOAE present: 4004 Hz (%)	94.5 ^b	81.0	94.9	88.0	73.0	63.3	78.6	66.0	89.0 ^b	75.3	90.6	81.7
Mean amplitude: 4004 Hz (dB)	5.7	7.3	6.3	6.2	2.0	1.0	-0.6	2.3	5.0	5.6	4.7	5.3
DPOAE present: 6006 Hz (%)	88.1	84.1	89.7	85.7	62.2	53.3	57.1	58.5	81.5	74.2	81.1	78.0
Mean amplitude: 6006 Hz (dB)	7.9	7.2	9.0	7.2	5.4	1.9	5.5	3.6	7.4	5.9	8.4	6.4

Note: Frequencies given for the DPOAEs are the f2 generating frequency.

Abbreviation: DPOAE, distortion-product otoacoustic emission.

^aStatistical significance (defined as $p < .05$).

^bStatistical significance (defined as $p < .01$).

4 | DISCUSSION

MD consists of a triad of hearing loss, vertigo, and tinnitus, and is thought to be caused by EH in the inner ear. MRI in these cases shows EH in the cochlea and vestibule, and a very high rate of EH has been reported in definite MD.^{12,24} On the other hand, EH has also been reported to be present in atypical cases of MD and in subjects with other causes of vestibulocochlear symptoms, although less frequently than in MD.¹² EH is present to a greater extent in the unaffected ears of patients with MD compared to controls.^{24,25} EH in the unaffected ear might support the epidemiologic observation that MD shows bilateral involvement in about 9.2%–16.2% of cases,²⁶ suggesting that EH in the unaffected ear might be an early lesion or a precursor lesion of MD. The present study included cases with vestibulocochlear symptoms, but only mild cochlear damage, which might represent the early or preliminary stage of MD. In DPOAE testing, high frequency sounds of above 1 kHz are used for testing due to high biological noise in the low-frequency range. In addition, the response disappears when there is an increase in the hearing threshold to 35–40 dB or more in cases with bone-conduction hearing. DPOAE responses could thus be obtained in early MD and EH-related diseases due to reversible hearing loss in the frequency range below 1 kHz and preservation of hearing at high frequencies.²⁷ The DPOAE is a test capable of sensitively capturing OHCs activity. In the present study, no significant attenuation or loss of DPOAE response was found in patients with EH with normal hearing or mild hearing loss. In contrast, there were frequency ranges where the EH ear showed improved SNR and also significant DPOAE responses. In the EH ear, excessive fluid in the scala media can press on the basilar membrane thereby stiffening it and causing an altered frequency-position map of the cochlea and the operating point of OHC transfer function.^{13,14,28–31} In the apical turn of the cochlea, where compliance of the basilar membrane is highest, source deflection might occur, resulting in a phase change in DPOAEs.³² It has previously been reported that unstable operating points likely affect the phase rather than the amplitude of DPOAEs. There was no obvious impairment of OHCs with an increase in hearing threshold in the early EH ears included in this study, suggesting that the change in DPOAE response was due to morphological changes caused by endolymph accumulation affecting the oscillatory nature of the basilar membrane. High pressure differences between endolymph and perilymph are known to affect the resonant properties of the basilar membrane. In guinea pigs, early stage chronic hydrops occur with minimal pressure change (<67 Pa) between endolymph and perilymph.³³ This phase is mainly due to the high flexibility of the endolymphatic boundary, which allows the endolymph volume to grow without a high pressure increase.^{16,34} In contrast, the finite element method analysis revealed that EH may result in increased or decreased basilar membrane displacement at some frequency even at low pressure. Several clinical studies in humans have reported alterations in DPOAE response in EH ears. In a study using changes in DPOAE to evaluate glycerol test results in patients with ear fullness without other associated symptoms, a high percentage (58%) showed improvement. This group of patients could potentially

have been in the early stages of MD, with DPOAE confirming changes not detected by pure tone audiometry.³⁵ DPOAE responses were present in more than 60% of the ears with MD, even though the average hearing threshold was greater than 40 dB.³⁶ Unexpected DPOAEs were also observed in some patients when the corresponding pure-tone threshold was 50 dB. These findings might represent localized information about the basilar membrane displacement of certain areas of the cochlea.¹

Currently, a simple screening method for asymptomatic EH is being explored to diagnose the prodromal state of MD. Electrocochleography and vestibular evoked myogenic potentials are commonly used tests for EH estimation. The combination of summing potential amplitude and summing potential bias ratio at 1 kHz reportedly has an overall diagnostic accuracy of 85% for MD.³⁷ Even in patients with only ear fullness symptoms and no MD, EH can be estimated using the area ratio parameter of electrocochleography.³⁸ Additionally, vestibular-evoked myogenic potentials measured using tuning criteria of specific frequencies showed a similar response to MD in 27% of healthy side, asymptomatic ears with MD.³⁹ Thus, evaluation of DPOAE in MD patients could provide useful information regarding cochlear function, such as changes in basilar membrane compliance due to EH.

5 | CONCLUSION

We confirmed that DPOAEs are relatively well preserved in patients with cochlear EH, whose hearing levels were ≤ 35 dB at all frequencies. The characteristics of DPOAE responses in the early stages of hearing disturbance might indicate morphological changes in the inner ear with altered basilar membrane compliance due to EH.

CONFLICT OF INTEREST

The authors have no sources of funding, financial relationships, or conflicts of interest to disclose.

ORCID

Tadao Yoshida  <https://orcid.org/0000-0001-9993-0766>

Masumi Kobayashi  <https://orcid.org/0000-0002-4285-1466>

Satofumi Sugimoto  <https://orcid.org/0000-0001-8890-8627>

Michihiko Sone  <https://orcid.org/0000-0001-7380-610X>

REFERENCES

1. Fetterman BL. Distortion-product otoacoustic emissions and cochlear microphonics: relationships in patients with and without endolymphatic hydrops. *Laryngoscope*. 2001;111(6):946-954.
2. Howard J, Hudspeth AJ. Compliance of the hair bundle associated with gating of mechano-electrical transduction channels in the bullfrog's saccular hair cell. *Neuron*. 1988;1(3):189-199.
3. Cheung ELM, Corey DP. Ca²⁺ changes the force sensitivity of the hair-cell transduction channel. *Biophys J*. 2006;90(1):124-139.
4. Moulin A. Influence of primary frequencies ratio on distortion product otoacoustic emissions amplitude. I. Intersubject variability and consequences on the DPOAE-gram. *J Acoust Soc Am*. 2000;107(3):1460-1470.

5. Moulin A. Influence of primary frequencies ratio on distortion product otoacoustic emissions amplitude. II. Interrelations between multicomponent DPOAEs, tone-burst-evoked OAEs, and spontaneous OAEs. *J Acoust Soc Am*. 2000;107(3):1471-1486.
6. Tubis A, Talmadge CL, Tong C. Modeling the temporal behavior of distortion product otoacoustic emissions. *J Acoust Soc Am*. 2000;107(4):2112-2127.
7. Nakashima T, Naganawa S, Sugiura M, et al. Visualization of endolymphatic hydrops in patients with Meniere's disease. *Laryngoscope*. 2007;117(3):415-420.
8. Gürkov R, Flatz W, Louza J, Strupp M, Ertl-Wagner B, Krause E. In vivo visualized endolymphatic hydrops and inner ear functions in patients with electrocochleographically confirmed Ménière's disease. *Otol Neurotol*. 2012;33(6):1040-1045.
9. Katayama N, Yamamoto M, Teranishi M, et al. Relationship between endolymphatic hydrops and vestibular-evoked myogenic potential. *Acta Otolaryngol*. 2010;130(8):917-923.
10. Kato M, Teranishi M, Katayama N, Sone M, Naganawa S, Nakashima T. Association between endolymphatic hydrops as revealed by magnetic resonance imaging and caloric response. *Otol Neurotol*. 2011;32(9):1480-1485.
11. Yamamoto M, Teranishi M, Naganawa S, et al. Relationship between the degree of endolymphatic hydrops and electrocochleography. *Audiol Neurootol*. 2010;15(4):254-260.
12. Pyykkö I, Nakashima T, Yoshida T, Zou J, Naganawa S. Meniere's disease: a reappraisal supported by a variable latency of symptoms and the MRI visualisation of endolymphatic hydrops. *BMJ Open*. 2013;3(2):e001555.
13. Brown DJ, Chihara Y, Curthoys IS, Wang Y, Bos M. Changes in cochlear function during acute endolymphatic hydrops development in Guinea pigs. *Hear Res*. 2013;296:96-106.
14. Brown DJ, Gibson WPR. On the differential diagnosis of Ménière's disease using low-frequency acoustic biasing of the 2f1-f2 DPOAE. *Hear Res*. 2011;282(1-2):119-127.
15. Mom T, Pavier Y, Giraudet F, Gilain L, Avan P. Measurement of endolymphatic pressure. *Eur Ann Otorhinolaryngol Head Neck Dis*. 2015;132:81-84.
16. Salt AN, Brown DJ, Hartsock JJ, Plontke SK. Displacements of the organ of Corti by gel injections into the cochlear apex. *Hear Res*. 2009;250:63-75.
17. Lopez-Escamez JA, Carey J, Chung W-H, et al. Diagnostic criteria for Meniere's disease. *J Vestib Res*. 2015;25:1-7.
18. Olusanya BO, Davis AC, Hoffman HJ. Hearing loss grades and the international classification of functioning, disability and health. *Bull World Health Organ*. 2019;97:725-728.
19. Naganawa S, Yamazaki M, Kawai H, Bokura K, Sone M, Nakashima T. Visualization of endolymphatic hydrops in Ménière's disease with single-dose intravenous gadolinium-based contrast media using heavily T(2)-weighted 3D-FLAIR. *Magn Reson Med Sci*. 2010;9(4):237-242.
20. Naganawa S, Nakamichi R, Ichikawa K, et al. MR imaging of endolymphatic hydrops: utility of iHYDROPS-Mi2 combined with deep learning reconstruction denoising. *Magn Reson Med Sci*. 2020;20(3):272-279.
21. Naganawa S, Yamazaki M, Kawai H, et al. MR imaging of Ménière's disease after combined intratympanic and intravenous injection of gadolinium using HYDROPS2. *Magn Reson Med Sci*. 2014;13(2):133-137.
22. Nakashima T, Naganawa S, Pyykkö I, et al. Grading of endolymphatic hydrops using magnetic resonance imaging. *Acta Otolaryngol Suppl*. 2009;560:5-8.
23. Committee on hearing and equilibrium guidelines for the diagnosis and evaluation of therapy in Meniere's disease. *Otolaryngol Head Neck Surg*. 1995;113:181-185.
24. Yoshida T, Sugimoto S, Teranishi M, et al. Imaging of the endolymphatic space in patients with Ménière's disease. *Auris Nasus Larynx*. 2018;45(1):33-38.
25. Okazaki Y, Yoshida T, Sugimoto S, et al. Significance of endolymphatic hydrops in ears with unilateral sensorineural hearing loss. *Otol Neurotol*. 2017;38(8):1076-1080.
26. Shojaku H, Watanabe Y, Yagi T, et al. Changes in the characteristics of definite Meniere's disease over time in Japan: a long-term survey by the Peripheral Vestibular Disorder Research Committee of Japan, formerly the Meniere's Disease Research Committee of Japan. *Acta Otolaryngol*. 2009;129(2):155-160.
27. Moulin A, Bera JC, Collet L. Distortion product otoacoustic emissions and sensorineural hearing loss. *Audiology*. 1994;33(6):305-326.
28. Tonndorf J. Endolymphatic hydrops: mechanical causes of hearing loss. *Arch Otorhinolaryngol*. 1976;212:293-299.
29. Gluth MB. On the relationship between Ménière's disease and endolymphatic hydrops. *Otol Neurotol*. 2020;41:242-249.
30. Guinan JJ Jr, Lefler SM, Buchman CA, Goodman SS, Lichtenhan JT. Altered mapping of sound frequency to cochlear place in ears with endolymphatic hydrops provide insight into the pitch anomaly of diplacusis. *Sci Rep*. 2021;11:10380.
31. Drexel M, Krause E, Gürkov R. A comparison of distortion product otoacoustic emission properties in Ménière's disease patients and normal-hearing participants. *Ear Hear*. 2018;39(1):42-47.
32. Avan P, Giraudet F, Chauveau B, Gilain L, Mom T. Unstable distortion-product otoacoustic emission phase in Ménière's disease. *Hear Res*. 2011;277(1-2):88-95.
33. Böhmer A. Hydrostatic pressure in the inner ear fluid compartments and its effects on inner ear function. *Acta Otolaryngol Suppl*. 1993;507:3-24.
34. Long CH 3rd, Morizono T. Hydrostatic pressure measurements of endolymph and perilymph in a Guinea pig model of endolymphatic hydrops. *Otolaryngol Head Neck Surg*. 1987;96:83-95.
35. Magliulo G, Cianfrone G, Triches L, Altissimi G, D'Amico R. Distortion-product otoacoustic emissions and glycerol testing in endolymphatic hydrops. *Laryngoscope*. 2001;111(1):102-109.
36. Cianfrone G, Ralli G, Fabbricatore M, Altissimi G, Nola G. Distortion product otoacoustic emissions in Ménière's disease. *Scand Audiol*. 2000;29(2):111-119.
37. Isele C, Gibson W. A comparison of three methods of using transtympanic electrocochleography for the diagnosis of Meniere's disease: click summing potential measurements, tone burst summing potential amplitude measurements, and biasing of the summing potential using a low frequency tone. *Acta Otolaryngol*. 2010;130(1):95-101.
38. Maheu M, Alhabib SF, Landry SP, Nader ME, Champoux F, Saliba I. Ear fullness as a symptom of endolymphatic hydrops in non-Ménière's patient. *J Int Adv Otol*. 2017;13(3):379-384.
39. Lin MY, Timmer FC, Oriel BS, et al. Vestibular evoked myogenic potentials (VEMP) can detect asymptomatic saccular hydrops. *Laryngoscope*. 2006;116(6):987-992.

How to cite this article: Inagaki K, Yoshida T, Kobayashi M, et al. Impact of endolymphatic hydrops on DPOAE in subjects with normal to mild hearing loss. *Laryngoscope Investigative Otolaryngology*. 2023;8(1):262-268. doi:10.1002/lio2.998