

CASE REPORT

Nagoya J. Med. Sci. 77. 525 ~ 530, 2015

Utility of a 3-dimensional full-scale NaCl model for rib strut grafting for anterior fusion for cervicothoracic kyphosis

Kazuyoshi Kobayashi¹, Shiro Imagama¹, Akio Muramoto², Zenya Ito¹, Kei Ando¹,
Hideki Yagi¹, Tetsuro Hida¹, Kenyu Ito¹, Yoshimoto Ishikawa¹, Mikito Tsushima¹
and Naoki Ishiguro¹

¹Department of Orthopaedic Surgery, Nagoya University Graduate School of Medicine, Nagoya, Japan

²Department of Orthopaedic Surgery, Kariya Toyota General Hospital, Kariya, Japan

ABSTRACT

In severe spinal deformity, pain and neurological disorder may be caused by spinal cord compression. Surgery for spinal reconstruction is desirable, but may be difficult in a case with severe deformity. Here, we show the utility of a 3D NaCl (salt) model in preoperative planning of anterior reconstruction using a rib strut in a 49-year-old male patient with cervicothoracic degenerative spondylosis. We performed surgery in two stages: a posterior approach with decompression and posterior instrumentation with a pedicle screw; followed by a second operation using an anterior approach, for which we created a 3D NaCl model including the cervicothoracic lesion, spinal deformity, and ribs for anterior reconstruction. The 3D NaCl model was easily scraped compared with a conventional plaster model and was useful for planning of resection and identification of a suitable rib for grafting in a preoperative simulation. Surgery was performed successfully with reference to the 3D NaCl model. We conclude that preoperative simulation with a 3D NaCl model contributes to performance of anterior reconstruction using a rib strut in a case of cervicothoracic deformity.

Key Words: cervicothoracic degenerative spondylosis, rib strut, full-scale 3-dimensional NaCl model, surgical planning

INTRODUCTION

Three-dimensional (3D) full-scale models can reproduce complicated osseous anatomy accurately and are used in preoperative planning as surgical support tools.¹⁻³⁾ In this report, we describe the surgical treatment of a case of cervicothoracic degenerative spondylosis. We created a 3D full-scale NaCl (salt) model based on computed tomography (CT) data and performed a simulation of corrective surgery for spinal anterior reconstruction with rib grafting. There has been no previous report of use of a 3D NaCl model for spinal anterior reconstruction with a rib. Compared with a conventional plaster model, the 3D NaCl model had good strength, a quality resembling real bone,⁴⁾ and could be easily scraped, which was particularly useful in performing bone resection in a preoperative simulation. We show that this 3D NaCl model was of particular utility in allowing the planned procedures to be accomplished accurately and safely.

Received: April 21, 2015; accepted: June 15, 2015

Corresponding author: Shiro Imagama, MD

Department of Orthopaedic Surgery, Nagoya University Graduate School of Medicine, 65, Tsurumai-cho, Showa-ku, Nagoya, 466-8560, Japan

Tel: +81-52-741-2111, Fax: +81-52-744-2260, Email address: imagama@med.nagoya-u.ac.jp

CASE REPORT

A 49-year-old male had suffered from occasional neck pain with no neurological symptoms for several years ago. However, spinal deformity at the cervicothoracic level gradually progressed, and led to continuous neck pain, muscle weakness in the upper and lower extremities, and gait disturbance associated with myelopathy. CT indicated marked degenerative deformity of C5-Th3 (Fig. 1). Therefore, we decided to perform the surgery.

Surgery was planned in two stages. First, a posterior approach was performed with decompression, C2-Th6 posterior instrumentation with a screw, and use of a halo vest pre-, and postoperatively (Fig. 2A). After the first operation, we planned a second surgery using 3D models. The strategy was curettage of the C5-Th3 vertebra, followed by anterior strut reconstruction using a rib. For preoperative simulation, we created a 3D NaCl model (Sony EMCS Corp., Aichi, Japan) based on CT images with informed consent.

The model was created from a CT scan of the cervicothoracic area and ribs using digital imaging. In the completed 3D NaCl spinal model, hyperkyphosis at the cervicothoracic level and anterior vertebrae with the posterior screw was completely reproduced (Fig. 2A). The ribs were also reproduced in the model to allow selection for grafting (Fig. 2B). In simulation surgery, the total length of the anterior C5-Th3 lesion was 11 cm, including the curvature (Fig. 3A). The anterior vertebral body of the 3D NaCl model was easily used for curettage and drilling (Fig. 3B). An examination of the rib that best corresponded to the spinal curvature led to selection of the posterior lateral left side 8th rib (size 11 cm) as the rib with the most appropriate curvature that was suitable for grafting (Fig. 3C).

During the actual surgery, an anterior approach provided exposure from C4 to Th4. All planned procedures were performed successfully, including C5-Th3 vertebra resection for spinal reconstruction. The harvested 8th rib was cut at 11 cm and assembled for reconstruction for stabilization using grafting in the same manner as that in the simulated 3D model. We performed rib resection and scraping using the simulated ribs as a reference.

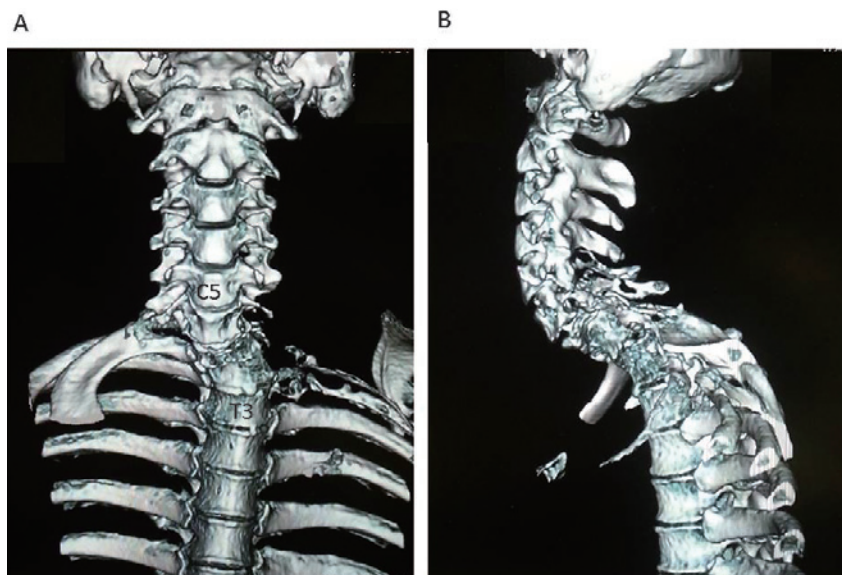


Fig. 1 Sagittal view in 3D-CT, showing deformity due to a cervicothoracic lesion.

After surgery, neurologic function and neck pain were markedly improved. In another 3D model created using postoperative CT images, the grafted rib and cervicothoracic alignment were successfully reproduced (Fig. 4A,B).

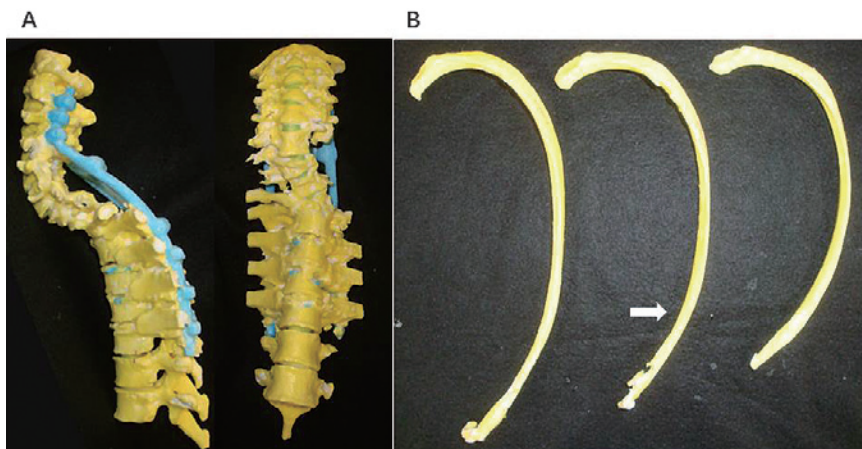


Fig. 2 (A) A 3D model based on postoperative CT after posterior fixation reproduced the cervicothoracic deformity. The posterior implant is colored in blue.
(B) A rib 3D model (7th–9th ribs). The arrow indicates the 8th rib.

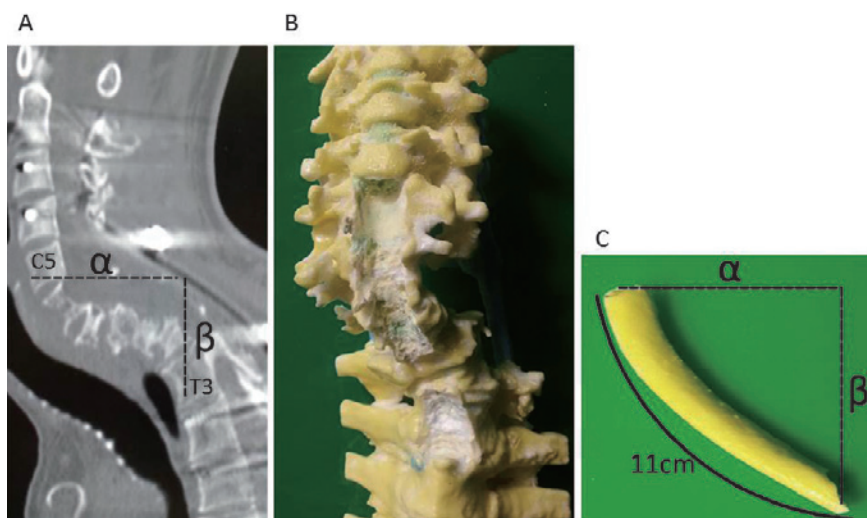


Fig. 3 (A) In simulation, sagittal view on CT with the measured C5-Th3 lesion: α is 9cm, β is 8 cm.
(B) In simulation, the anterior vertebral body of the 3D NaCl model was easily used for curettage and drilling for the bone graft.
(C) In simulation, the total length of the anterior C5-Th3 lesion was 11 cm, including the curve with the 8th left rib: α is 9cm, β is 8 cm.

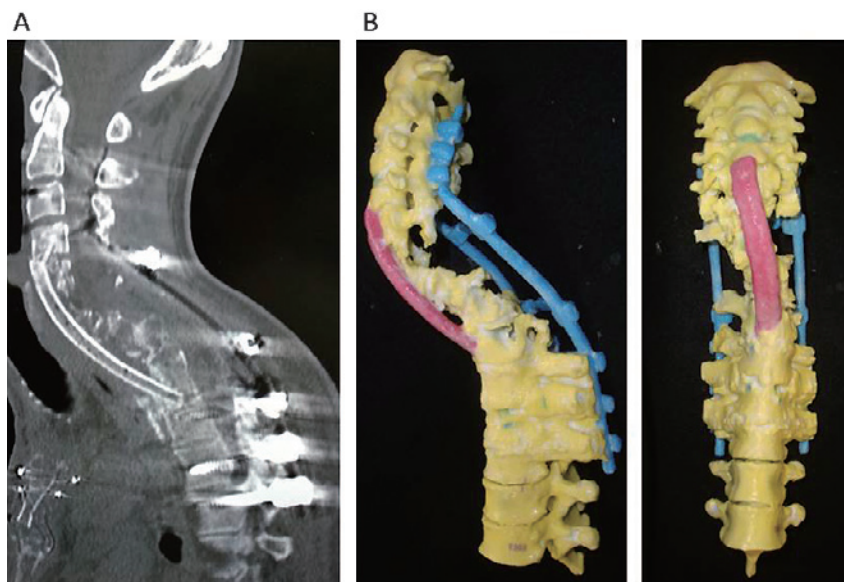


Fig. 4 (A) Sagittal view on CT after anterior reconstruction using a rib strut.
 (B) A 3D model based on postoperative CT after anterior reconstruction, with the rib strut shown in red. This model was also useful for obtaining postoperative informed consent and allowing the patient to understand his surgeries.

DISCUSSION

Several advantages of 3D spinal models have been described.^{1,5-7)} Toyoda *et al.* found that a 3D model allowed visualization of the vertebral artery in a patient with atlantoaxial subluxation.⁷⁾ Yamazaki *et al.* reported reduction of the displaced facet with the pedicle screw-rod system in a patient with old cervical fracture-dislocation.⁶⁾ Mizutani *et al.* showed that 3D models allowed preoperative planning as a template, particularly for determining entire plate-rod contours for occipitocervical junctions in 15 rheumatoid cervical spine surgeries.¹⁾ The advantage of full-scale 3D models lies in the ability to confirm the surgical procedure and anatomy. In the current report, the 3D model accurately represented the actual bone, and the novel use of a 3D model facilitated alignment of a cervicothoracic lesion and selection of ribs with appropriate curvature for reconstruction. The cortex of the rib is composed of curved segments for which the degrees of curvature differ among individuals, and preoperative knowledge of the features of each rib could lead to more accurate grafting during surgery.

Compared with other published 3D models made of plaster, the 3D NaCl model has several advantages: coloring of the model interior; strength and quality resembling real bone; relatively low cost of the main material (salt); and environmental friendliness because of the high solubility of salt in water.^{3,4)} Plaster 3D models are occasionally damaged due to the weakness of the material.⁸⁾ In contrast, the 3D NaCl model is prepared using a strong material that does not shatter or crack during simulated surgery. The model can also be easily scraped, which was particularly useful in performing bone resection in the preoperative simulation. Hardness was obtained by using impregnation material, and the cortical bone and cancellous bone were generally reproduced. Thus, the cutting sensation using the NaCl model is similar to that with bone and the model can be handled like bone. In addition, because of the rigidity, the model does not break, even

in preoperative cutting. In the preoperative simulation, the ribs were easily scraped and it was possible to define the ideal cervical alignment shape. This model has a disadvantage in that it becomes soft in high-humidity environments because of its high water solubility.⁹⁾ However, despite this problem, the 3D NaCl model is ideal for use in simulation surgery.

In anterior spinal reconstruction, in 1960 Hodgson *et al.* reported treatment of 100 cases of kyphotic thoracic deformities due to tuberculosis using the patient's own rib or an iliac bone graft.¹⁰⁾ Materials used for anterior struts can mainly be classified into bone auto grafting using a rib, fibula, or iliac bone,¹¹⁻¹⁴⁾ and use of an artificial strut made of methylmethacrylate, rods, bone cement, or a cage.¹⁵⁻¹⁸⁾ Since anterior spinal deformity tends to have progressive changes, in our case we used the patient's own rib, rather than artificial struts. Additionally, the grafted rib was shaped like the deformity of the anterior strut, and exactly matched the simulated shape. However, there has been no previous report of use of a 3D model including the ribs for planning of anterior reconstruction. We found that this 3D model method is reliable for preoperative simulation, and the findings of this study should allow reconstructive surgeries to improve techniques and perspectives to achieve better reconstruction outcomes. We conclude that preoperative simulation with a 3D NaCl model contributes to performance of anterior reconstruction using a rib strut in a case of cervicothoracic deformity.

Conflict of Interest: None of the authors have a conflict of interest regarding the contents of the manuscript.

REFERENCES

- 1) Mizutani J, Matsubara T, Fukuoka M, Tanaka N, Iguchi H, Furuya A, Okamoto H, Wada I, Otsuka T. Application of full-scale three-dimensional models in patients with rheumatoid cervical spine. *Eur Spine J*, 2008; 17: 644-649.
- 2) van Dijk M, Smit TH, Jiya TU, Wuisman PI. Polyurethane real-size models used in planning complex spinal surgery. *Spine*, 2001; 26: 1920-1926.
- 3) D'Urso PS, Askin G, Earwaker JS, Merry GS, Thompson RG, Barker TM, Effeney DJ. Spinal biomodeling. *Spine*, 1999; 24: 1247-1251.
- 4) Abe Y, Hashimoto I, Matsuo S, Goishi K, Kashiwagi K, Nagai H, Miyamoto Y, Nakanishi H. Three-dimensional sodium chloride (NaCl) model for simulated mandibular reconstruction surgery: a new environmentally friendly material. *J Med Invest*, 2014; 61: 318-324.
- 5) Sugimoto Y, Tanaka M, Nakahara R, Misawa H, Kunisada T, Ozaki T. Surgical treatment for congenital kyphosis correction using both spinal navigation and a 3-dimensional model. *Acta Med Okayama*, 2012; 66: 499-502.
- 6) Yamazaki M, Okawa A, Akazawa T, Koda M. Usefulness of 3-dimensional full-scale modeling for preoperative simulation of surgery in a patient with old unilateral cervical fracture-dislocation. *Spine*, 2007; 32: E532-326.
- 7) Toyoda K, Urasaki E, Yamakawa Y. Novel approach for the efficient use of a full-scale, 3-dimensional model for cervical posterior fixation: a technical case report. *Spine*, 2013; 38: E1357-1360.
- 8) Strackee SD, Kroon FHM, Spierings PTJ, Jaspers JE. Development of a modeling and osteotomy jig system for reconstruction of the mandible with a free vascularized fibula flap. *Plast Reconstr Surg*, 2004; 114: 1851-1858.
- 9) Sakamoto Y, Ogata H, Nakajima H, Kishi K, Sakamoto T, Ishii T. Role of solid model simulation surgery for hemifacial microsomia. *Palate Craniofac J*, 2013; 50: 623-626.
- 10) Hodgson AR, Stock FE. Anterior spinal fusion for the treatment of tuberculosis of the spine. *J Bone Joint Surg [Am]*, 1960; 42: 295-310.
- 11) Bradford DS. Anterior vascular pedicle bone grafting for the treatment of kyphosis. *Spine*, 1980; 5: 318-323.
- 12) Johnson JT, Robinson RA. Anterior strut grafts for severe kyphosis. Results of 3 cases with a preceding progressive paraplegia. *Clin Orthop Relat Res*, 1968; 56:525-536.
- 13) Sundaresan N, Galicich JH, Lane JM, Bains MS, McCormack P. Treatment of neoplastic epidural cord

- compression by vertebral body resection and stabilization. *J Neurosurg*, 1985; 63: 676–684.
- 14) Shirakusa T, Motonaga R, Yoshimine K, Takada S, Ueda H, Yamasaki S, Takachi T, Yoh S. Anterior rib strut grafting for the treatment of malignant lesions in the thoracic spine. *Arch Orthop Trauma Surg*, 1989; 108: 268–272.
 - 15) Harrington KD. Anterior cord decompression and spinal stabilization for patients with metastatic lesions of the spine. *J Neurosurg*, 1984; 61: 107–117.
 - 16) Sundaresan N, Galicich JH, Lane JM. Harrington rod stabilization for pathological fractures of the spine. *J Neurosurg*, 1984; 60: 282–286.
 - 17) Waisbrod H. Treatment of metastatic disease of the spine with anterior resection and stabilization by means of a new cancellous metal construct. A preliminary report. *Arch Orthop Trauma Surg*, 1988; 107: 222–225.
 - 18) Akamaru T, Kawahara N, Tsuchiya H, Kobayashi T, Murakami H, Tomita K. Healing of autologous bone in a titanium mesh cage used in anterior column reconstruction after total spondylectomy. *Spine*, 2002; 27: E329–333.