

CASE REPORT

Nagoya J. Med. Sci. 78. 329 ~ 334, 2016

Scleroderma renal crisis during intravenous cyclophosphamide pulse therapy for complicated interstitial lung disease was successfully treated with angiotensin converting enzyme inhibitor and plasma exchange

Norihiro Nagamura¹ and Seikon Kin²

¹*Department of Rheumatology and Allergy, Shimane Prefectural Central Hospital, Izumo, Japan*

²*Department of Nephrology, Shimane Prefectural Central Hospital, Izumo, Japan*

ABSTRACT

Systemic sclerosis (SSc) is a multiorgan disorder involving the skin, heart, lungs, kidneys, and intestines. Progressive interstitial lung disease (ILD) is a serious complication in SSc patients, and cyclophosphamide (CYC) is the only recommended therapy for this condition;¹⁾ however, its clinical effectiveness is not sufficient. Scleroderma renal crisis (SRC) is a rare complication, characterized by acute renal failure and progressive hypertension. Angiotensin-converting-enzyme inhibitor (ACE-i) is a widely accepted therapy for SRC. We report an SSc patient with SRC and progressive ILD who underwent treatment with CYC and successful treatment with ACE-i and plasma exchange (PE). SRC and ILD are significant contributors to morbidity and mortality among SSc patients, and the therapy for these disorders is of great interest to rheumatologists. This study presents the possibility of favorable effects of PE for SSc-associated ILD and SRC.

Key Words: systemic sclerosis, scleroderma renal crisis, interstitial lung disease, thrombotic microangiopathy, thrombotic thrombocytopenic purpura

This is an Open Access article distributed under the Creative Commons Attribution-NonCommercial-NoDerivatives 4.0 International License. To view the details of this license, please visit (<http://creativecommons.org/licenses/by-nc-nd/4.0/>).

INTRODUCTION

Systemic sclerosis (SSc) is a multiorgan disorder, and progressive interstitial lung disease (ILD) and scleroderma renal crisis (SRC) are serious complications in SSc patients. Cyclophosphamide (CYC) is the recommended therapy for SSc-associated ILD (SSc-ILD), but its effectiveness is not sufficient. We report a SRC patient who underwent treatment with CYC for progressive ILD and whose SRC was successfully treated with angiotensin-converting-enzyme inhibitor (ACE-i) and plasma exchange (PE).

Received: February 29, 2016; accepted: June 16, 2016

Corresponding author : Norihiro Nagamura, MD

Department of Rheumatology and Allergy, Shimane Prefectural Central Hospital. 4-1 Himebara, Izumo, Shimane 693-8555, Japan

Phone: +81-853-22-5111, Fax: +81-853-21-2975, E-mail address : nagamura@spch.izumo.shimane.jp

A CASE REPORT

A 67-year-old female was referred to our hospital for stiffness in her hands and a high titer of antinuclear antibody (ANA) of 1:640. She manifested Raynaud's phenomenon and redness of the fingers a year before. The patient had a history of hypertension, and her blood pressure (BP) at first consultation was 110/66 mmHg with a medication of 5 mg amlodipine besylate a day. Physical examination revealed scleroderma extending bilaterally to the upper arms, nailfold bleeding, and fine crackles on her back. Arterial oxygen pressure under room air was 81.9 mmHg. Her ANA titer was positive at 1:1280 with homogeneous and nucleolar patterns, and anti-topoisomerase I antibody titer examined by immunodiffusion was positive at 1:2. Tests for other specific autoantibodies were all negative. Serum Krebs von den Lungen-6 (KL-6) level was 331 U/mL, which was within the normal range. In addition to blood cell counts and urinalysis, other clinical data were unremarkable (Table 1). Electrocardiogram demonstrated no arrhythmia, and ventricular dysfunction and pulmonary arterial hypertension were not revealed by echocardiography. Chest computed tomography (CT) presented bilateral slight ground-glass opacity (GGO) predominantly around the dorsal area (Figure. 1A), and gastroduodenal endoscopy showed atrophic gastritis and mild reflux esophagitis. From her clinical findings, the diagnosis of diffuse-type SSc was made, and 20 mg/day of prednisolone (PSL) was initiated for the newly onset edematous scleroderma. One month after administration of PSL, her skin thickness had

Table 1 Laboratory data on first examination

<u>Urinalysis</u>		Aspartate aminotransferase	26 U/L
Specific gravity	1.027	Alanine aminotransferase	21 U/L
PH	6.0	Lactate dehydrogenase	197 U/L
Protein	(±)	Blood urea nitrogen	15.7 mg/dL
Glucose	(-)	Creatinine	0.60 mg/dL
Occult blood	(-)	Na	140.9 mmol/L
		K	4.4 mmol/L
<u>Blood cell count</u>		Cl	101.2 mmol/L
White blood cell	42 × 10 ² /μL	KL-6	331U/mL
Neutrophil	56.2 %	<u>Serology</u>	
Monocyte	8.7 %	C-reactive protein	0.06 mg/dL
Eosinophil	0.9 %	Immunoglobulin G	991 mg/dL
Lymphocyte	34.0 %	Immunoglobulin A	335 mg/dL
Red blood cell	469 × 10 ⁴ /μL	Immunoglobulin M	208 mg/dL
Hemoglobin	14.6 g/dL	Anti-nuclear antibody	1,280
Hematocrit	44.6 %	Anti-topoisomerase- I antibody	2
Platelet	23.0 × 10 ⁴ /μL	<u>Endocrinology</u>	
<u>Biochemistry</u>		Brain natriuretic peptide	21.8 pg/mL
Total bilirubin	1.5 mg/dL		

gradually improved.

Seven months after PSL therapy initiation (4 months before PE), she was aware of dyspnea on effort and worsening of hand stiffness. We started a medication of beraprost sodium for deterioration of her Raynaud's disease. The GGO shadow in her lung field in the chest CT had deteriorated (Figure. 1B), and arterial oxygen pressure under room air was decreased to 67.1 mmHg. Percentages of forced vital capacity (FVC) for the predicted values also decreased to 52.4% (Table 2). Progressive ILD was suspected, and therefore, 13.7 mg/kg body weight intravenous CYC (IVCY) pulse therapy was initiated for every 4 weeks. However, after four courses of IVCY therapy, clinical improvement could not be obtained, and she began to complain of appetite loss, nausea, and general fatigue. On second admission (19 days before PE), her BP was 106/70 mmHg and body temperature (BT) was 36.8°C. Laboratory data revealed that total bilirubin (T-Bil) and lactate dehydrogenase (LDH) levels had increased to 1.8 mg/dL and 345 U/L, respectively. C-reactive protein (CRP) level was 0.73 mg/dL, which slightly exceeded the normal upper limit of 0.5 mg/dL. The patient also tested negative for cytomegalovirus antigen. The serum KL-6 level had progressively increased to 767 U/mL. Urinalysis revealed mild proteinuria, but no hematuria. The GGO shadow of her lung field in a chest CT, which presented a nonspecific interstitial pneumonia (NSIP) pattern, had become slightly worse after four courses of IVCY therapy (Figure. 1C). Cardiac dysfunction and pulmonary arterial hypertension were not observed again by echocardiography. By a few weeks (5 days before PE), the serum T-Bil, LDH, and creatinine (Cr) levels had progressively increased, and this was accompanied by thrombocytopenia and anemia (Figure. 2). The patient's hemoglobin levels had decreased to 10.5 g/dL, and her haptoglobin level was below 10 mg/dL with a negative Coombs test, and

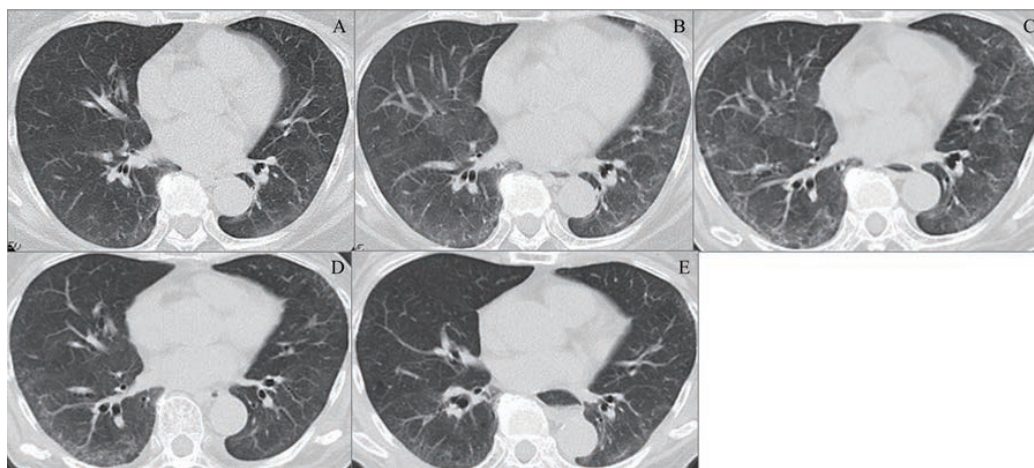


Fig. 1 Chest CT presented GGO shadow around dorsal area at first examination(A), got worse before IVCY(B), persisted before PE(C), improved right after PE(D), and still stabilized 2 years after PE(E).

Table 2 Change in pulmonary function before and after PE

	first examination (1 year before PE)	before IVCY (4 months before PE)	1 year after PE	2 years after PE
%FVC (%)	66.5	52.4	36.3	50.9
%DLCO (%)	74.0	51.9	not examined	63.1

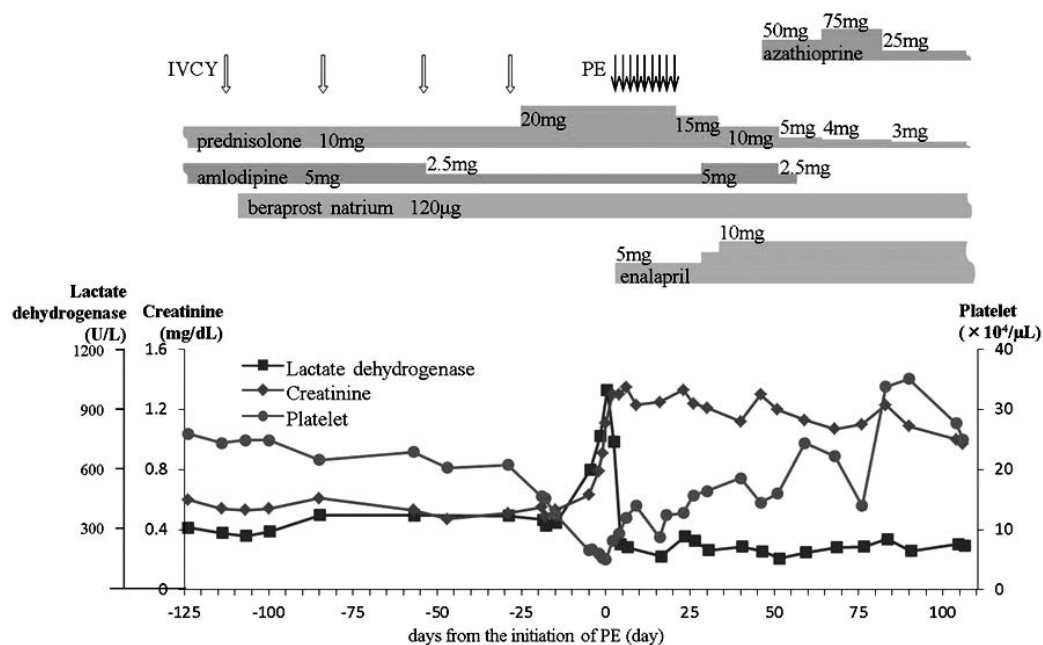


Fig. 2 Clinical course of serum creatinine, lactate dehydrogenase, and platelet. After ACE-i accompanied with PE therapy, the abnormal laboratory data suggesting TMA and renal damage had improved.

schistocytes were observed under the microscope. Further examination of the blood revealed an international normalized ratio prothrombin time of 0.88, an activated partial thromboplastin time of 30.8 s, and fibrinogen/fibrin degradation products (FDP) was 7.1 $\mu\text{g}/\text{mL}$. The FDP level was slightly elevated, and her fibrinogen level was 388 mg/dL , which was within the normal range. The plasma renin activity (PRA) and aldosterone (ALD) levels were elevated to 18.8 $\text{ng}/\text{mL}/\text{hr}$ and 289 pg/mL , respectively. Her blood pressure was 123/65 mmHg, which was within the normal range, but slightly elevated over her usual level. A disintegrin-like and metalloproteinase with thrombospondin type-1 motifs 13 (ADAMTS13) level was 32.4%, which was below the lower limit, but still detectable. The ADAMTS13 inhibitor levels were not examined. Tests for the perinuclear and cytoplasmic antineutrophil cytoplasmic antibodies (ANCA) and anti-RNA polymerase III antibody were negative. Taking these clinical findings into consideration, we diagnosed the patient with SRC with thrombotic microangiopathy (TMA) and hemolytic anemia. Although we did not get the result of ADAMTS13 level when serum Cr levels progressively elevated, we could not deny the involvement of thrombotic thrombocytopenic purpura (TTP). Therefore, we initiated enalapril treatment accompanied by PE with 73.4 mL/kg body weight frozen fresh plasma for nine courses. Renal biopsy was not performed because of the need for immediate therapeutic induction and avoiding progressive renal damage. Upon PE completion, azathioprine was added and PSL dose was tapered off. Following this, her blood pressure returned to the normal level of 110/70 mmHg, and abnormal laboratory data had improved (Figure. 2). Chest radiographic findings had stabilized (Figure. 1D and E), and the worsening of pulmonary function had stopped and improved at 2 years after PE (Table 2).

DISCUSSION

SRC is a severe complication, which mainly occurs in approximately 5% of diffuse-type SSc patients.²⁾ Typical manifestations of SRC are progressive BP elevation and renal damage, which sometimes lead to poor prognoses. Our case did not present severe hypertension or renal damage, but her BP and serum Cr were elevated above normal levels. TMA, which occurred in half of the SRC patients, was identified in our case.³⁾ ADAMTS13 level was detectable, which was suggestive of negative TTP.⁴⁾ Specific clinical features of TTP include hemorrhagic manifestation, fever, and neurologic deficits. Our case demonstrated none of these symptoms. In addition, the highest risk group for SRC are patients with early diffuse-type SSc and rapidly progressive skin sclerosis, but majority of TTP associated with SSc was reported to be of the limited type.⁵⁾ SRC results from endothelial injury and intimal proliferation in the renal arteries, followed by activation of the renin-aldosterone system. The PRA and ALD levels in our patient's case were high, which possibly indicated SRC. Although our patient should be diagnosed with SRC, it is difficult to rule out TTP at an acute phase of SRC because of the similarity between these two disorders and absence of ADAMTS13. To avoid therapeutic delay for the suspected disorder, initiation of PE can be considered under such circumstances.

One of the reasons for a normal BP was the patient's long-term use of antihypertensives, and the other was slowly elevation rate of BP. Considering the clinical course, the serum Cr and LDH levels rapidly elevated from 5 days before PE (Figure 2). At this time, renovascular damage had critically progressed because of TMA. PRA had elevated because of the decrease in renal blood flow, followed by progressive hypertension. We supposed that early initiation of ACE-i and PE interrupted the elevation of BP. If we had not started the therapy for SRC immediately, hypertension would have become apparent in our case.

Prior administration of high-dose corticosteroid is a risk factor for SRC.⁶⁾ This idea is based on the hypercoagulative state of the blood brought about by the corticosteroid.⁷⁾ On the other hand, some reports have mentioned that corticosteroid administration is not a risk factor of SRC, but rather is the result of therapy for severe SSc.⁶⁾ Steen *et al.* reported that a significantly greater proportion of SRC patients than SSc control patients received high-dose (>15 mg/day) corticosteroid for 6 months prior to SRC onset, but there was no difference in the patients who had been taking corticosteroid continuously for more than 6 months.⁸⁾ In our case, 11 months had passed from initiation of steroid therapy to SRC onset, which was a long interval for the development of steroid-induced SRC. Therefore, the contribution of corticosteroid to the development of SRC is unclear in this case.

Typical renovascular histopathological findings of SRC include so-called "onion skin" lesions in the arteries ranging from the arcuate to cortical radiate arteries and fibrinoid thrombosis of the small vessels.⁴⁾ These changes are caused by endothelial damage to the small vessels, leading to an increase in vascular permeability, endothelial cell proliferation, and stenotic change because of platelet aggregation.⁴⁾ Reactive stromal proliferation is observed around the vessels.³⁾ TMA and mechanical hemolytic anemia are caused by this vascular stenotic process. The increased production of Th2 cytokines, such as interleukin-4, -13, and transforming growth factor- β (TGF- β) in SSc patients cause angiofibrosis and intimal stenosis by the activation of fibroblasts.⁹⁾ Other mechanisms of vascular damage in SSc are antibody-dependent cell-mediated cytotoxicity by anti-endothelial autoantibody⁹⁾ and hyper-excretion of endothelin-1 (ET-1).⁴⁾ Although the only recommended therapy for SRC is ACE-i, the efficacy of PE combined with ACE-i has also been reported.¹⁰⁾ The therapeutic mechanism of PE is considered to be via the removal of cytokines that induce tissue fibrosis; vasoconstrictive factors, such as ET-1; and autoantibodies.¹¹⁾

SSc-ILD is also suspected to be caused by vascular stenosis and interstitial fibrosis due

to advanced cytokine production.¹¹⁾ Currently, the only recommended therapy for progressive SSc-ILD is CYC; however, the therapeutic efficacy of CYC is not sufficient.⁹⁾ In our case, the progressive interstitial shadow of pulmonary fibrosis stopped after PE, and stable radiographic findings had been maintained and pulmonary function had improved. Renovascular stenosis by endothelial injury, observed in the pathology of SSc patients, is also observed in the pulmonary arteries. Therefore, we speculate that PE has contributed to the clinical improvement of SSc-ILD to some extent. The serum Cr level at diagnosis is reported to be the prognostic indicator for SRC.²⁾ This demonstrates the importance of prompt therapeutic intervention. Immediate initiation of ACE-i and PE combination therapy is thought to be effective for the amelioration of renal function and treatment of progressive ILD.

Conflict of interest: None

REFERENCES

- 1) Kowal-Bielecka O, Landewé R, Avouac J, Chwiesko S, Miniati I, Czirjal L, *et al.* EUSTAR Co-Authors. EULAR recommendations for the treatment of systemic sclerosis: a report from the EULAR Scleroderma Trials and Research group (EUSTAR). *Ann Rheum Dis*, 2009; 68: 620–628.
- 2) Shanmugam VK, Steen VD. Renal disease in scleroderma: an update on evaluation, risk stratification, pathogenesis and management. *Curr Opin Rheumatol*, 2012; 24: 669–676.
- 3) Batal I, Domsic RT, Medsger TA, Bastacky S. Scleroderma renal crisis: a pathology perspective. *Int J Rheumatol*, 2010; 2010: 543704. doi:10.1155/2010/543704.
- 4) Ishizu A, Fukaya S, Tomaru U, Katumata K, Suzuki A, Umemoto Y, *et al.* Acute renal failure due to thrombotic microangiopathy in patient with scleroderma: autopsy case report. *Ann Vasc Dis*, 2012; 5: 458–461.
- 5) Iwagami M, Kubo K, Tanaka R, Kawahata K, Okamoto A, Hagino N, *et al.* Thrombotic thrombocytopenic purpura with severe hypertension in a patient with systemic sclerosis sine scleroderma and polymyositis. *Intern Med*, 2011; 50: 2413–2416.
- 6) Akoglu H, Atilgan GK, Ozturk R, Yenigun EC, Gonul II, Odabas AR. A “silent” course of normotensive scleroderma renal crisis. *Rheumatol Int*, 2009; 29: 1223–1229.
- 7) Naniwa T, Banno S, Takahashi N, Maeda S, Hayami Y, Ueda R. Normotensive scleroderma renal crisis with diffuse alveolar damage after corticosteroid therapy. *Mod Rheumatol*, 2005; 15: 134–138.
- 8) Steen VD, Medsger TA. Case-control study of corticosteroids and other drugs that either precipitate or protect from the development of scleroderma renal crisis. *Arthritis and Rheumatism*, 1998; 41: 1613–1619.
- 9) Manno R, Boin F. Immunotherapy of systemic sclerosis. *Immunotherapy*, 2010; 2: 863–878.
- 10) Stratta P, Besso L, Ferrero S, Sandri L, Thea A, Mazzocco G. Scleroderma renal crisis is still a life-threatening syndrome. *Ren Fail*, 1996; 18: 567–574.
- 11) Cozzi F, Marson P, Rosada M, De Silvestro G, Bullo A, Punzi L, *et al.* Long-term therapy with plasma exchange in systemic sclerosis: effects on laboratory markers reflecting disease activity. *Transfus Apher Sci*, 2001; 25: 25–31.