Nagoya J. med. Sci. 28: 261-272, 1966

VERTEX EXTRADURAL HEMATOMA (FOUR CASES DUE TO THE INJURY OF THE SUPERIOR SAGITTAL SINUS)*

KOJI NAKAMURA, HARUO HAYASHI, TADATAKA TAKEUCHI,

1st Department of Surgery, Nagoya University School of Medicine

HIDEO OBATA, AND HIROSHI NARITA

Obata Surgical Hospital, Yokkaichi
(Director: Prof. Yoshio Hashimoto)

SUMMARY

Four cases of the vertex extradural hematoma demonstrated by the lateral venogram of the carotid arteriography are reported. Two of them were treated non-surgically. In other two cases, craniotomy at the vertex and removal of the extradural clot was performed. Clinical manifestations of this hematoma are shown in the table summarizing from the world literatures. Advanced suture separations and fissure fractures were observed in all cases, which ran across the mid-line. The clinical course of this hematoma was mild and some of the patients did not lose consciousness. Intracranial hypertension was a main symptom, which was due to the brain congestion derived from the disturbance of venous return by the compression of the superior sagittal sinus. The lateral venogram of the carotid arteriography has the most important diagnostic value for this hematoma. Indication and risk of the operative treatment are also discussed.

INTRODUCTION

Acute extradural hematoma have been discussed by many authors[1], for this hemorrhage threatens the life after head injury. Among these, Jones[2)3)] has demonstrated in 1912 that the middle meningeal groove of the parietal bone was formed and occupied by the middle meningeal veins or sinuses not by the artery, and tears of the vein were more important than the tears of the artery for the extradural hematoma. Holmes and Sargent[4] have demonstrated the injury of the superior sagittal sinus and special clinical manifestations.

The injury of the dural sinus may happen by the penetrating wound. So the many sinus injuries occurred in battle field, where missiles were prevalent.

中村鋼二，林　春男，竹内忠孝，小畑秀雄，成田　弘

Received for publication March 7, 1966.

* These cases were presented at the 131st meeting of the Tokai Surgical Society at Tsu.

Collective reports have been written during and after the great war; by Cushing[5] during the first World War, by Matson[6] during the second World War and by Meirowsky[7] after the Korea War. These works have established the treatment method of the sinus injuries in their early stages to prevent the fatal complication of sinus thrombosis.

Apart from these penetrating injuries during war, many traffic accidents may cause the sinus injury even in the peace time. Clinical manifestations of the sinus injury distributed widely, and sometimes operative procedures were not necessary. Since the application of carotid arteriography to the patient of head injury is usual, diagnosis of the extradural hematoma becomes relatively easy. But the usual arterial phase has no significant diagnostic value to this vertex extradural hematoma. We emphasize the usefullness of the lateral venogram on the diagnosis of this type of the extradural hematoma.

We have experienced four cases of the vertex extradural hematoma due to the injury of the superior sagittal sinus. two cases of which were treated conservatively. In world literatures, we have found five cases, which were cured without surgery. These facts suggest the mildness of this type of hematoma in comparison with the lateral extradural hematoma due to the tear of the middle meningeal vessels.

CASE PRESENTATION

Case 1. A 27-year-old male, driving a motor bicycle after drinking, collided with a bicycle on April 15, 1963. He was conscious and returned home riding on his own motor bicycle. On the next day, he complained of gradually increased headache and repeated vomiting. He was transferred to Obata Surgical Hospital on April 17. Neurological examination revealed that his pupils were equal in size, round and reactive to light promptly. Both knee and ancle jerks were exaggerated bilaterally. Babinski reflex was elicitable on each side. Headache and vomiting increased and he became restless especially at mid-night, but no papilloedema was seen.

Carefully performed lumbar tap revealed that initial pressure was 230 mmH_2O and the cerebrospinal fluid was waterlike clear. Right side carotid arteriogram was taken but no apparent abnormal finding was discovered (Fig. 1). On April 20, because of severe headache, vomiting and restlessness and mild left side weakness, and because of marked fissure fracture running across the sagittal suture, right side carotid arteriography was performed again and venogram was taken (Fig. 2). This venogram of lateral view showed that a rather clear engorged cortical ascending veins were observed and that superior sagittal sinus was pushed downward and an avascular area was seen between this sinus and the vertex.

Craniotomy over the vertex on the mid-line as a free bone flap was per-

formed and about 30 grams of the extradural clot was removed. Massive venous bleeding was seen from a large Paccionian granule, which was controlled with some pieces of spongel. After the operation, he became conscious, and left side hemiparesis recovered gradually. Post-operative lateral venogram taken on May 8 (Fig. 3) revealed normal curvature of the superior sagittal sinus.

Case 2. A 29-year-old male was hit by a motor car, when riding on a bicycle, on October 9, 1963. When he was transferred to the hospital, he was unconscious, wounded on occipital mid-line. After 2 hours, he became conscious, complained of nausea, vomiting and headache of the occipital region. A lumbar tap was tried, initial pressure counted 230 mmH_2O and the cerebrospinal fluid tinged bloody. Skull x-ray demonstrated a fissure fracture across the mid-line on the occipital region and separation of the sagittal and rhomboid sutures was observed. On October 16, severe occipital headache with vomiting continued and optic fundi became edematous and left side VIth nerve paresis appeared. Somewhat weakness on both lower limbs was seen. Left side carotid arteriogram with venogram was taken, which showed a separation of the superior sagittal sinus from the vertex on lateral venogram (Fig. 4).

Craniotomy on the mid-line as a free bone flap was done and extradural hematoma of about 20 grams was removed. Post-operative course was satisfactory and post-operative venogram showed restoration of the superior sagittal sinus.

Case 3. A 40-year-old male was hit by a bicycle on April 24, 1964. When he arrived at our hospital 10 minutes after the accident by an ambulance, he was conscious, wounded on the frontal region and pale looked. Skull x-ray showed the separation of sagittal and coronal sutures, and fissure fracture of right frontal region. Carotid arteriography was performed immediately, which demonstrated normal record, however venogram was not taken. Headache increased gradually but no vomiting, optic fundi showed an engorged venous dilatation but the papillae were not edematous.

On May 6, carotid arteriography was performed on both sides again to take the venogram, he felt unpleasant dysesthesia on his right lower limb at the time of the injection of radiopaque dye into the left carotid artery. Lateral venogram (Fig. 5, 6) showed a separation of the superior sagittal sinus from the carvarium.

As the condition of the patient was not urgent; he complained only of mild headache and no weakness nor vomiting was seen, and he was able to walk as usual; he was treated non-surgically. Repeated carotid arteriography was done to take the lateral venogram to know the fate of the hematoma, on May 20 (Fig. 7) and on June 19 (Fig. 8); each showed gradual reduction of

the hematoma size. As his headache and vertigo though mild continued, two burr holes were made at the vertex on the mid-line, on June 1. The dura was thickly proliferated; as it were of a thickened periosteum after callus formation of fracture, but no extradural clot was seen, which was probably organized after a long post-traumatic period.

His mild headache and vertigo continued for about 6 months as was usually seen on the patient of the post concussion syndrome.

Case 4. A 23-year-old male was struck on the occipital region by a part of a crane, on November 24, 1964. He did not lose consciousness, and was lacerated on the occipital region, about 10 cm in length. On his arrival at the hospital 20 minutes after the accident, he was conscious, however he complained of blindness only being able to discriminate dark or light. Pupils were dilated about 4 mm in diameter and reactive to light promptly. External ocular muscles were not impaired. Knee and ancle jerks were hyperactive bilaterally. After 3 hours, he was conscious, had a severe headache from his eyes and repeated vomiting. Blindness changed to left side homonymous hemianopsia of clear form. Skull x-ray films showed the separation of the sagittal and rhomboid sutures. Right side carotid arteriography was performed, arteriogram showed no abnormal finding, lateral venogram (Fig. 9) revealed the compression of the superior sagittal sinus and the cortical ascending veins of the occipital region.

On the next day, headache and nausea continued though vomiting was ceased. He was fully conscious, pupils were 4 mm in diameter and reactive to light promptly, left side homonymous hemianopsia continued and optic fundi showed normal. Vertebral arteriography was done and the posterior cerebral arteries were not obstructed on each side.

Though we offerred the patient to operation he did not accept it, so he was treated with anticonvulsant, coagulant and vasodilator.

On November 26, 48 hours after the head injury left side homonymous hemianopsia was improved to normal. Headache became mild, then optic fundi became blurred on the left side. Marked occipital subperiosteal hematoma was punctured and about 50 ml of bloody fluid was removed. After this removal of bloody fluid, his headache decreased much. Puncture was repeated every other day for several times. On November 27, optic fundi had blurred margin bilaterally, and dysdiadochokinesis appeared and one foot standing was unsteady on both sides. Carotid arteriography was repeated on December 2, (Fig. 10), and on January 6, 1965 (Fig. 11), the hematoma decreased gradually in its depth. Optic fundi became normal on December 29, and the cerebellar dysfunction also disappeared, and patient was discharged on January 14, 1965.

CLINICAL MANIFESTATIONS

Probably the first report of the vertex extradural hematoma demonstrated by lateral venogram, was made by Wickbom[8] in 1949. Since his report, many authors have written such cases[9) 10) 11) 12) 13) 14) 15) 16) 17) 18) 19) 20) 21) 22)]. Table showed only the cases in which the detail of the clinical course have been described, excluding the cases in which the bleeding was apparently due to the tear of the Torcular Herophili.

It is interesting that Rockoff *et al.*[23] have reported a case of monkey with experimental head trauma and demonstrated the separation of the superior sagittal sinus from the vault on lateral venous phase of carotid serial arteriography.

Now we discuss on the clinical manifestations of the vertex extradural hematoma on each article (Table).

1) *Lucid interval*

Lucid interval is the period of consciousness after the recovery from *commotio cerebri*. Patient becomes unconscious again after the lucid interval. Lucid interval in the vertex hematoma is longer than that in the usual type of extradural hematoma. In some cases, lucid interval is absent, for the patient does not fall in unconsciousness. These facts show the mildness and the chronicity of this hematoma.

2) *Degree of unconsciousness*

This degree distributes from consciousness to coma broadly, but coma is not observed commonly. DA Pian *et al.*[13] indicated that severe vertex headache coexisted with restlessness and stupor. In our case 1, severe vertex headache had some relation with restlessness especially at mid-night. This degree may be affected by the violent complications such as brain contusion, intracerebral hematoma and/or subarachinoidal hemorrhage.

3) *Fractures and suture separation*

Many fissure fractures, which mean the linear fractures with wide gaps, run across the mid-line and separation of suture occurs in sagittal, coronal and rhomboid sutures. Each suture separation and fissure fracture is advanced, especially in non-operative cases. We guess that the advanced suture separations form the natural decompressive mechanism; for the extradural clot leaks out through the wide gap of the separated suture or fissure fracture. These mechanisms seemed to act intensively in non-operative cases. Indeed in our case 3, a large subperiosteal hematoma was seen on the fronto-parietal region, which probably had a communication with the extradural clot. In our case 4, his headache subsided after the puncture of subperiosteal hematoma was made.

TABLE (Reported Cases

Author	Case	Age/Sex	Lucid interval	Consciousness	Fractures and Suture separation	Headache
Columella *et al.*[12] 1959	1	47/male	(−)	Conscions	+	+
	2	41/male	?	Lethalgic	+	+
	3	26/male	20 hrs.	Lethalgic	+	
	4	44/male	(−)	Conscious	+	
Alexander[9] 1961	1	36/male	12 hrs.	Coma	Across the vertex along coronal suture	+
	2	23/male	5 days	Drowsy	Sagittal suture separation	+
	3	43/male	(−)	Conscious	Fracture crossing the mid-line	+
	4	39/male	(−)	Conscious	Across the vertex transversely	?
DA Pian *et al.*[13] 1963	1	60/male	10 hrs.	Coma	Fracture across the vertex	+
	2	37/male	?	Lethalgic	Sagittal and coronal suture separation	
	3	40/male	?	Deep coma	Depressed fracture on mid-line	
	4	40/male	48 hrs. (?)	Conscious	+	+
Iwata[15] 1964	1	33/male	12 hrs.	Lethalgic	Evident only on ope. on mid-line	+
	2	19/male	5 days	Lethalgic	Across the vertex on occipital region	+
Stevenson *et al.*[21] 1964	1	35/male	(−)	Conscious	Coronal fracture	+

4) *Intracranial hypertension*

Headache, nausea and vomiting are common in almost all cases. Headache of this patient is a very violent kind of vertex headache and causes the patient restless. Optic fundi was written as papilloedema or engorged venous dilatation. These findings suggest that the intracranial hypertension is caused by the intracranial congestion due to the disturbance of venous return by compression of the superior sagittal sinus. Alexander[9] thought that impairment of the efficiency of resorption of the cerebrospinal fluid by the local pressure of extradural clot might be a lesser factor contributing to intracranial hypertension.

In our case 4, first a severe headache and the retardation of cerebral blood flow (an excellent venogram was taken even 10 seconds after the injection of radiopaque dye into the carotid artery, which generally taken within 5 to 6 seconds) were observed; repeated arteriograms showed the improvement of the blood flow and good shadowing of the sphenoparietal sinus through the Trolard's anastomosis which developed as a collateral venous pathway, and in this time, papilloedema came out gradually (Fig. 9, 10, 11). Probably these relations could be demonstrated more clearly if the serial arteriogram would

in World Literature)

Nausea and Vomiting	Optic fundi	Motor function	Interval from injury to operation
	Retinal edema	Monoparesis (right arm)	Not operated
+	?	Babinski on left side	Not operated
	Venous congestion	Hemiparesis	18 days
	Venous congestion Papilloedema	Hemiparesis	4 days
+	Engorgement of retinal veins. Early papilloedema	Hemiplegia Decerebration	1 day
+	Papilloedema	Hemiparesis	6 and 8 days
+	Early papilloedema	No weakness	Not operated
?	Normal	Hemiparesis	2 days
+	Venous congestion	Hemiparesis	1 day
	Venous congestion	Hemiplegia	1 day
	Venous congestion	Hemiparesis	1 day
+	Venous congestion	?	Not operated
+	Normal	Hemiparesis	7 days
+	Papilloedema Venous congestion	Paraparesis	7 days
+	Papilloedema	No weakness	42 days

have been taken. The development of the collateral venous pathway is another mechanism that decreases the intracranial hypertension, for in this hematoma, intracranial hypertension is rather due to the intracranial congestion than due to the cerebral edema. If the brain contusion or intracerebral hematoma is complicated, intracranial hypertension may become more intensive.

5) *Motor function*

We have experienced two cases in which the mild vertex extradural hematoma was complicated with the usual extradural hematoma of the temporal region, in these cases hemiplegia with unconsciousness was the main sign, and patients showed rapidly deteriorating course. Apart from these complicated cases, hemiplegia or hemiparesis seems to be common even in the pure vertex extradural hematoma. DA Pian *et al.*[13] emphasized the unilateral Babinski reflex. These facts are important in differential diagnosis between the vertex extradural hematoma and the usual hematoma. If the lateral venogram had not been taken, the vertex extradural hematoma could not be found, for the arterial phase showed normal record. The lateral venogram should be taken even when the hemiparesis or the hemiplegia exists in these patients of head

injury. Alexander[9] suggested the cause of hemiparesis as the obstruction of cerebral veins especially as compression of thin walled lacunae. Hemiparesis sometimes accompanied with hemihypesthesia[12,14] that was probably due to the congestion by the compression of the Rolandic vein. In our case 3, patient felt unpleasant dysesthesia on his right lower limb when the radiopaque dye was injected into the left carotid artery which might be due to the congestion of dye on the postcentral gyrus.

6) Eye sign

Cortical blindness or homonymous hemianopsia was observed in the extensive laceration of the posterior portion of the superior sagittal sinus, of the Torcular Herophili, of the transverse sinus or of the lateral sinus, by the penetrating wound[6,7].

In our case 4, first cortical blindness continued for 3 hours, which was changed to homonymous hemianopsia and persisted for 48 hours. The mechanism of this case might concern with the cerebral congestion or the local cerebral edema, and the injury might not have been severe enough to produce permanent damage.

Anisocoria was not commonly observed, which was seen in Alexander's case 1.

7) Angiographic findings

No abnormal finding may be observed on the antero-posterior arteriogram. On lateral arterial view, the pericallosal artery may be pushed down on its course in some cases[9,14].

The most characteristic is the compression of the superior sagittal sinus demonstrated on the lateral venogram. An avascular area is observed between the vertex and the superior sagittal sinus. The cortical ascending veins or sometimes the superior sagittal sinus are engorged in the anterior portion to the hematoma and rather thin in the posterior region. These findings suggest the secondary congestion of the brain due to the disturbance of venous return.

We emphasize the significance of the lateral venogram in these patients. If possible, the biplain serial angiography should be done, because the blood flow of these patients is retarded much, so it is difficult to determine the good timing to take the excellent venogram.

8) Others

Meningeal irritating sign was observed in Alexander's case 2, in Columella's case 3 and in Hashimoto's case. This sign was probably due to the complication of subarachinoidal bleeding. Lumbar tap of these cases showed bloody cerebrospinal fluid.

Lumbar tap was tried in some cases, and demonstrated increased pressure. It is advisable however that lumbar tap for such patients as suffering from intracranial hypertension should be avoided to prevent the tentorial herniation.

OPERATION

Seven cases including our case 3 and 4, have been treated without surgery. Each of them did not lose consciousness. Considering the probability of permanent damage resulted from long continued congestion, operation should be performed even in these conscious cases. Congestion is seemed more severe when the position of hematoma is nearer to the Torcular Herophili, or when the hematoma size is more extensive in its thickness. But the clear determination of indication by these factors are yet difficult.

DA Pian *et al.*[13] classified this kind of hematoma to three types. The first type is characterized by the pure intracranial hypertension that intense headache in the vertex, vomiting and restlessness begin after short interval of no symptoms, and headache lasts for 10 to 20 days and then disappears. The second type has the sign of compression of the Rolandic vein, that has motor and sensory deficits in addition to intracranial hypertension, and a period of stupor lasting for several days. In the third type, the symptoms of the above described progress quickly, probably complicated with brain contusion. Operation is necessary in the second and the third types, especially in the latter.

We chose the craniotomy of a free bone flap after four burr holes which were made on the vertex just on the hematoma. Extradural clot was removed carefully. Lacerated sinus was repaired with several pieces of spongel.

Operation to dural sinus has some troublesome problems: control of bleeding, air embolism and secondary sinus thrombosis.

1) Bleeding

Massive bleeding may occur on the vertex from dural sinus when the bone flap is turned. But in extradural hematoma, dural sinus has been separated from the skull by the extradural clot and the bleeding points have been obstructed with clot, so the bleeding on craniotomy is not so much. Care should be taken when removing the clot, because exposure of the lacerated dural sinus causes massive venous bleeding and air embolism. It is advisable not to remove the clot before the plan of repairment of the dural sinus is established.

Bleeding of this hematoma may be mainly due to the laceration of the superior sagittal sinus, and occasionally due to the laceration of the diploic vein or peripheral branch of the meningeal vessels.

2) Air embolism

Many authors have emphasized the risk of air embolism[5)6)7)]. Probably air embolism may have relation to intrathoracic negative pressure. We chose the intubated general anesthesia with controlled respiration through non-rebreathing valve. Intensive negative intrathoracic pressure may increase the negative pressure of the jugral vein and the venous sinus and results the air

embolism which is inhaled from the lacerated point. Patient should be placed in horizontal position, we preferred lowering of the head despite increased bleeding from such posturing.

3) *Secondary sinus thrombosis*

Matson[6] emphasized that a large defect of dural sinus should be repaired with silk sutures and fascia, not with spongel, gel foam or muscle stamp to avoid the secondary sinus thrombosis. Meirowsky[7] described that secondary thrombosis might depend not so much on the method of repair as on the maintenance of blood volume and pressure before, during and immediately after operation. In our cases, as the defect was small, spongel was used; secondary thrombosis was not observed. It is advisable that too much spongel should not be applied because the superior sagittal sinus could be compressed by the spongel.

PROGNOSIS

The prognosis is good, if the operation is performed without delay. The degree of residual symptom depends upon the duration of congestion and complication of other type of head injury such as brain contusion, intracerebral hemorrhage etc. All patients are alive in the reported cases in the world literatures. As the diagnosis of this hematoma is difficult even with carotid arteriography or burr holes which are generally made for acute head injury, the fate of many severer undiagnosed cases of this vertex hematoma may be failed to oberve.

ACKNOWLEDGEMENT

The authors wish to thank Prof. Dr. Y. Hashimoto for his advise.

REFERENCES

1. Gurdjian, E. S. and Webster, S. E. Head injuries mechanismus, diagnosis and management. 238, Little Brown and Co., Boston, Toronto, 1958.
2. Jones, F. W. On the grooves upon the ossa parietalia commonly said to be caused by the arteria meningea media. *J. Anat.* **46**: 228, 1912.
3. Jones, F. W. The vascular lesion in some cases of middle meningeal haemorrhage. *Lancet* **2**: 7, 1912.
4. Holmes, G. and Sargent, P. Injuries of the superior longitudinal sinus. *Brit. Med. J.* **2**: 493, 1915.
5. Cushing, H. A study of a series of wounds involving the brain and its enveloping structures. *Brit. J. Surg.* **5**: 558, 1918.
6. Matson, D. D. The treatment of acute craniocerebral injuries due to missiles. 52, Charles C. Thomas, Springfields, Ill., 1948.
7. Meirowsky, A. M. Wound of dural sinuses. *J. Neurosurg.* **10**: 496, 1953.
8. Wickbom, I. Angiography by post-traumatic intracranial hemorrhage. *Acta Radiol.* **32**: 249, 1949.

9. Alexander, G. L. Extradural hematoma at the vertex. *J. Neurol. Neurosurg. Psychiat.* **24**: 381, 1961.
10. Brodin, H. Extradural hematoma, a survey of cases covering a 20-year period with special reference to diagnosis. *Acta Chir. Scand.* **102**: 99, 1961.
11. Campiche, R. Hámatome épidural Subaigu de localisation inhabituelle avec son image artériographique. *Radiol. Clin.* **31**: 95, 1962.
12. Columella, F., Delzanno, G. B. and Nicola, G. C. L'ematoma epidurale al vertice. *Sist. Nerv.* **2**: 558, 1959.
13. DA Pian, R., Benati, A., Bricolo, A., Perbellini, D. and Dalle Ore, G. Ematomi extradurali traumatici del terzo medio del senso longitudinale superore. *Osped. Ital. Chir.* 8: 667, 1963.
14. Hashimoto, Y. Angiography, 176, Igaku Shoin Ltd. Tokyo, 1962, (in Japanese).
15. Iwata, K. Sagittal sinus hematoma. *Pacif Med. Surg.* **72**: 340, 1964.
16. Lindgren, S. O. Acute severe head injuries. Clinical diagnosis and classification with respect to early prognosis and treatment. *Acta Chir. Scand.* suppl. **254**: 49, 1960.
17. Melo, A. DA. R. and Resende, J. (Two cases of chronic extradural hematoma.) *Rev. Esp. Otoneurooftal.* **18**: 166, 1959.
18. Pecker, J., Javalet, A. and Le Menn L'hématome extra-dural. Réflexions sur une série de 111 cas personnels. *Neurochirurgie* **5**: 428, 1959.
19. Pecker, J., Javalet, A. and Stabert, C. L'angiographie dan les traumatismes crâniens. *J. Radiol Electr.* **40**. 623, 1959.
20. Petit-Dutaillis, D., Guiot, G., Pertuiset, B. and De Besnerais, Y. Les Hématomes extraduraux de la fosse cérébelleuse. *Press. med.* **64**: 521, 1956.
21. Stevenson, C. C., Brown, H. A. and Hoyt, W. H. Chronic venous epidural hematoma at the vertex. *J. Neurosurg.* **21**: 887, 1964.
22. Tiwisina, T. and Stäcker, A. D. Die frischen Schädel-Hirnverletzungen im Gefässbild. *Chirurg.* **30**: 344, 1959.
23. Rockoff, S. D. and Ommaya, A. K. Experimental head trauma. cerebral angiographic observations in the early post-traumatic period. *Amer. J. Roentgen.* **91**: 1026, 1964.

CAPTIONS FOR FIGURES

FIG. 1. Right side carotid arteriogram of lateral view of case 1, showing only mild compression of the pericallosal artery.

FIG. 2. Lateral venogram of case 1, showing an avascular area on the vertex between the superior sagittal sinus and the carvarium, corresponding to the fissure fracture.

FIG. 3. Post-operative lateral venogram of case 1, showing the recovery of the superior sagittal sinus to normal curvature and position.

FIG. 4. Lateral venogram of case 2, which showed the avascular area on the parietal region of mid-line.

FIG. 5. Lateral venogram of case 3, which was taken by the injection of radiopaque dye into right carotid artery, showing the characteristic view of the vertex extradural hematoma.

FIG. 6. Lateral venous phase of left carotid arteriography of case 3, which was taken on May 6, at the same time of Fig. 5. Marked compression of the cortical ascending veins especially of the Rolandic vein was observed.

FIG. 7. Lateral venogram of left side of case 3, taken on May 20, showing the decreased extradural hematoma.

FIG. 8. Lateral venogram of left side of case 3, taken on June 19, showing the remarkably decreased hematoma, only thin layer was left.

FIG. 9. Lateral venogram of case 4, taken on November 24, showing the retarded circulation, obscure shadow of the superior sagittal sinus and an avascular area on occipital region.

FIG. 10. Lateral venogram of case 4, taken on December 2, the avascular area reduced in its size and the Trolard's anastomosis developed.

FIG. 11. Lateral venogram of case 4, taken on January 6, 1965, the extradural hematoma disappeared almost completely.

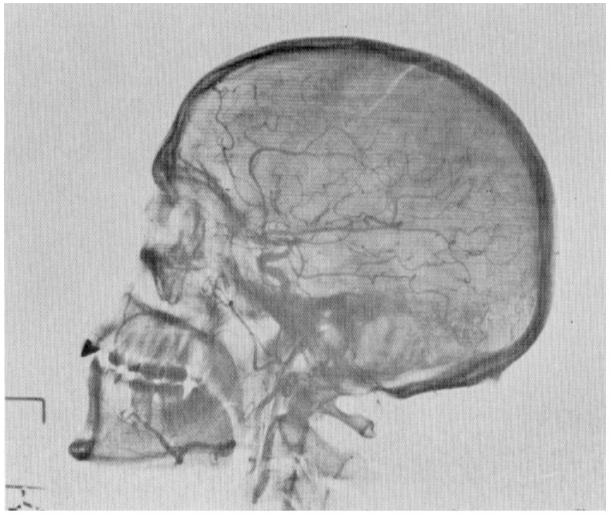

FIG. 1

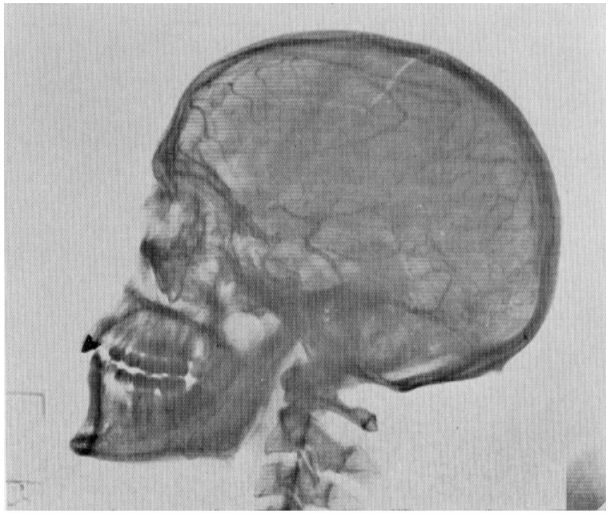

FIG. 2

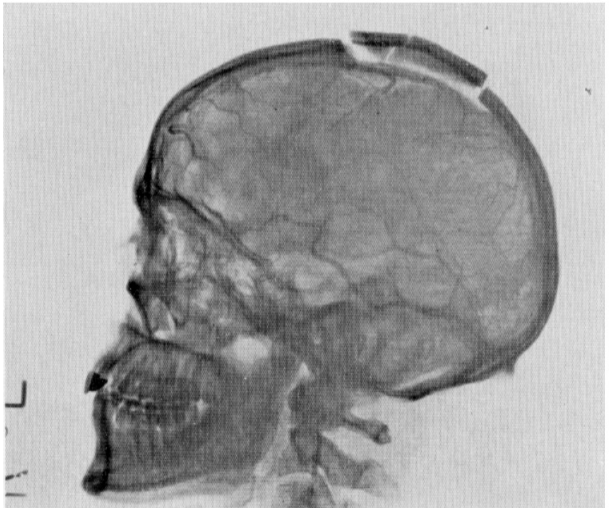

FIG. 3

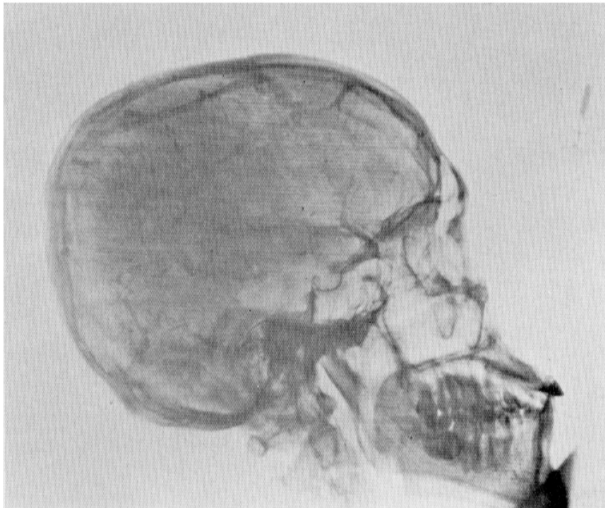

FIG. 4

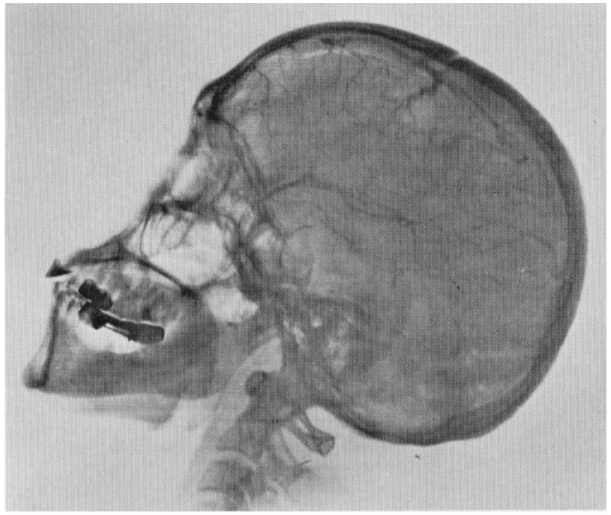

FIG. 5

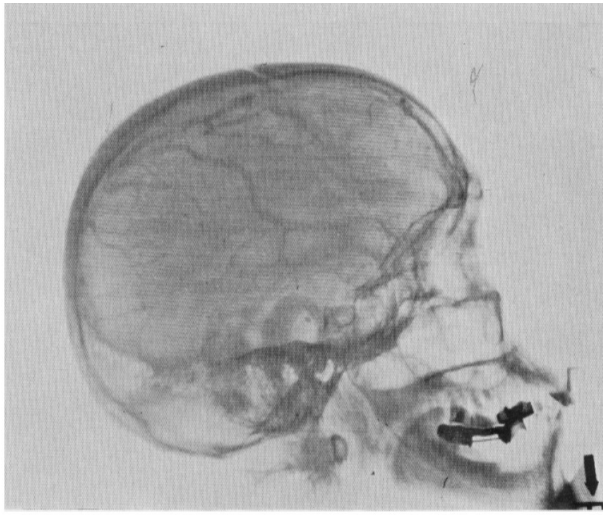

FIG. 6

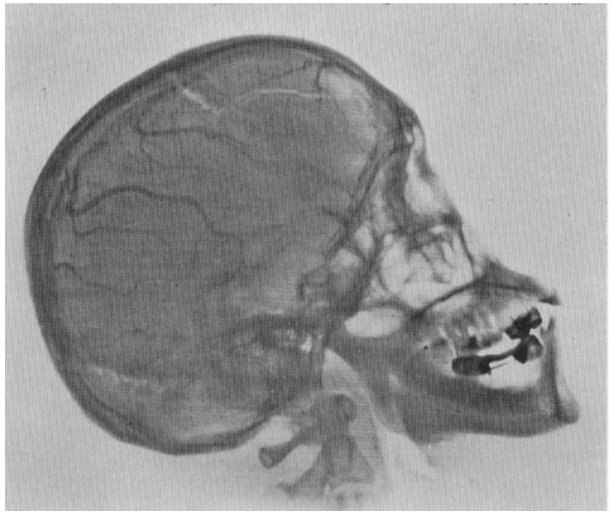

FIG. 7

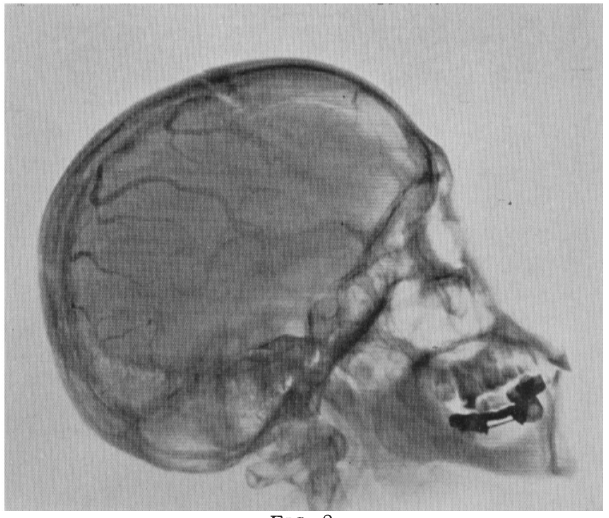

FIG. 8

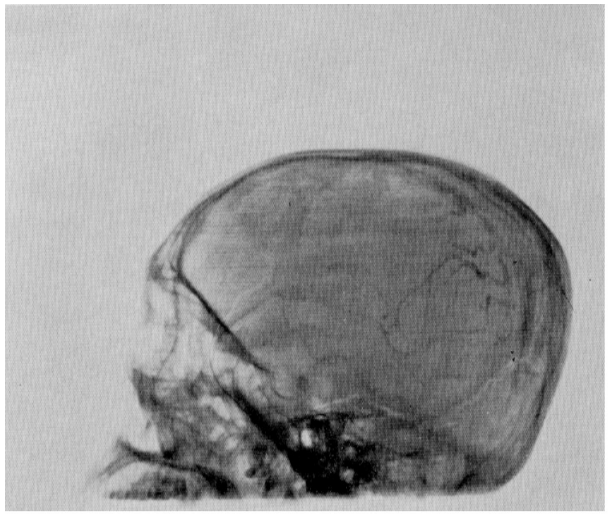

FIG. 9

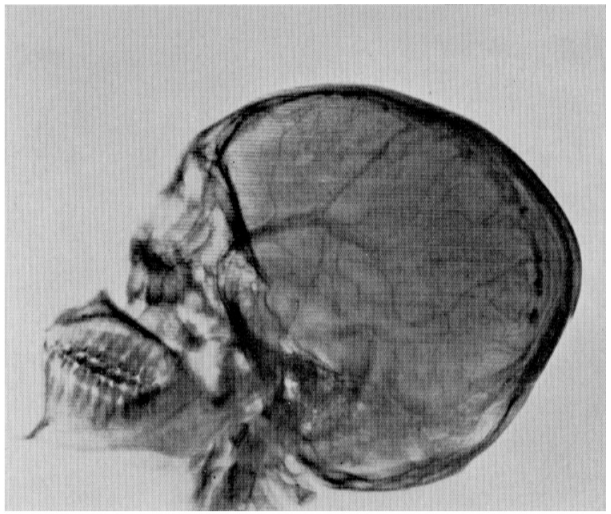

FIG. 10

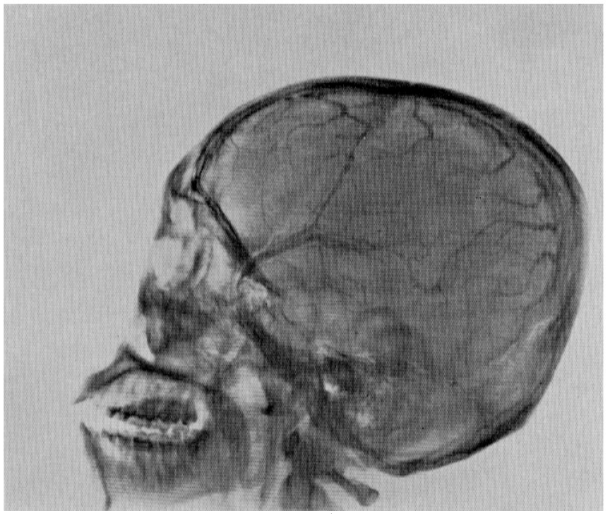

FIG. 11