Nagoya J. med. Sci. 28: 271-274, 1967

THE CLINICAL VALUE OF MALIGANT CELLS FROM ENEMA RETURNS IN CARCINOMA OF THE COLON

TATSUHEI KONDO AND YOSHIMASA MOMOI

2nd Department of Surgery, Nagoya University School of Medicine
(Director: Emeritus Prof. Hajime Imanaga)
and
(Director :Prof. Shin Hoshikawa)

SUMMARY

We described a method for recovery of cancer cells from large intestinal tumors by enema returns. By this method the discovery rate of cancer cells was 23 of 36 cases, namely 69.6% and the rate was lower for tumors located away from anus. The phosphorylase staining mothod is useful to distinguish doubtful cancer cells.

Since Papanicolaous advocated in 1943 the cytological diagnosis of carcinoma of the uterus by vaginal smear, exfoliative tumor cells from various tubal organs have been used for cytological diagnosis. For the diagnosis of malignant tumor of the colon, a long tubal organ, the detection of malignant cells from this organ has definite meaning when a correct diagnosis is not easy by palpation, sigmoidscopy or X-ray examination.

There have been several reports made on the recovery of malignant cells from enema returns, such as those of Wisseman[1], Blank[2], Bader[3], Rubin[4], Galombos[5], Raskin[6] and Cameron[7], and the diagnostic success is said to be between 5-96%, a higher discovery rate being obtained by using particular instruments, for example a brush or balloon. This method is safe and does not need complicated instrument or technique and can be performed easily clinically, and with fair diagnostic accuracy.

MATERIALS AND METHODS

Prior to the examination the patient is made to take light meals for two days. The day before the test a laxative is given and eight hours later an enema is performed with 500-1000 ml of saline. He is abstained from food thereafter and an enema is performed again the next morning with 500-1000 ml of saline, and the two fluids are examined after mixture. The enema is performed with the left side of the body below, the upper left extremity pulled back, the chest against the bed and the right lower extremity bent with the

近藤達平，桃井能生
Received for publication September 26, 1966.

knee near the face and the left lower extremity half bent. Enema is given with salines in this position and the abdomen is massaged repeatedly in order to spread the fluid into the large intestine. This procedure is repeated in the reverse position. The enema fluid which has been collected in this manner is filtered by suction through metal mesh of 200 mesh into a bottle. The fluid is centrifuged at 500-1,000 rpm for 5 minutes to obtain a cell sheet to smear on a glass slide and double stained with May-Giemsa and Hematoxylin after fixing with metanol. (Fig. 1-4)

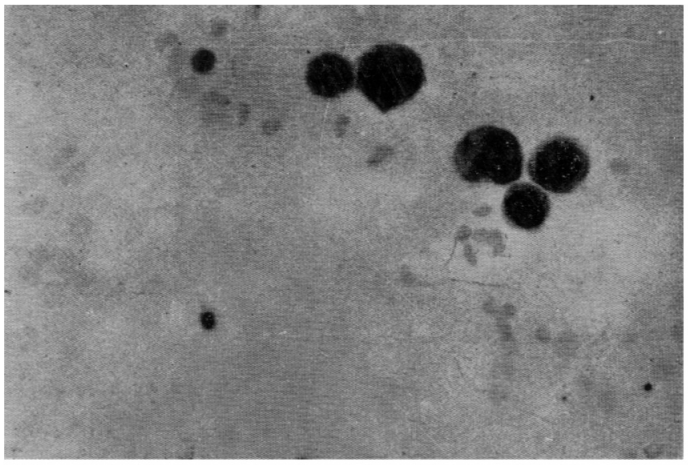

FIG. 1. Malignant trmor cells of the ascending colon.

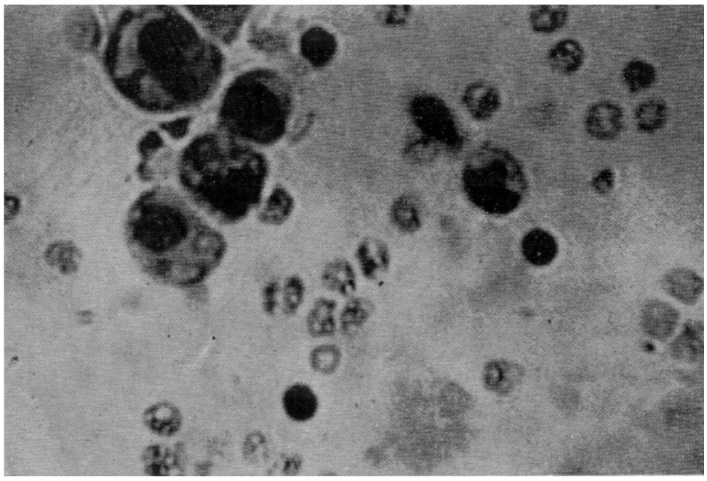

FIG. 2. Malignant tumor cells of the transverse colon.

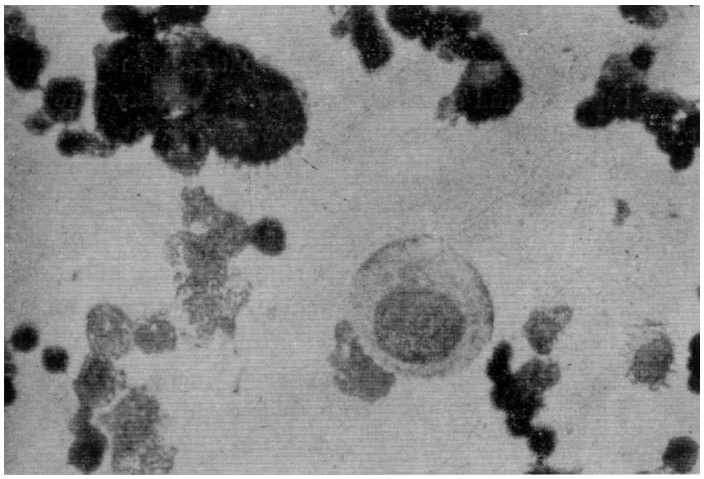

FIG. 3. Malignant tumor cells of the descending colon.

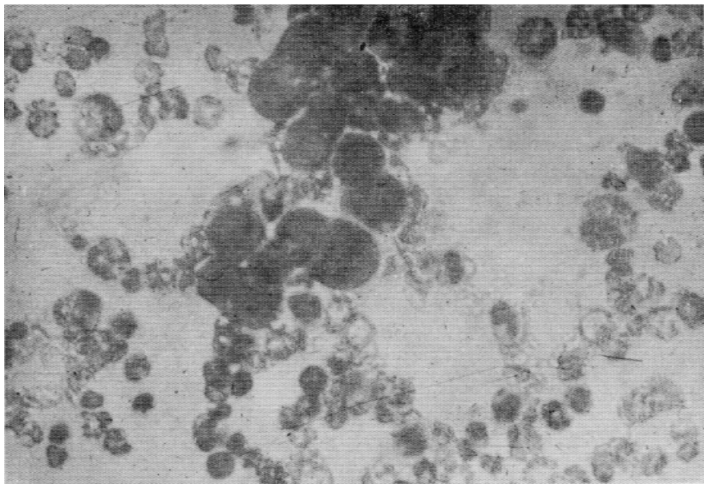

FIG. 4. Malignant tumor cells of the rectum.

The malignant cells are classified by Papanicoloaus' classification and the frequency of cells divided into five groups. When the cells are doubtful malignant or benign, they were confirmed after staining with phosphorylase reaction of Takeuchi[8]. The epithelium of the colon is covered with a monolayer of columnar or goblet cells and it is easy to distinguish them from malignant cells, except for only a few pseudopositive ones. In case of polyp, on the other hand, some of the epithelial cells are hard to distinguish from malignant cells.

RESULTS

The cases investigated were 33 malignant patients and as control rectal polyposis 1, rectal ulcer 1 and stomach cancer 1. Twenty three cases of the 33 malignant tumors were positive, namely 69.6%. (Fig. 5)

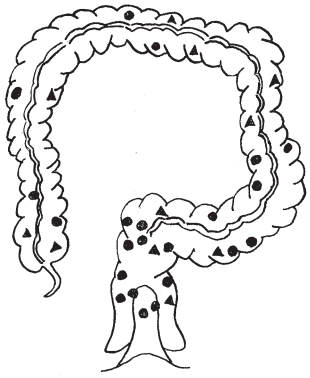

● malignant cell positive
▲ malignant cell negative

FIG. 5. Localization of malignant tumor of the colon and the results of their examination.

When the cases are classified according to site 3 were positive of 6 ascending colon cases, 2 of 4 colon transversus, 3 of 5 descending colon, 3 of 4 sigmoidal and 12 of 14 rectal cases, and are shown in the figure. From these results we can say that the discovery rate is low when located far from anus and this might be due to the anatomical reason that the enema can not reach well enough areas distal from anus. Another point requiring attention is to repeat the above mentioned procedure with the cooperation of the patient. The effort of abdominal massage of the assistant can promote the experimental success.

REFERENCES

1) Wisseman, C. L. Jr., Lemon, H. M. and Lawrence, K. B., Cytologic diagnosis of cancer of the descending colon and rectum, *Surg. Gynec. Obstet.*, **89**, 24, 1949.
2) Blank, W. A. and Steinberg, A. H., Cytologic diagnosis of malignancies of the lower bowel and rectum, *Amer. J. Surg.*, **81**, 127, 1951.
3) Bader, G. M. and Papanicolaou, G. N., The application of cytology in the diagnosis of cancer of the rectum, sigmoid, and descending colon, *Cancer*, **5**, 307, 1952.
4) Rubin, C. E., Massey, B. W., Kirsner, J. B., Palmer, W. L. and Stonecypher, D. D., The clinical value of gastrointestinal cytologic diagnosis, *Gastroenterology*, **25**, 119, 1953.
5) Galambos, J. T. and Klayman, M. I., The clinical value of colonic exfoliative cytology in the diagnosis of cancer beyond the reach of the proctoscope, *Surg. Gynec. Obstet.*, **101**, 673, 1955.
6) Raskin, H. F., Palmer, W. L. and Kirsner, J. B., Exfoliative cytology in diagnosis of cancer of the colon, *Dis. Colon Rectum.*, **2**, 46, 1959.
7) Cameron, A. B. and Thabet, R. J., Recovery of malignant cells from enema returns in carcinoma of the colon, *Surgical Forum*, **10**, 39, 1959.
8) Takeuchi, Y., Histochemical aspects of glycogen formation in cells and its clinicopathological application, *Jap. J. Clin. Path.*, **9**, 28, 1961. (in Japanese)