The Journal of Investigative Dermatology
Letter to the Editor

Dyschromatosis symmetrica hereditaria and Aicardi-Goutières syndrome 6 are phenotypic variants caused by *ADAR1* mutations

Authors
Michihiro Kono[1]*, Fumihiro Matsumoto[2], Yasuhiro Suzuki[2], Mutsumi Suganuma[1], Hirotomo Saitsu[3], Yasutomo Ito[4], Sakuhei Fujiwara[5], Shinichi Moriwaki[6], Kazuhiko Matsumoto[7], Naomichi Matsumoto[3], Yasushi Tomita[1], Kazumitsu Sugiura[1], Masashi Akiyama[1]*

[1] Department of Dermatology, Nagoya University Graduate School of Medicine, Nagoya, 466-8550, Japan
[2] Department of Pediatric Neurology, Osaka Medical Center and Research Institute for Maternal and Child Health, Izumi, 594-1101, Japan
[3] Department of Human Genetics, Yokohama City University Graduate School of Medicine, Yokohama, 236-0004, Japan
[4] Division for Medical Research Engineering, Nagoya University Graduate School of Medicine, Nagoya, 466-8550, Japan
[5] Department of Dermatology, Oita University Faculty of Medicine, Yufu, 879-5593, Japan
[6] Department of Dermatology, Osaka Medical College, Takatsuki, 569-8686, Japan
[7] Department of Dermatology, Shinshu University School of Medicine, Matsumoto, 390-8621, Japan

***Corresponding authors**:

Michihiro Kono and Masashi Akiyama
65 Tsurumai-cho, Showa ku, Nagoya, 466-8550, Japan
Tel.: +81-52-744-2314; Fax: +81-52-744-2318
E-mail address: miro@med.nagoya-u.ac.jp (MK),
makiyama@med.nagoya-u.ac.jp (MA)

Text word count, number of references, tables, and figures
988 words in the main text, 10 references, 2 figures, 0 tables

Short title: Clinical diversity for *ADAR1* mutations

Abbreviations: DSH, dyschromatosis symmetrica hereditaria; ADAR1, adenosine deaminase acting on RNA 1; AGS, Aicardi-Goutières syndrome; RT-PCR, reverse transcription PCR; NMD, nonsense-mediated mRNA decay

Key words
(1) dyschromatosis symmetrica hereditaria (DSH), (2) Aicardi-Goutières syndrome (AGS), (3) adenosine deaminase acting on RNA 1 gene (*ADAR1*), (4) compound heterozygous mutations

Main Text

Dyschromatosis symmetrica hereditaria (DSH: MIM#127400) is an autosomal dominant skin disease caused by a heterozygous mutation in adenosine deaminase acting on RNA 1 gene (*ADAR1*, NM_001111.4) (Miyamura *et al.*, 2003). DSH is characterized by a mixture of hyper- and hypo-pigmented small macules on the dorsal aspects of the extremities.

In 2012, it was clarified that *ADAR1* mutation causes Aicardi-Goutières syndrome (AGS) (Rice *et al.*, 2012), a genetic inflammatory disorder that affects the nervous system. Eight out of the 10 reported AGS patients had homozygous or compound heterozygous mutations in *ADAR1*, and the other 2 reported AGS cases were caused by the identical heterozygous mutation p.Gly1007Arg.

We report a case of DSH with neurological symptoms and brain calcification resulting from compound heterozygous *ADAR1* mutations, and we study the RNA editing activity of those mutations.

A Japanese girl had an afebrile convulsive seizure at the age of 1 month. She neurologically regressed from the age of 13 months and was unable to sit unassisted at the age of 17 months. At the age of 15 months, she developed hyper-creatinine-phosphokinasenemia. Brain calcification was recognized at the age of 4 months and was worse at the age of 17 months (Figure 1g, h). At the age of 5 months, she developed a mixture of 5-mm hyper- and hypo-pigmented macules on the whole body, particularly on the extremities (Figure 1b-d), and freckle-like macules on the face (Figure 1e). Her maternal great-grandfather, grandfather and aunt showed these skin lesions on the finger joints (Figure 1a). Her mother had very faint skin lesions on the fingers and the toes (Figure 1f).

The proband had the compound heterozygous mutations c.1600C>T (p.Arg534X) (maternal) and c.3444-1G>A (IVS14-1G>A) (paternal) in *ADAR1* (Figure 1i, j). To our knowledge, neither mutation has been previously reported.

From our RT-PCR results (Figure 1k), p.Arg534X was thought to cause nonsense-mediated mRNA decay (NMD) and ADAR1 protein deficiency.

c.3444-1G>A was revealed to result in aberrant splicing and insertion of 36 bp between exon 14 and exon 15, i.e., p.1148_1149insSQVNNECFCFSK in the deaminase domain (Figure 1j, l). To our knowledge, in-frame insertion mutations in *ADAR1* have not been reported previously.

In two families that we previously reported, the heterozygous *ADAR1* mutation p.Gly1007Arg lead to DSH phenotypes with neurological symptoms. We evaluated the RNA editing ability of heterozygous p.Gly1007Arg, other heterozygous mutations in DSH and homozygous mutations in AGS using an *in vitro* double-stranded RNA editing assay (Herbert *et al.*, 2002) (Figure 2a). There are two isoforms of ADAR1 (p150 and p110), and loss of function of the p150 isoform is known to cause DSH (Suzuki *et al.*, 2007).

The A-I editing efficiencies of cos7 cells transfected with DSH or AGS causative mutant p150 isoforms are summarized in Figure 2b. The average A-I editing efficiency of transfectants of 3 half-wild/half DSH-causative mutants was approximately half (48.1 ±

13.4%) that of only wild-type plasmid transfectants. The average A-I editing efficiency of transfectants of the 3 simple AGS-causative mutants was very low, 20.9 ± 2.7% that of only wild-type plasmid transfectants, possibly leading to the AGS phenotype. Transfectants of half-wild/half DSH with the neurological symptoms-causative exceptional mutant p.Gly1007Arg showed an A-I editing efficiency of 30.2% that of only wild-type plasmid transfectants, between the above-mentioned values of transfectants with DSH-causative mutants and AGS-causative mutants. These results seem consistent with the phenotypic severity of DSH and AGS. However, there are some discrepancies from the editing data of previous studies (Mannion *et al.*, 2014; Rice *et al.*, 2012). This might be because editing assay results can depend on the editing substrates or cell types (Rice *et al.*, 2012).

We speculate that the reduction in editing efficiency resulting from compound heterozygous *ADAR1* mutations could be sufficiently below the threshold needed for the neurological phenotype of AGS to develop. In contrast, the reduction in editing efficiency resulting from general heterozygous mutations might be insufficient for AGS to develop.

Thus, patients with heterozygous *ADAR1* mutations other than p.Gly1007Arg show only skin symptoms without neurological abnormalities.

Ten AGS cases caused by *ADAR1* mutations have been reported (Rice *et al.*, 2012). Six cases were Caucasians, 2 were Pakistanis, 1 was Indian and 1 was Brazilian. The skin colors of these patients were not reported. There have been no reports of East Asian patients developing AGS as a result of *ADAR1* mutations. In contrast, most DSH cases have been East Asian, and there have been no genetically confirmed Caucasian DSH patients except for 1 Hispanic case (Kono *et al.*, 2013). This discrepancy might be attributable to variability in the severity of skin manifestations associated with background skin color. We speculate that the skin manifestations of Caucasian DSH patients are inconspicuous and difficult to recognize. East Asian skin coloration may make the skin lesions more clearly visible. Furthermore, subtle dyspigmentation might not have been noticed in the context of severe neurological disability in the series of AGS patients (Rice *et al.,* 2012).

In conclusion, we present a DSH patient with compound heterozygous *ADAR1* mutations who was complicated with AGS. This case makes a connection between DSH and AGS that was not, to our knowledge, reported previously. The present case is consistent with the prediction by Rice *et al.* (2012) that a pair of parents with DSH would have a 1 in 4 risk of having a child with AGS. We propose that heterozygous *ADAR1* mutations may cause DSH in East Asian patients while causing no apparent disease in non-East Asian individuals. In contrast, homozygous or compound heterozygous *ADAR1* mutations might cause the combination of AGS and DSH in East Asian patients while causing only AGS in non-East Asian patients. Notably, it may be that, even in a heterozygous state, p.Gly1007Arg can cause both DSH and AGS in East Asian patients but only AGS in non-East Asian patients. However, it is premature to conclude that DSH is non-penetrant in non-East Asians, because few AGS patients have been described and the features of DSH could have been missed in some cases.

Conflicts of Interest

The authors declare no conflicts of interest.

Acknowledgements

We are grateful to the patient's family and the volunteers for providing blood samples.

This work was supported in part by Grants-in-Aid for Scientific Research (C) 24591646 (to MK) from the Ministry of Education, Culture, Sports, Science and Technology of Japan.

References

Herbert A, Wagner S, Nickerson JA (2002) Induction of protein translation by ADAR1 within living cell nuclei is not dependent on RNA editing. *Mol Cell* 10:1235-46.

Kondo T, Suzuki T, Ito S*, et al.* (2008) Dyschromatosis symmetrica hereditaria associated with neurological disorders. *J Dermatol* 35:662-6.

Kono M, Akiyama M, Suganuma M*, et al.* (2013) Dyschromatosis symmetrica hereditaria by ADAR1 mutations and viral encephalitis: a hidden link? *Int J Dermatol* 52:1582-4.

Li CR, Xu XL, Sun XJ*, et al.* (2010) Two new mutations of the ADAR1 gene associated with dyschromatosis symmetrica hereditaria. *Arch Dermatol Res* 302:477-80.

Mannion NM, Greenwood SM, Young R*, et al.* (2014) The RNA-editing enzyme ADAR1 controls innate immune responses to RNA. *Cell Rep* 9:1482-94.

Miyamura Y, Suzuki T, Kono M*, et al.* (2003) Mutations of the RNA-specific adenosine deaminase gene (DSRAD) are involved in dyschromatosis symmetrica hereditaria. *Am J Hum Genet* 73:693-9.

Patrizi A, Manneschi V, Pini A*, et al.* (1994) Dyschromatosis symmetrica hereditaria associated with idiopathic torsion dystonia. A case report. *Acta Derm Venereol* 74:135-7.

Rice GI, Kasher PR, Forte GM*, et al.* (2012) Mutations in ADAR1 cause Aicardi-Goutieres syndrome associated with a type I interferon signature. *Nat Genet* 44:1243-8.

Suzuki N, Suzuki T, Inagaki K*, et al.* (2007) Ten novel mutations of the ADAR1 gene in Japanese patients with dyschromatosis symmetrica hereditaria. *J Invest Dermatol* 127:309-11.

Tojo K, Sekijima Y, Suzuki T*, et al.* (2006) Dystonia, mental deterioration, and dyschromatosis symmetrica hereditaria in a family with ADAR1 mutation. *Mov Disord* 21:1510-3.

Figure legends

Figure 1. Pedigree, clinical features of the proband with both DSH and AGS and of her mother with only DSH, and causative ADAR1 mutations. (a) The pedigree of the proband's family. Closed circles and squares indicate individuals with DSH skin manifestations. The proband (*) has both DSH skin lesions and AGS neurological manifestations. The skin of her father was not examined (?). (b-e) Skin manifestations of the proband. A mixture of 5-mm hyper- and hypo-pigmented macules on the trunk (b), the arm (c) and the leg (d). Freckle-like macules are observed on the face (e). (f) Skin lesions are recognized in the mother, but are very faint. (g, h) Brain CT images of the proband at the ages of 4 months (g) and 17 months (h). (i) The mutation c.1600C>T was identified by sequence analysis of exons 2 of *ADAR1*. (j) The mutation c.3444-1G>A (IVS14-1G>A) was identified by sequence analysis of the boundary between intron 14 and exon 15 of *ADAR1*. (k) Agarose gel electrophoresis of RT-PCR products derived from the boundary between exons 14 and 15 in *ADAR1*. The RT-PCR product from the patient's father shows a 519-bp band (a normally spliced fragment) and a 555-bp band (an aberrantly spliced fragment), whereas the RT-PCR product from the patient shows only a

555-bp band (an aberrantly spliced fragment) derived from the paternal mutant allele with c.3444-1G>A (IVS14-1G>A). The RT-PCR product from the patient does not demonstrate a 519-bp band theoretically derived from the maternal mutant allele carrying the mutation c.1600C>T. Thus, it is thought that the allele with c.1600C>T underwent NMD. The mother has only a 519-bp band derived from the wild-type allele. (l) Direct sequencing of RT-PCR products from the patient and her father reveals a 36-bp nucleotide insertion between exon 14 and exon 15. The paternal mutation c.3444-1G>A results in aberrant splicing and the insertion of 36 bp between exon 14 and exon 15, i.e. p.1148_1149insSQVNNECFCFSK in the deaminase domain. (m) The scheme of the domain structure of ADAR1 and two mutations found in the patient's family.

Figure 2. RNA editing activity analysis of mutant *ADAR1* p150 isoforms causative of DSH and ADS. (a) Structure of the RNA editing reporter construct. When the UAG at a double-stranded RNA site upstream of the luciferase gene is converted by ADAR1 into UIG by A-I editing, the stop is canceled and the luciferase gene is translated. Thereby, quantification of the editing efficiency is possible. (b) The A-I editing efficiency of cos7

cells transfected with DSH-causative or AGS-causative mutant p150 isoforms.

Concerning the 3 AGS-causative mutations, only mutant plasmids were transfected into cos7 cells and the A-I editing efficiencies of the transfectants were evaluated. This system mimics the state of patients with homozygous *ADAR1* mutations. As for the 3 DSH-causative mutations and pGly1007Arg (*) causative of DSH with neurological symptoms, both mutant plasmids and wild-type plasmids (half and half) were transfected into cos7 cells. This system mimics the state of patients with heterozygous *ADAR1* mutations.

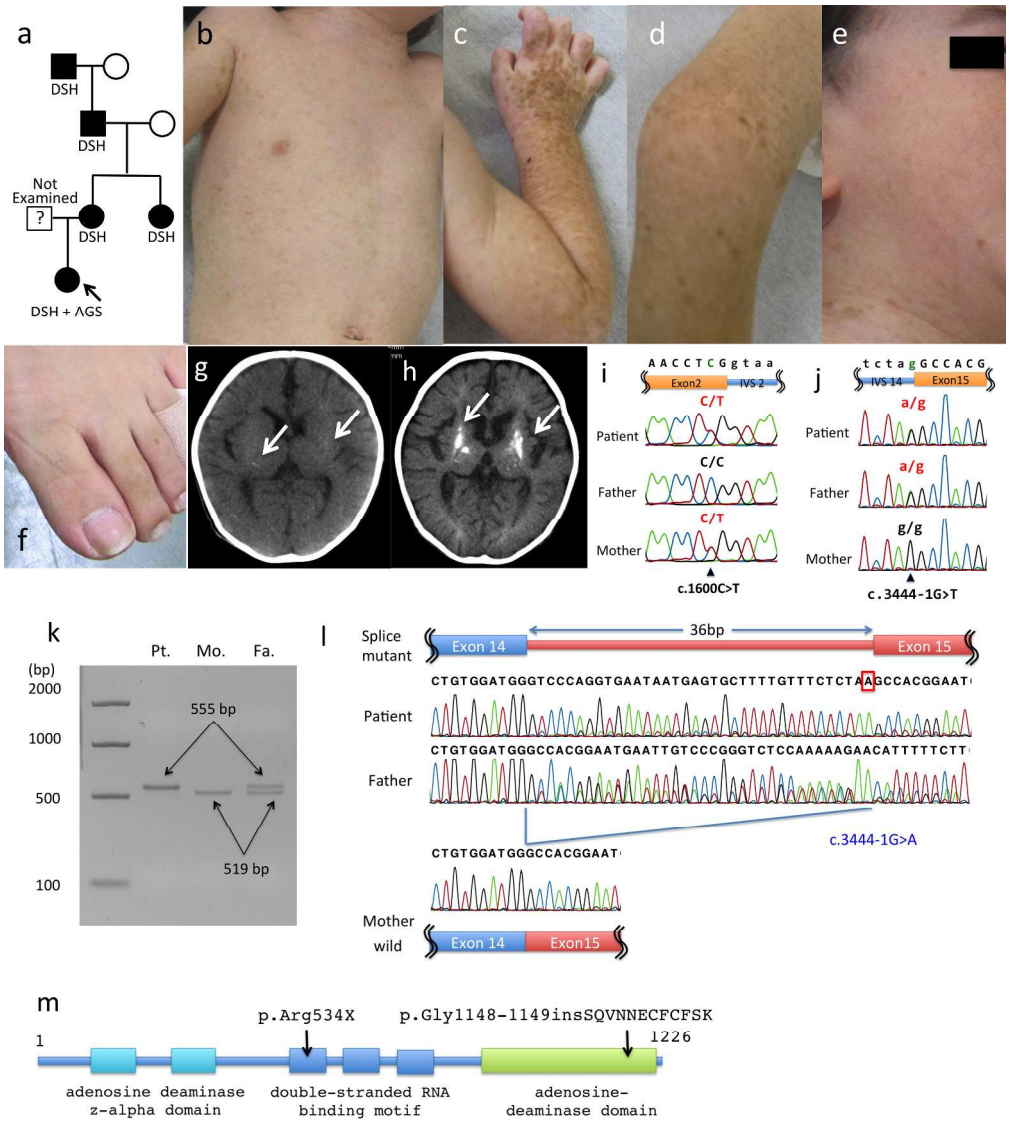

Figure 1. Pedigree, clinical features of the proband with both DSH and AGS and of her mother with only DSH, and causative ADAR1 mutations. (a) The pedigree of the proband's family. Closed circles and squares indicate individuals with DSH skin manifestations. The proband (*) has both DSH skin lesions and AGS neurological manifestations. The skin of her father was not examined (?). (b-e) Skin manifestations of the proband. A mixture of 5-mm hyper- and hypo-pigmented macules on the trunk (b), the arm (c) and the leg (d). Freckle-like macules are observed on the face (e). (f) Skin lesions are recognized in the mother, but are very faint. (g, h) Brain CT images of the proband at the ages of 4 months (g) and 17 months (h). (i) The mutation c.1600C>T was identified by sequence analysis of exons 2 of ADAR1. (j) The mutation c.3444-1G>A (IVS14-1G>A) was identified by sequence analysis of the boundary between intron 14 and exon 15 of ADAR1. (k) Agarose gel electrophoresis of RT-PCR products derived from the boundary between exons 14 and 15 in ADAR1. The RT-PCR product from the patient's father shows a 519-bp band (a normally spliced fragment) and a 555-bp band (an aberrantly spliced fragment), whereas the RT-PCR product from the patient shows only a 555-bp band (an aberrantly spliced fragment) derived from the paternal mutant allele with c.3444-1G>A (IVS14-1G>A). The RT-PCR product from the patient does not demonstrate a 519-bp band theoretically derived from the maternal mutant allele carrying the mutation c.1600C>T. Thus, it is thought that the allele with c.1600C>T underwent NMD. The mother has only a 519-bp band derived from

the wild-type allele. (l) Direct sequencing of RT-PCR products from the patient and her father reveals a 36-bp nucleotide insertion between exon 14 and exon 15. The paternal mutation c.3444-1G>A results in aberrant splicing and the insertion of 36 bp between exon 14 and exon 15, i.e. p.1148_1149insSQVNNECFCFSK in the deaminase domain. (m) The scheme of the domain structure of ADAR1 and two mutations found in the patient's family.
243x275mm (300 x 300 DPI)

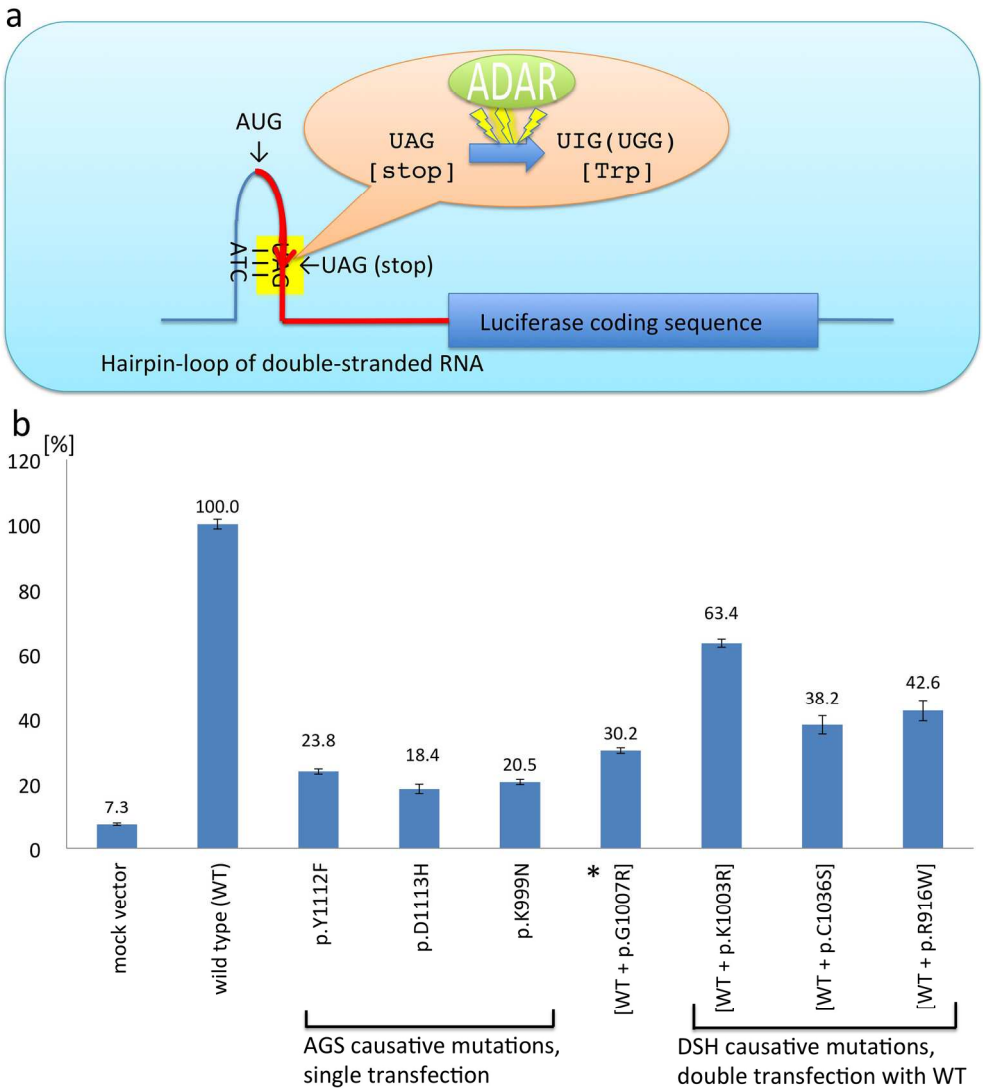

Figure 2. RNA editing activity analysis of mutant ADAR1 p150 isoforms causative of DSH and ADS. (a) Structure of the RNA editing reporter construct. When the UAG at a double-stranded RNA site upstream of the luciferase gene is converted by ADAR1 into UIG by A-I editing, the stop is canceled and the luciferase gene is translated. Thereby, quantification of the editing efficiency is possible. (b) The A-I editing efficiency of cos7 cells transfected with DSH-causative or AGS-causative mutant p150 isoforms. Concerning the 3 AGS-causative mutations, only mutant plasmids were transfected into cos7 cells and the A-I editing efficiencies of the transfectants were evaluated. This system mimics the state of patients with homozygous ADAR1 mutations. As for the 3 DSH-causative mutations and pGly1007Arg (*) causative of DSH with neurological symptoms, both mutant plasmids and wild-type plasmids (half and half) were transfected into cos7 cells. This system mimics the state of patients with heterozygous ADAR1 mutations.
199x223mm (300 x 300 DPI)