

PUBLISHED BY

INTECH

open science | open minds

World's largest Science,
Technology & Medicine
Open Access book publisher



2,850+
OPEN ACCESS BOOKS



97,000+
INTERNATIONAL
AUTHORS AND EDITORS



91+ MILLION
DOWNLOADS



BOOKS
DELIVERED TO
151 COUNTRIES

AUTHORS AMONG
TOP 1%
MOST CITED SCIENTIST



12.2%
AUTHORS AND EDITORS
FROM TOP 500 UNIVERSITIES



Selection of our books indexed in the
Book Citation Index in Web of Science™
Core Collection (BKCI)

Chapter from the book *CT Scanning - Techniques and Applications*

Downloaded from: <http://www.intechopen.com/books/ct-scanning-techniques-and-applications>

Interested in publishing with InTechOpen?
Contact us at book.department@intechopen.com

Three-Dimensional CT Analysis of Congenital Scoliosis and Kyphosis: A New Classification

Shiro Imagama¹, Noriaki Kawakami² and Naoki Ishiguro¹

¹*Department of Orthopaedic Surgery,*

Nagoya University Graduate School of Medicine

²*Department of Orthopaedic Surgery, Meijo Hospital
Japan*

1. Introduction

With advances in spine surgery, congenital spine deformity can now be treated with corrective fusion and osteotomy, even in young children. In these patients, the spine has various complications of vertebral anomalies and congenital fusion. A successful and safe outcome of corrective surgery requires evaluation by imaging preoperatively. Congenital spinal anomaly has conventionally been evaluated on plain radiographs using the classification described by Winter et al. in 1973 (Winter et al. 1973) as formation failure, segmentation failure, and mixed type (Table 1).

1. Failure of formation	Complete failure of formation (hemivertebra, butterfly vertebra)
	Partial failure of formation (wedged vertebra)
2. Failure of segmentation	Unilateral failure of segmentation (unilateral unsegmented bar)
	bilateral failure of segmentation (block vertebra)
3. Miscellaneous	Mixed type

Table 1. Winter's classification of congenital scoliosis on plain radiographs, as first described by Winter et al. in 1973 (partially modified for simplicity)

It is now clear that the complicated anomalies and the relationship between anterior and posterior components cannot be fully evaluated on plain radiographs only. We often encounter intraoperative findings that differ from preoperative findings on plain radiographs. Therefore, improved imaging evaluation of congenital anomalies is important to avoid difficulties during surgery. Preoperative 3-dimensional CT evaluation (3DCT) is very useful in this respect (Newton et al. 2002, Nakajima et al. 2007) since it allows clearer

observation of morphology and fusion compared to plain radiographs (Fig. 1). Based on evaluation of many cases with 3DCT, we have established a new classification of congenital spine anomaly (Kawakami et al. 2009). In this chapter, we introduce the utility of 3DCT and describe variations of congenital deformity detected by 3DCT, based on Winter's classification of deformity.

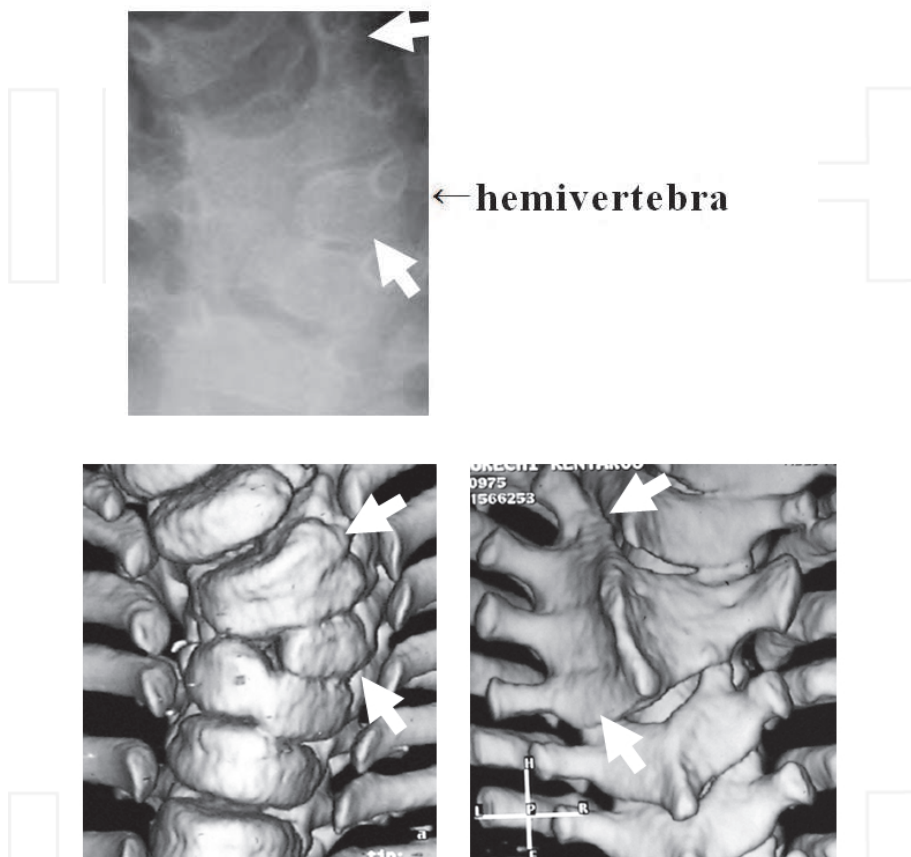


Fig. 1. Congenital scoliosis of a hemivertebra with posterior fusion. A hemivertebra (arrow) on the upper side may be missed and without 3DCT it can be difficult to evaluate the relationships of morphologic changes with anterior and posterior bony fusion.

2. Three-dimensional analysis of congenital anomaly

2.1 Formation failure

2.1.1 3DCT evaluation of morphology

Formation failures in Winter's classification are defined by morphology, and include a hemivertebra with one lateral pedicle, a butterfly vertebra, and a wedge vertebra with a bipedicle. However, evaluation of the morphology of the anterior component can be

difficult and evaluation of posterior components is often particularly difficult on plain radiographs. In contrast, 3DCT effectively reveals the morphology of the anterior and posterior components of the spine, and these images show that there are various patterns of posterior components.

First, we show a fully segmented hemivertebra and fully segmented hemilamina (Fig. 2). A plain radiograph shows the morphological change of the vertebra and suspected hemivertebra because of scoliosis, but does not reveal the details, whereas these are shown clearly on 3DCT. This type is a half structure of normal anterior and posterior components, which may be understood easily.

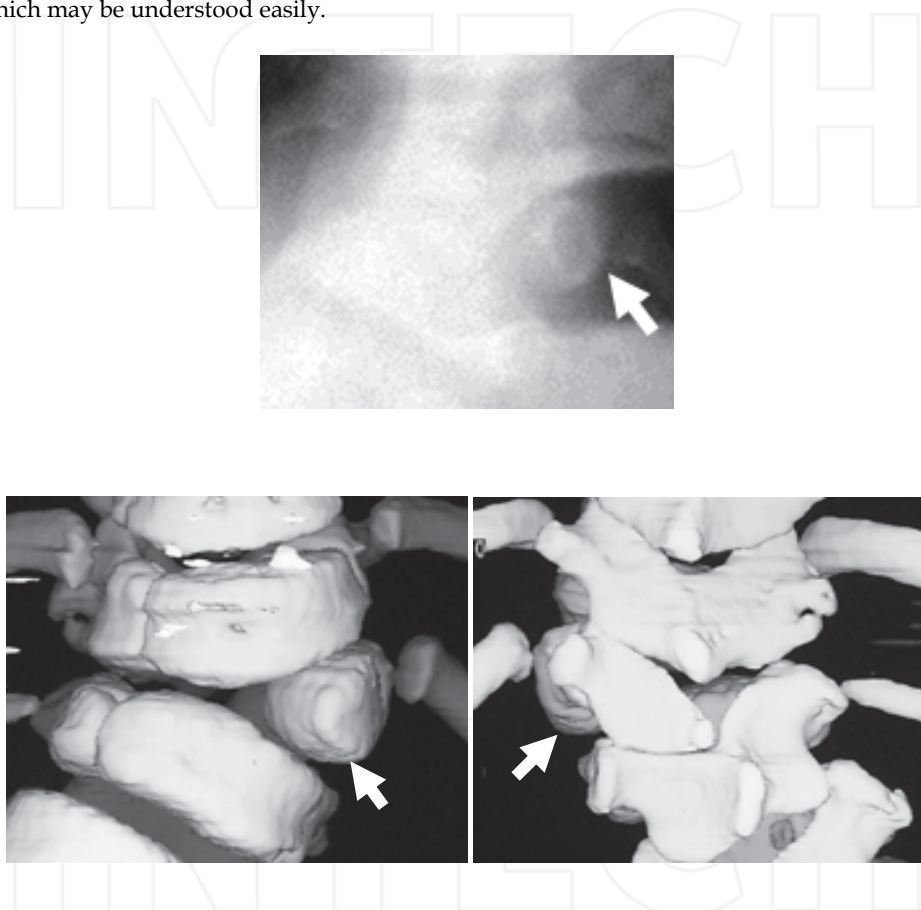


Fig. 2. **Fully-segmented hemivertebra with hemilamina.** The 3DCT images show a combination of a hemivertebra (anterior) and hemilamina (posterior) without bony fusion (arrow). In contrast, the plain radiograph shows no details of the morphology of the anterior and posterior components.

There are also other types of posterior components with a hemivertebra, including fully segmented bilamina (Fig. 3) and spina bifida (Fig. 4).

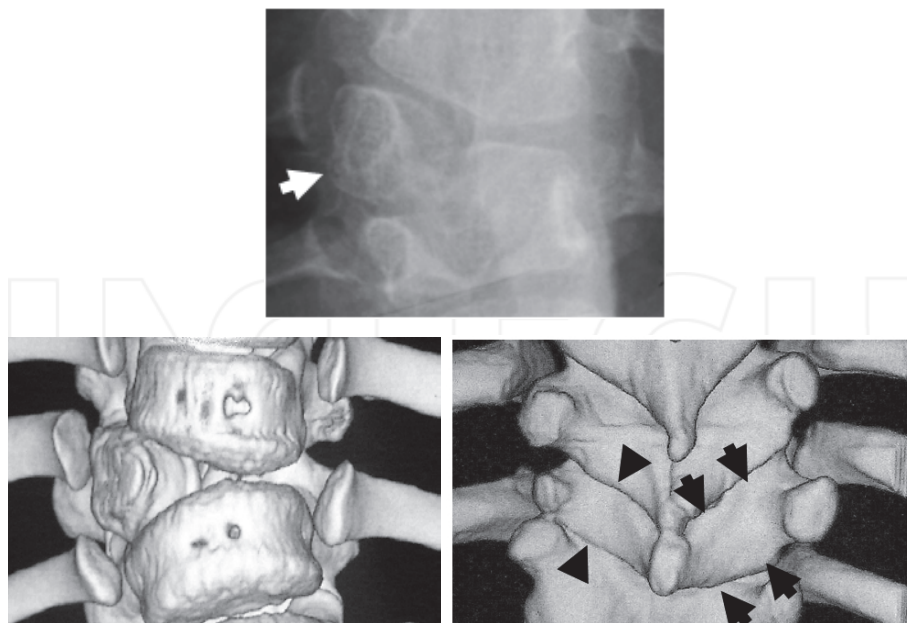


Fig. 3. **Fully-segmented hemivertebra and fully segmented bilamina.** A plain radiograph shows a hemivertebra (white arrow), but does not show the posterior components. 3DCT clearly showed bilamina that differed from the case in Fig. 2 (black arrow: same side of hemivertebra, arrowhead: opposite side of hemivertebra).

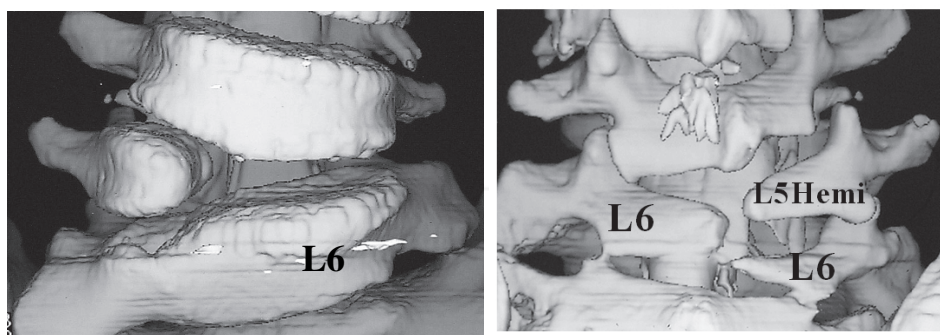
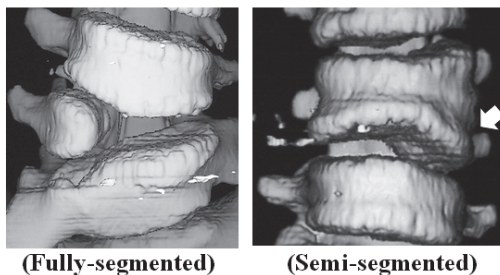


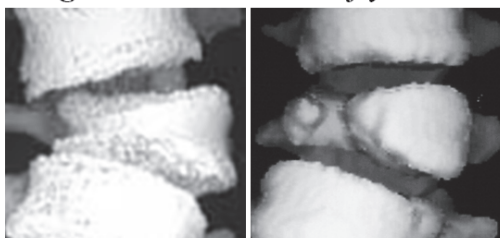
Fig. 4. **Fully-segmented hemivertebra and spina bifida.** The spina bifida type has a characteristic morphology of the posterior component. This type is located around the sacrum in most cases.

We show a summary of the combination of morphology of anterior and posterior components in formation failure in Table 2. For butterfly vertebra and lateral wedged vertebra, it is also likely that the morphology of the posterior component may vary, as for hemivertebra. There are many possible combinations of formation failures in both anterior and posterior components based on evaluation by 3DCT (Fig. 5).

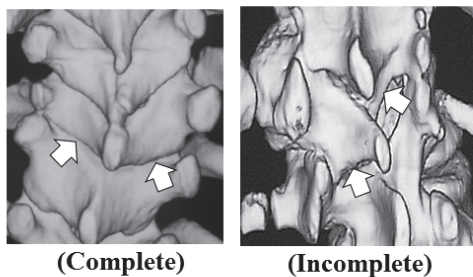
Hemivertebra



Wedged vertebra *Butterfly vertebra*



Bi-lamina



Hemilamina

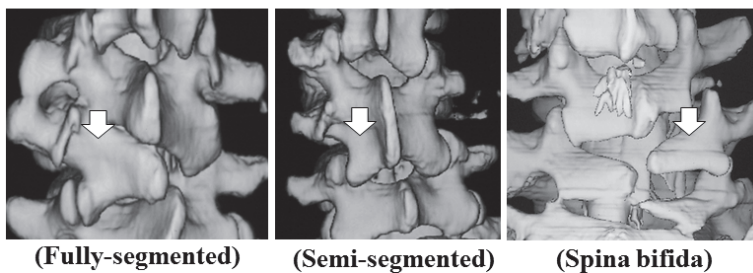


Fig. 5. Typical variation of type of formation failure in anterior and posterior components based on 3DCT. Arrows indicate formation failures.

Anterior component	Posterior component
Hemivertebra (hemi-pedicle)	Fully segmented hemilamina
	Semisegmented hemilamina
	Spina bifida
	Bilamina (complete or incomplete)
Butterfly vertebra (bipedicle)	Wedged lamina
	Spina bifida
Lateral wedged vertebra (bipedicle)	Wedged lamina

Table 2. Combination of morphology of anterior and posterior components in formation failure.

Segmentation failure may also occur in anterior and/or posterior components (semisegmented hemivertebra, semisegmented hemilamina) (Fig. 5) and solitary malformation and multiple anomalies must also be taken into account (Kawakami et al. 2009).

2.1.2 Anteroposterior (AP) unison anomaly and discordant anomaly

Malformed vertebrae in the solitary group and the simple type in the multiple malformation group may be explained by formation failure of vertebral components one by one. The usual pattern can be referred to as “an anteroposterior unison anomaly” (Nakajima et al. 2007). However, 3DCT findings indicate that posterior components are sometimes mismatched with anterior components. This malformation pattern can be referred to as “anteroposterior discordant anomaly” (Fig. 6). It also appears that this type is due to formation failure, segmentation failure, and mixed type (described below).

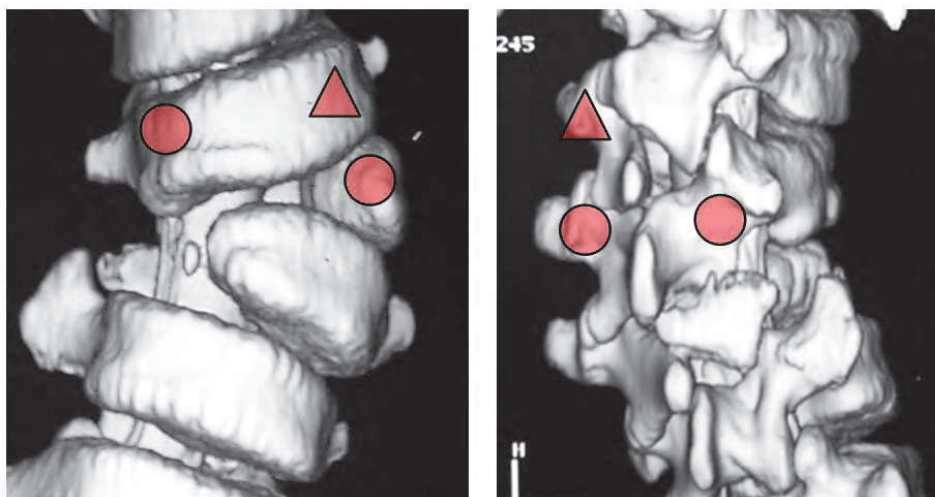


Fig. 6. Anteroposterior (AP) discordant anomaly. Left hemivertebra composed of the same lamina with the right upper segment at posterior. The anterior component is not matched to a posterior component (AP discordant anomaly).

2.2 Segmentation failure

Bony fusion (segmentation failure) and formation failure are often seen in 3DCT, with more cases than expected having a mixed type in Winter’s classification (Fig. 7). The semisegmented hemivertebra and semisegmented hemilamina shown in Fig. 5 can be evaluated based on unsegmented morphological changes. However, other types of bony fusion (i.e. segmentation failure) can be identified by 3DCT evaluation. Therefore, we introduce segmentation failure in this chapter. Since evaluation of all cases of segmentation failure as one group is complicated, we examined these cases in categories of segmentation failure alone (without formation failure) (Imagama et al. 2004) and formation failure with segmentation failure (mixed type in Winter’s classification) (Imagama et al. 2005).

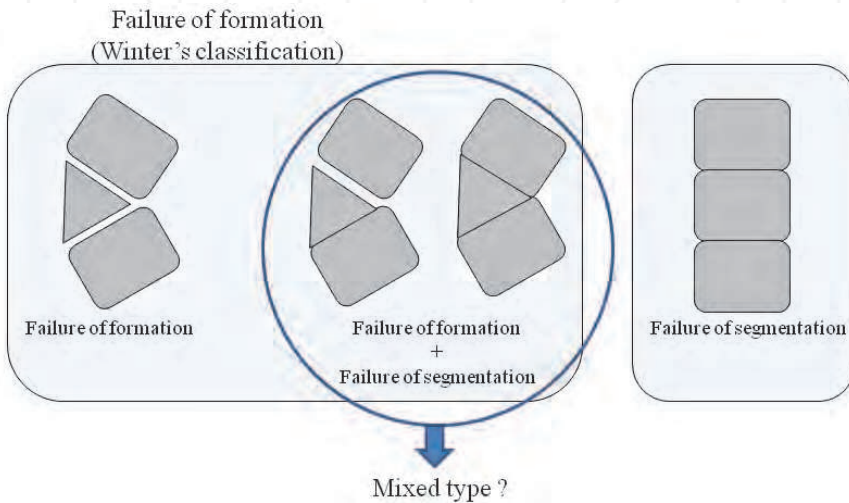


Fig. 7. **Ambiguous border of segmentation failure.** Failure of formation in Winter’s classification includes fully segmented, semisegmented, and nonsegmented hemivertebrae. However, semisegmented and nonsegmented vertebrae have the same characteristics of segmentation failure as a block vertebra with segmentation failure (Kawakami et al. 2009). Therefore, failure of formation in Winter’s classification also includes mixed type.

2.2.1 Segmentation failure (without formation failure)

3D-CT images for 25 patients with congenital scoliosis (failure of segmentation) were examined to determine the fusion abnormalities of the vertebral bodies and those of the laminae, pedicles, ribs and transverse processes. The vertebral body was defined as the anterior component, the pedicle, transverse process and rib as the lateral components, and the lamina and spinous process as the posterior components. We classified the 25 cases into three groups and investigated the posterior features in each group. One group had anterior fusion only (group A: 8 cases), the second had anterolateral fusion (group AL: 14 cases), and the third had posterior fusion only (group P: 3 cases) on 3DCT. In this series, we did not find any cases of lateral fusion only. In group A, all vertebral bodies had a posterior component with which they originally belonged (i.e. unison) (Fig. 8). All cases had normal posterior structures that were fully segmented.

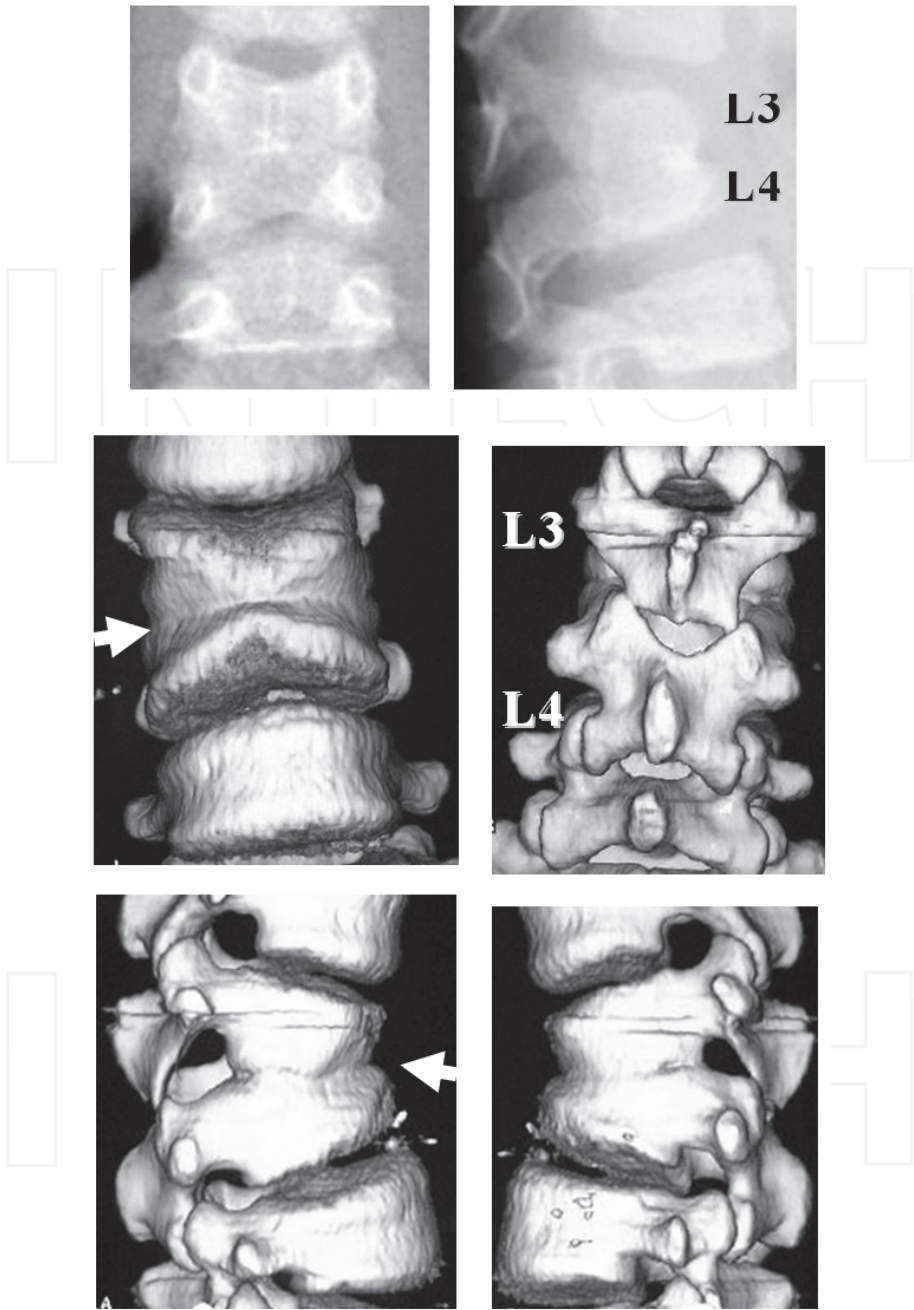


Fig. 8. **Segmentation failure only (group A)**. These cases had anterior fusion (arrow) with normal posterior components.

In group AL, all cases had congenital fusion posterior components. In all cases in group AL, the vertebral bodies paired with posterior components with which they originally belonged (i.e. unison) (Fig. 9).

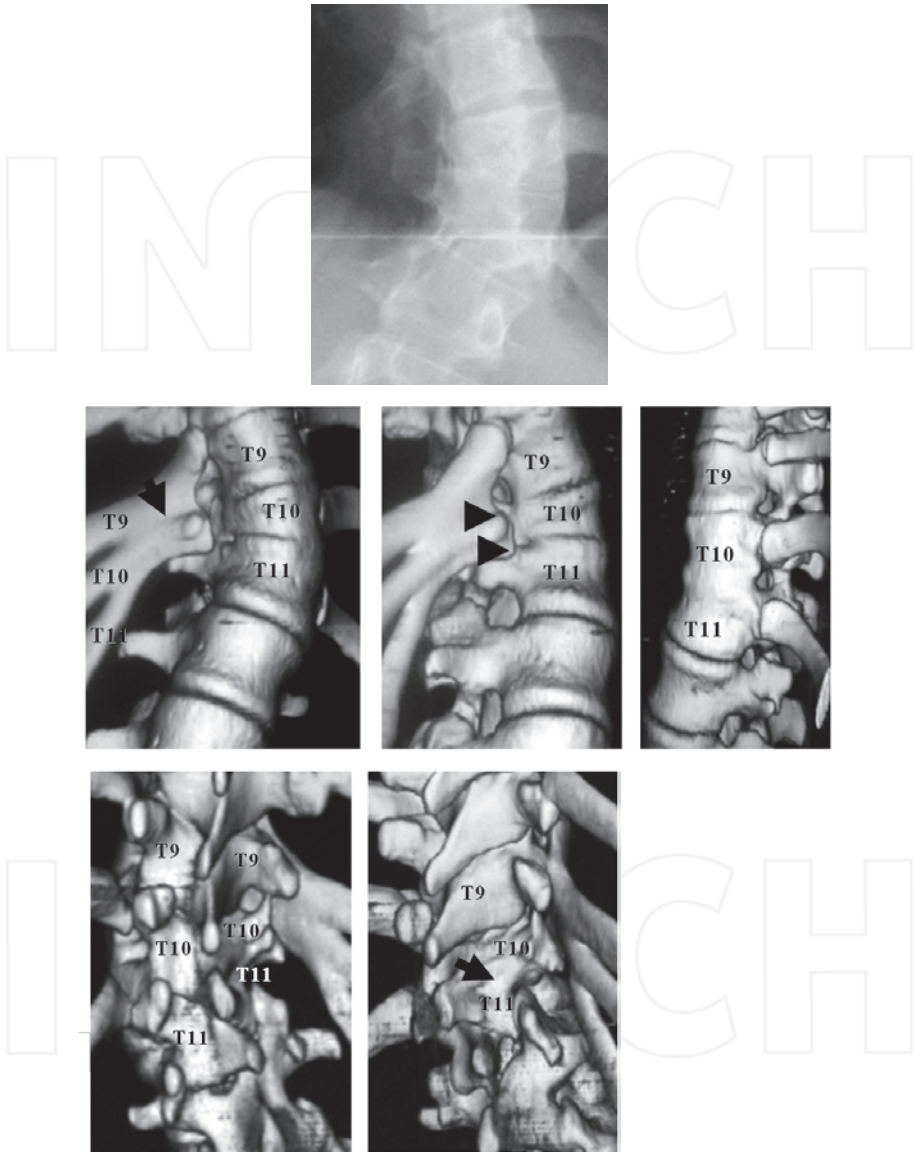


Fig. 9. **Segmentation failure only (group AL).** In this case, anterior, lateral (pedicle, transverse process and ribs) (arrowhead) and posterior (arrow) components were fused only on the left side, with no fusion on the right side.

In group P, posterior components (lamina and spinous process) were fused. Two cases showed unison anomalies (Fig. 10) and one had a discordant anomaly in which the vertebral bodies made another pair with posterior components with which they did not originally belong (Fig. 11). We also accidentally noticed that there may be a type of hemilamina only without another anomaly, as shown in Fig. 11.

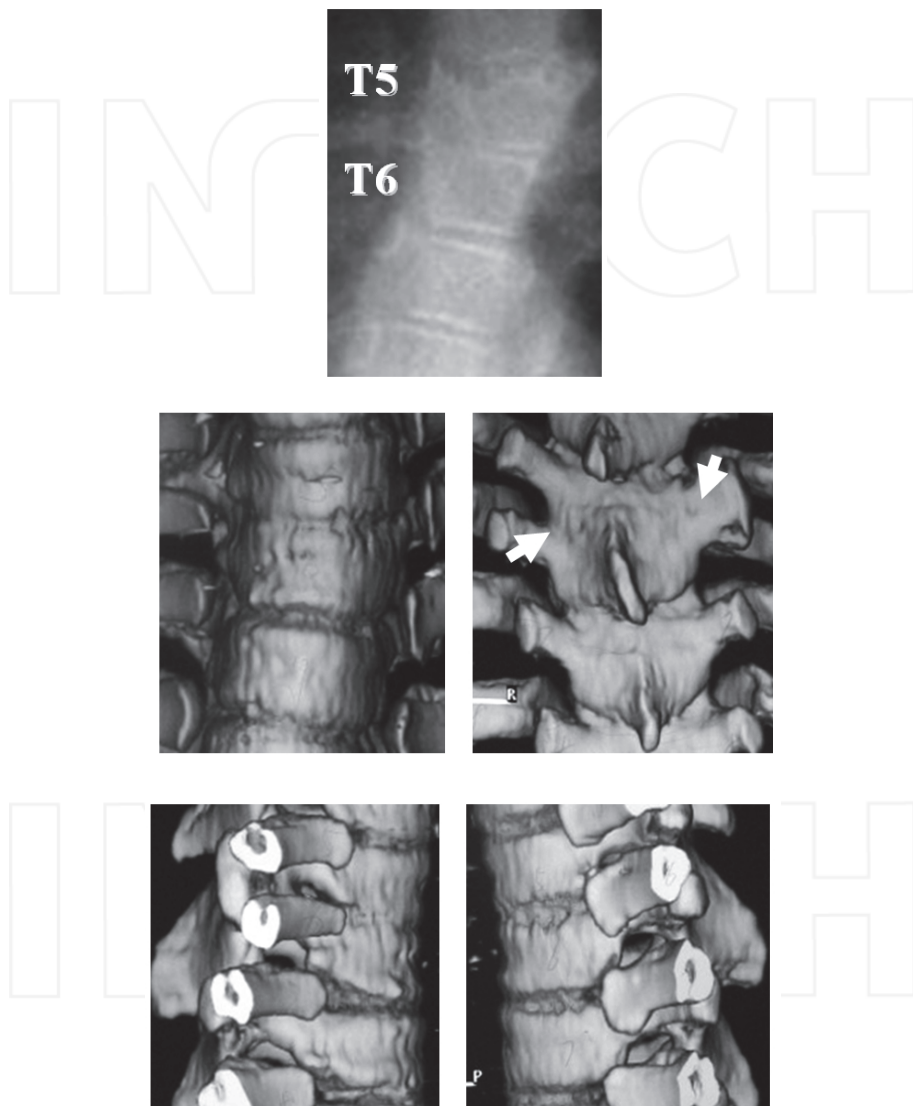


Fig. 10. **Posterior segmentation failure (group P: AP unison type).** This case showed no anterior and lateral fusion, but laminae and spinous processes at T5 and T6 were fused (arrow) with the corresponding anterior components.

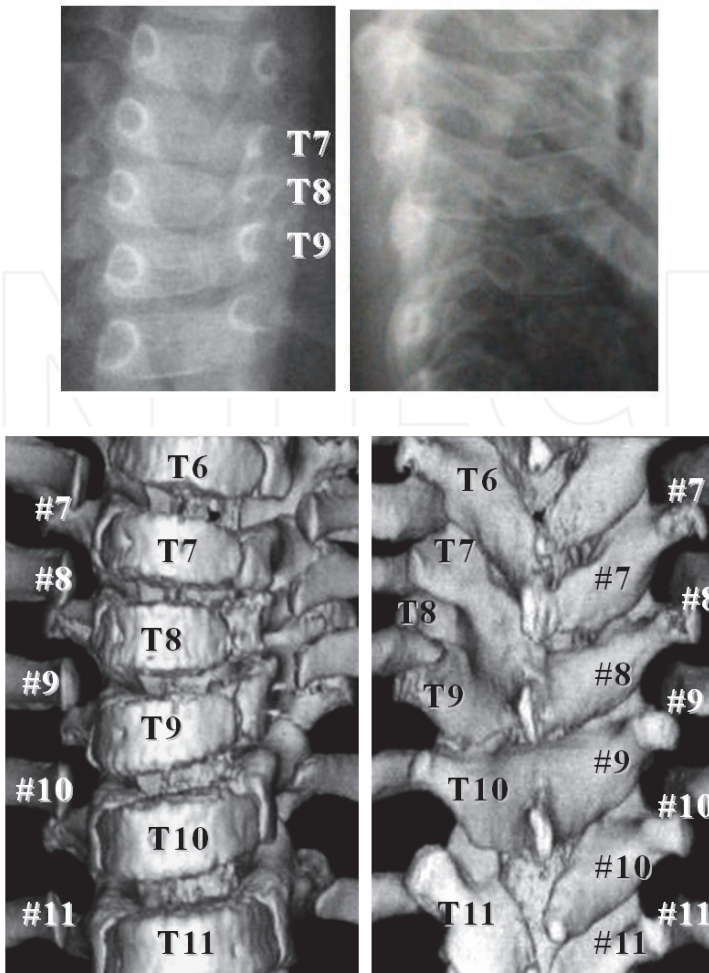


Fig. 11. **Posterior segmentation failure (group P: AP discordant type)**. This case showed no anterior and lateral fusion, but laminae and spinous processes at T7 to T9 were fused. The posterior structure on the right side did not correspond to the components on the left side, which can be viewed as anterior components.

In evaluation of segmentation failure alone on 3DCT, the fusion type was divided into three categories: fused anterior only (group A), fused anterior, lateral and posterior components on the same side (group AL), and posterior fusion only (group P). All cases in group AL had posterior segmentation failure, and thus may be an ALP group, with group AL requiring further division. We speculated that the lateral component (the pedicle) may be the key to extending the fusion to the anterior and posterior parts in categories of segmentation failure alone (Fig.12). However, we do not have sufficient cases to draw this conclusion and further studies are needed. We also note that discordant anomalies were seen only in group P in this series of segmentation failure alone without vertebral formation failure.

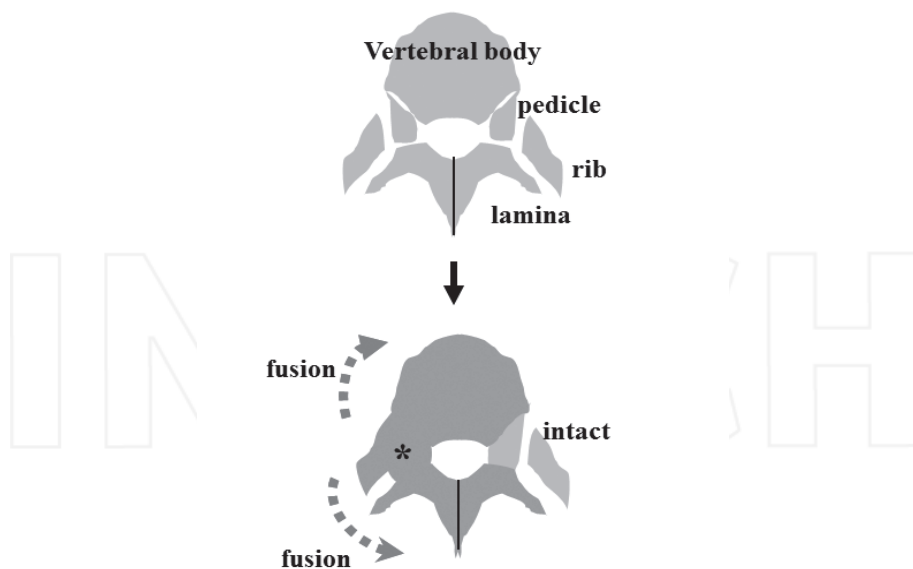


Fig. 12. **Proposed process of segmentation failure.** There were no cases of anterior and lateral segmentation failure, anterior and posterior segmentation failure, or lateral and posterior segmentation failure at the same side. Conversely, all cases with lateral fusion had anterior, lateral, and posterior fusion at the same side. Therefore, we speculate that the pedicle (asterisk) is the origin of the fusion in the cases of segmentation failure alone.

2.2.2 Formation failure with segmentation failure: Mixed type in Winter's classification

Next, we evaluated the mixed type in Winter's Classification. In this category, the combination of morphological anomalies and fusion varied and were the most complicated. We first divided the cases into hemivertebra or butterfly vertebra, and examined the relationship of fusion between the abnormal vertebral body and upper and lower adjacent segments. Here, we describe the results of this study (Imagama et al. 2005).

We examined 40 patients with congenital scoliosis (failure of formation) by 3D-CT to determine the morphological abnormalities of the vertebral bodies and the laminae, pedicles, ribs, and transverse processes. We excluded cases with segmentation failure only, which has been described above. We investigated the anterior, lateral and posterior features and evaluated the type of vertebral anomaly, incarcerated or nonincarcerated hemivertebra, and AP unison anomaly and AP discordant anomaly.

Twenty-seven of the cases had hemivertebra and 13 had butterfly vertebrae. There were fifteen incarcerated vertebra. As expected, the morphological features of the deformed vertebra and the adjacent vertebra had many variations of fusion. Anterior fusion only was present in 12 cases (group A), anteroposterior fusion was found in 16 cases (group AP), anterior, lateral, and posterior fusion was present in 6 cases (group ALP), and posterior fusion only was found in 6 cases (group P). There were no cases with lateral fusion only (group L in the classification), similarly to the evaluation of segmentation failure only. Many

cases showed anterior and posterior components combined and fused with the adjacent components, which differed from the evaluation of segmentation failure alone (Fig. 13, Table 3). Plain radiographs and 3DCT images for each group are shown in Figs. 14-17.

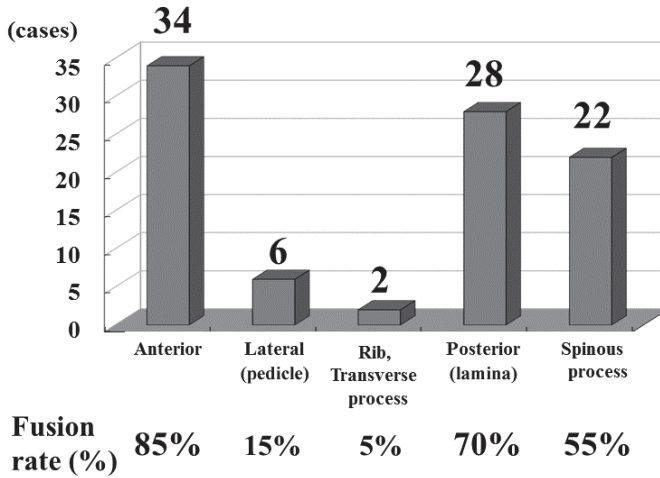


Fig. 13. Fusion rate for each component in the mixed type. Among cases with hemivertebra and/or butterfly vertebra, fusion was common for anterior and posterior components and seemed to be less frequent for lateral components.

Vertebral formation failure	n	Segmentation group			
		A (n=12)	AP (n=16)	ALP (n=6)	P (n=6)
Hemivertebra	27	8	13	3	3
Hemivertebra+ Butterfly vertebra	10	2	2	3	3
Butterfly vertebra	3	2	1		

Table 3. Classification of segmentation based on vertebral failure of formation

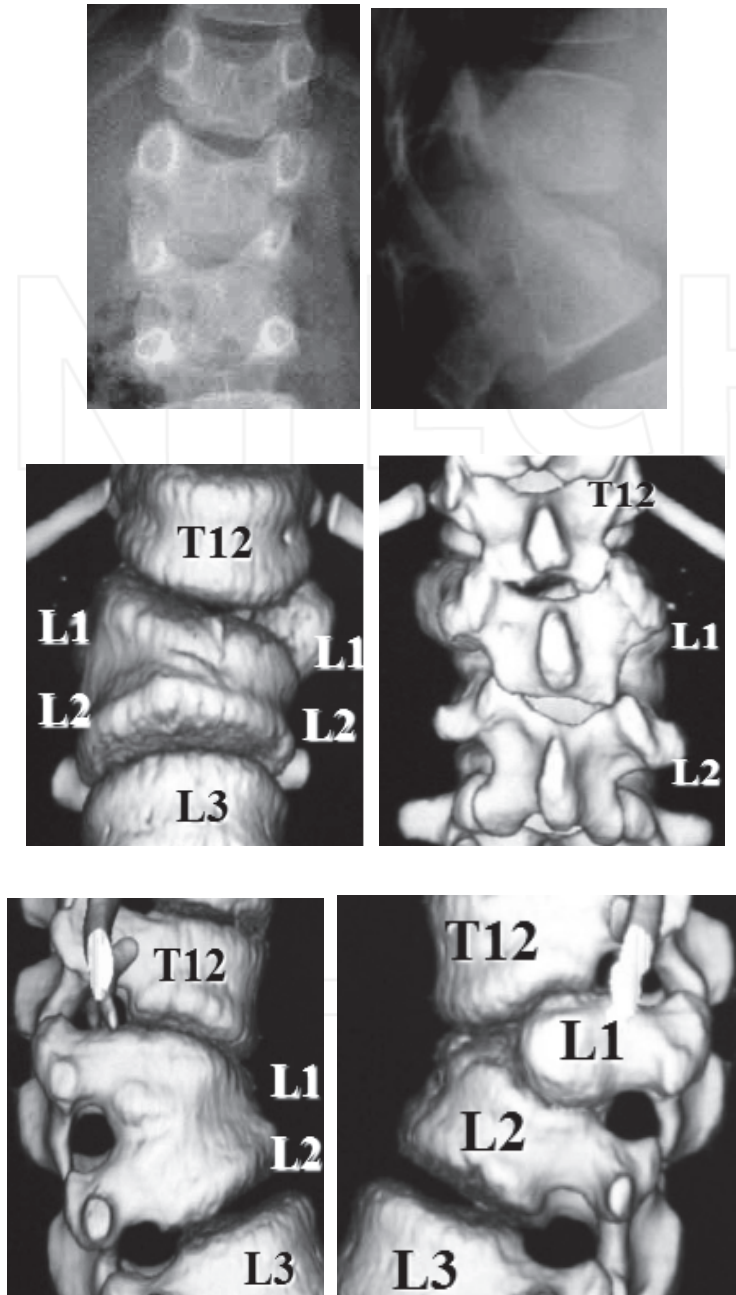


Fig. 14. **Images for group A.** This case has an L1 butterfly vertebra and only the right side of the vertebra was fused.

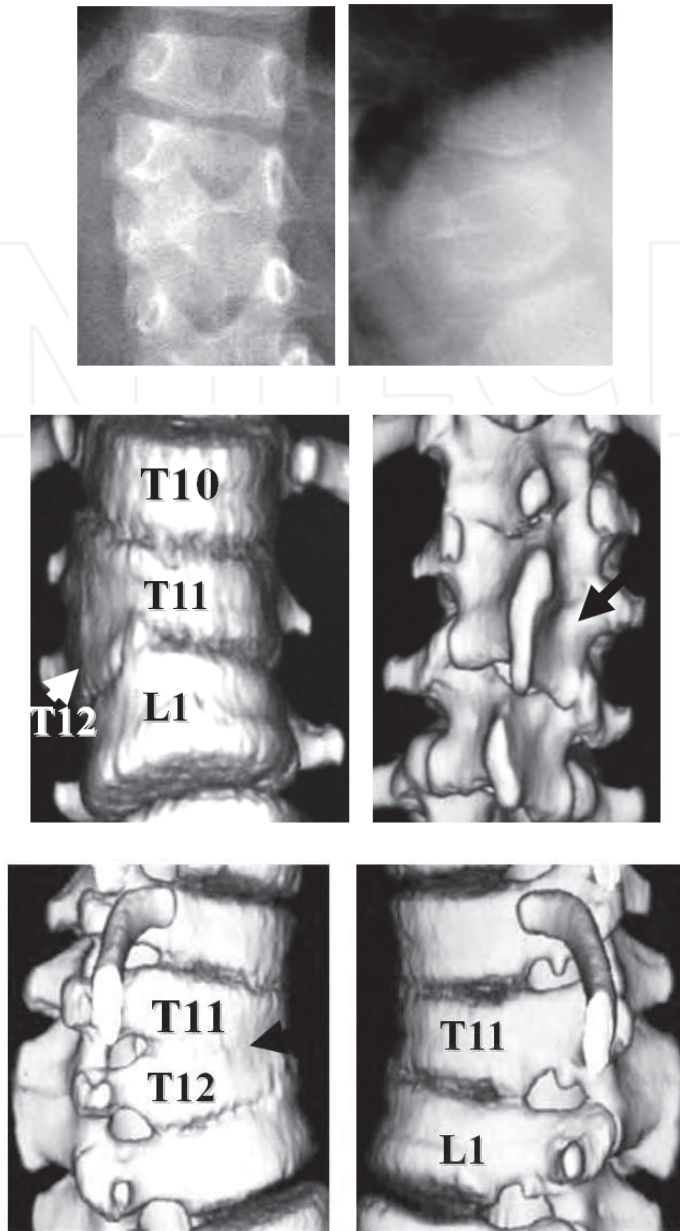


Fig. 15. **Images for group AP.** This case has a left T12 hemivertebra and anterior and posterior components were fused (arrow), with no lateral fusion. There was no incarceration hemivertebra.

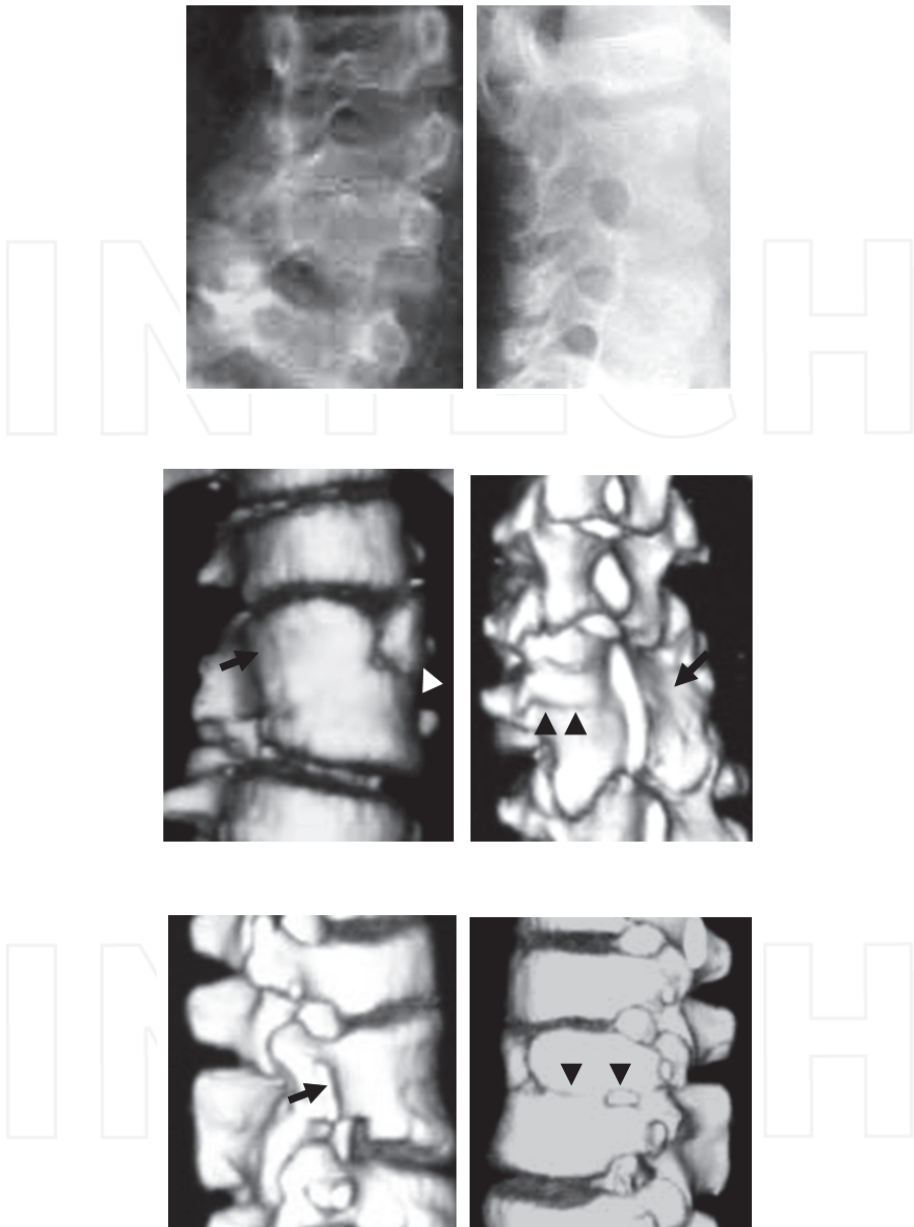


Fig. 16. **Images for group ALP.** This case has an L2 butterfly vertebra and right anterior, lateral and posterior components were fused (arrow). However, there was no complete fusion on the left side (arrowhead).

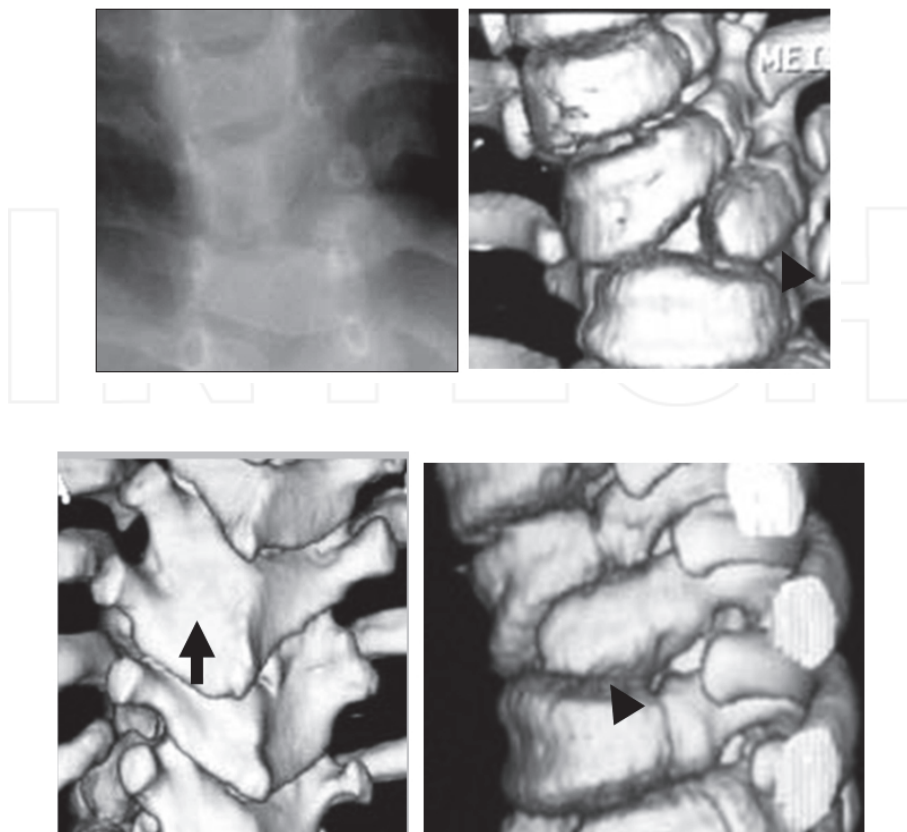


Fig. 17. **Images for group P.** This case has a left T9 hemivertebra and posterior fusion only (arrow), without anterior and lateral fusion (arrowhead). Incarceration was also seen at the T8 vertebra.

The above classification demonstrates the various types of formation failure with segmentation failure. There was no discordant type in the mixed type, but this may be because segmentation failure prevented evaluation of the correspondence between anterior and posterior components. Instead, we found an AP discordant *segmentation* anomaly (Fig. 18). This case had an anterior component fused with the lower site, but the laminae fused with the upper opposite adjacent laminae.

In this evaluation, there was no clear trend for segmentation failure or formation failure, including incarceration. However, various types of formation and segmentation failure were found in the study, and this is useful for performance of further research and for reference in preparing a surgical plan.

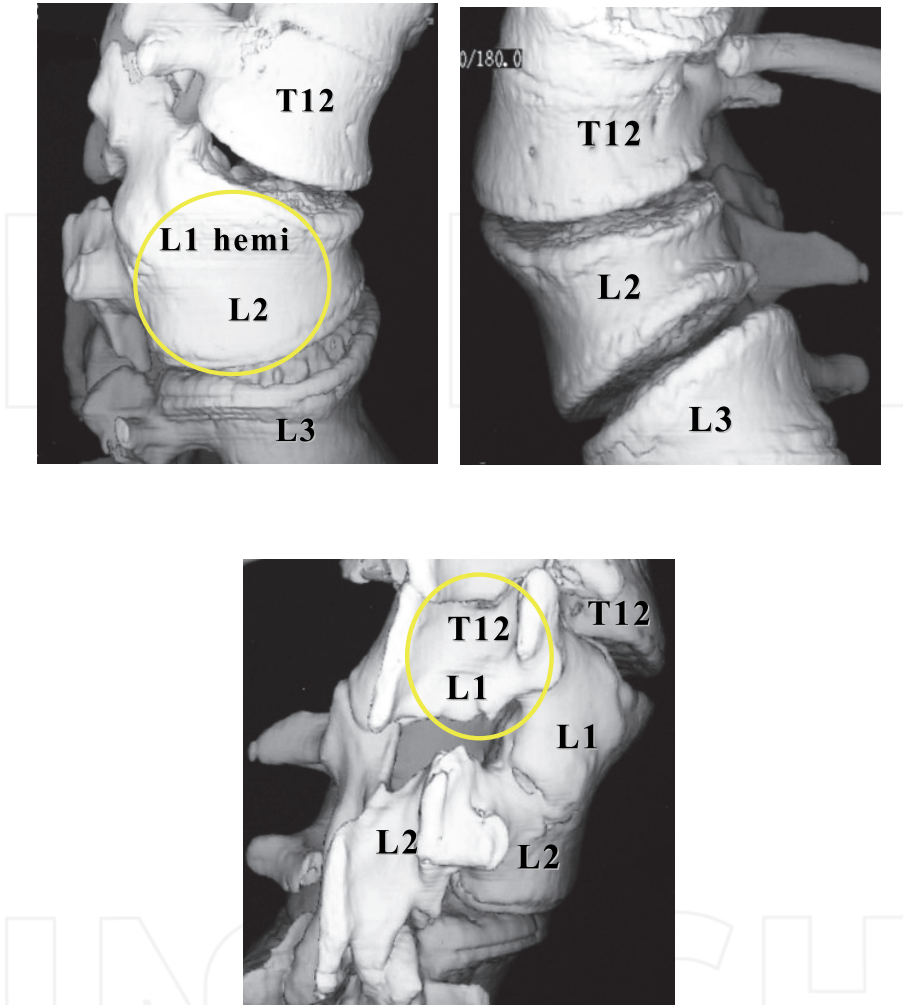


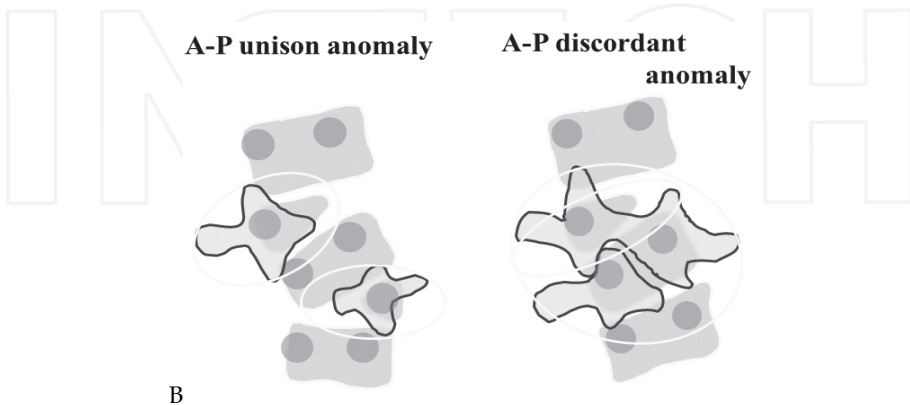
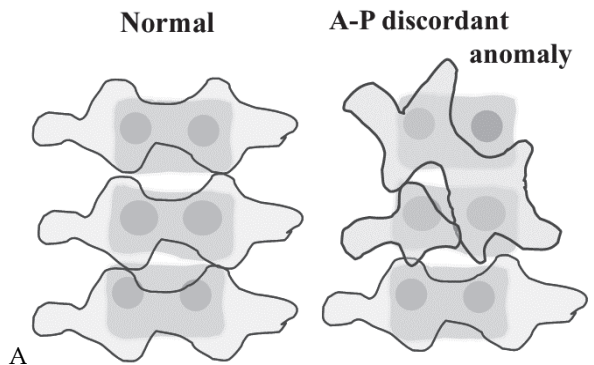
Fig. 18. **AP discordant segmentation anomaly.** This case has a right L1 hemivertebra and anterior fusion with L2. However, on the posterior side the L1 lamina was fused with T12, rather than L2.

2.3 Summary of anteroposterior unison anomaly and discordant anomaly

We first recognized the mismatch of anterior and posterior components and named this “AP discordant anomaly”. However, this may be somewhat complicated to understand, and therefore we describe the scheme in detail. There are some variations of discordant anomaly according to the presence and location of formation failure and segmentation failure. The scheme on the left in Fig. 19A is normal. When the anterior component (vertebra) has no

anomaly, it is possible for AP discordant anomaly with hemilamina to occur with or without posterior segmentation failure (Figs. 11, 19A right). If anterior formation failure is present, AP discordant anomaly can occur (Figs. 6, 19B). When anterior segmentation failure is present, AP discordant anomaly may occur (Fig. 19C). As an unusual type of AP discordant anomaly, AP discordant *segmentation* anomaly can also be present when the level of segmentation is mismatched between anterior and posterior components (Figs. 18, 19D). It may sometimes be difficult to evaluate AP discordant anomaly, so it may be useful to refer to the anterior and posterior components using the rib and the transverse process. That is, when the same rib is seen in the anterior and posterior views in 3DCT images, it is easier to evaluate the anomaly. AP discordant anomaly at the lumbar spine seems to be easier to evaluate compared to that at the thoracic spine.

There are clearly several types of AP discordant anomaly and the above findings are important for reference during surgery. Osteotomy from a posterior approach is now performed and in this method resection of anterior components from the posterior approach is performed blindly. Therefore, it is important to consider AP discordant anomaly for performing safe and accurate surgical procedures.



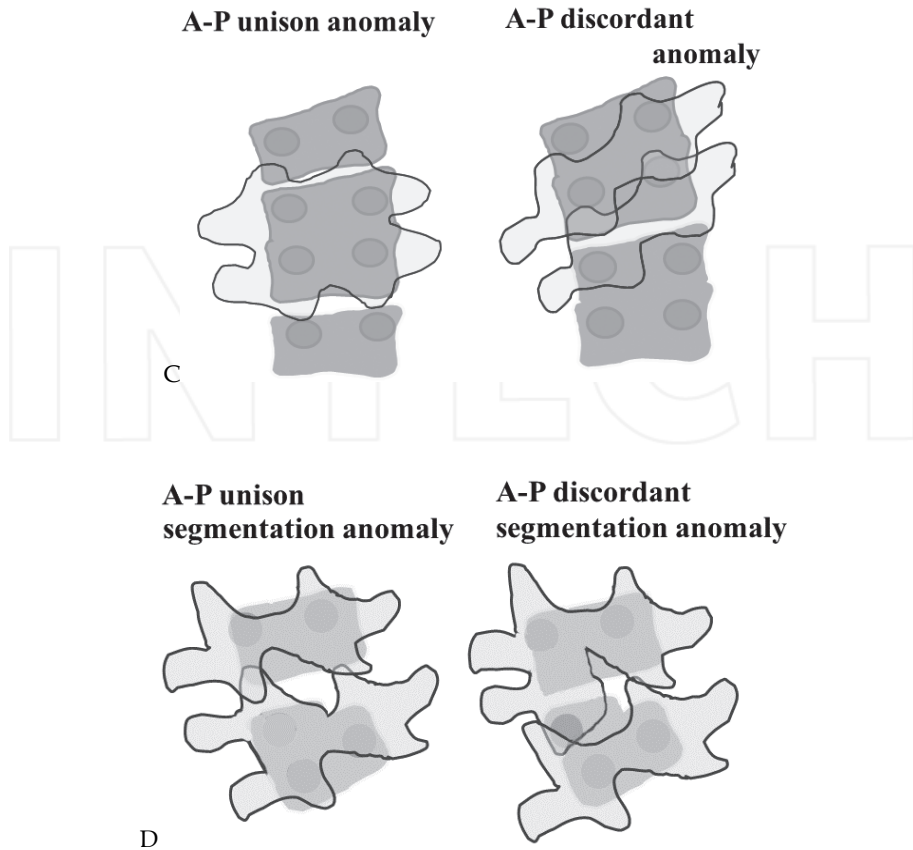
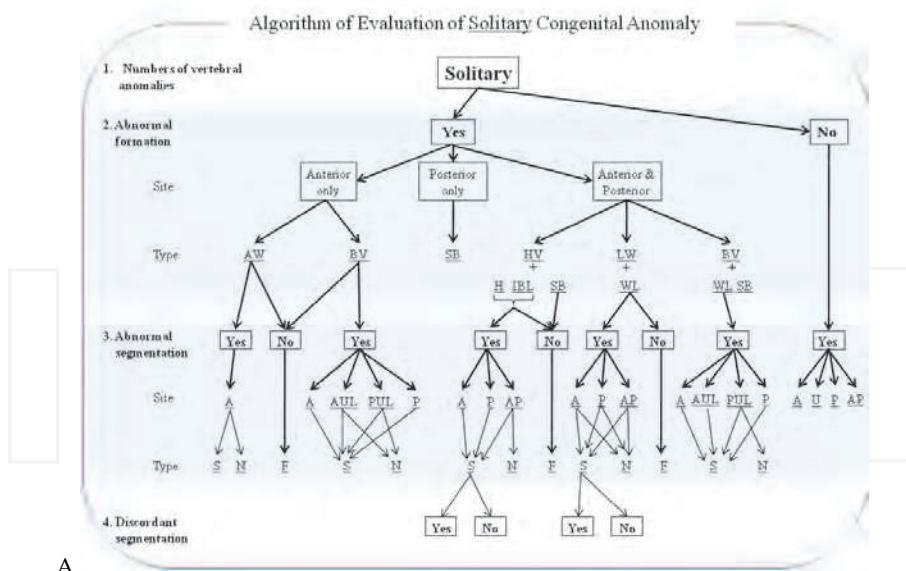


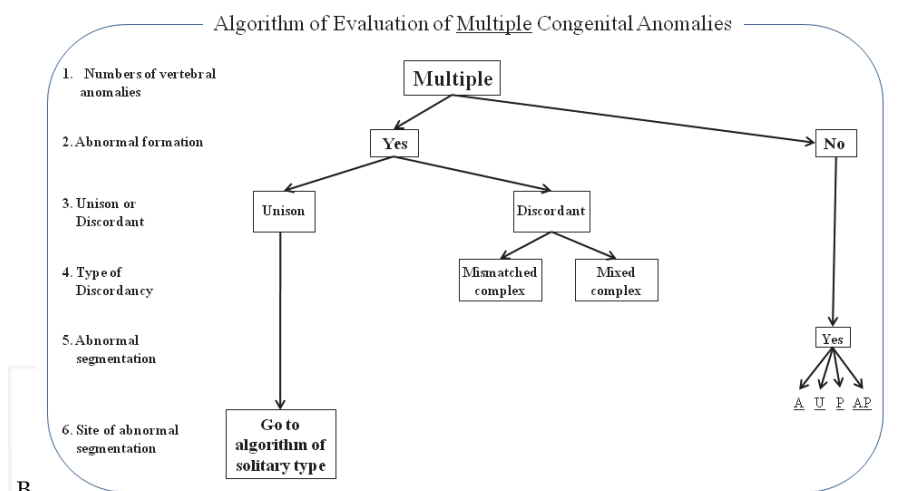
Fig. 19. **Scheme of AP discordant anomaly.** There are several type of AP discordant anomaly based on the location and presentation of formation failure and segmentation failure.

3. Conclusion (A new 3D classification of congenital anomaly)

We have evaluated congenital anomaly with 3DCT images for several years as described above, and developed a new classification of congenital scoliosis and kyphosis (Kawakami et al. 2009). This work clearly illustrated the limitation of two-dimensional classification, showed the clinical significance of 3D analysis of congenital vertebral anomalies, and allowed the proposal of a new 3D classification of these anomalies. The large volume of information obtained by 3DCT, including the various morphologies, patterns of segmentation, solitary or multiple, and unison or discordant, complicates the classification (Fig. 20). However, we believe that this approach provides a closer view of the reality of vertebral abnormalities based on analysis of 3DCT images, compared to past classifications. This new classification of congenital scoliosis based on 3D imaging is needed to understand the etiology and embryology of the disease, as well as to determine an operative strategy.



A




B

Fig. 20. Algorithm of evaluation of congenital anomalies. There are algorithms for the solitary type (A) and for the multiple type (B). If more than 2 congenitally abnormal vertebrae exist in whole spinal column, we should follow the algorithm for the multiple type. This algorithm helps to clarify the characteristics of abnormal vertebra. A indicates anterior; P, posterior; BV, butterfly vertebra; W, wedged vertebra; HV, hemivertebra; SB, spina bifida; AW, anterior wedged vertebra; LW, lateral wedged vertebra; H, hemilamina; IBL, incomplete bilamina; WL, wedged lamina; AUL, anterior unilateral; PUL, posterior unilateral; S, semisegmented; N, nonsegmented; F, fully segmented; U, unilateral; AP, anteroposterior(Kawakami et al. 2009).

4. References

- Imagama, S. et al.(2004). The three-dimensional analysis of congenital scoliosis–segmentation failure. *J Jpn Scoliosis Soc*;19:33–7.
- Imagama, S. et al.(2005). Spacial relationships between a deformed vertebra and an adjacent vertebra in congenial scoliosis–failure of formation. *J Jpn Scoliosis Soc*;20:20–5.
- Kawakami, N. et al.(2009). Classification of Congenital Scoliosis and Kyphosis: A New Approach to the Three-Dimensional Classification for Progressive Vertebral Anomalies Requiring Operative Treatment. *Spine*;34:1756–65
- Nakajima, A. et al.(2007). Three-Dimensional analysis of formation failure in congenital scoliosis. *Spine* ;32:562–7.
- Newton, PO. et al.(2002). Utility of three dimensional and multiplanar reformatted computed tomography for evaluation of pediatric congenital spine abnormalities. *Spine*;27:844–50.
- Winter, RB.; Moe, JH.& Wang, JF.(1973). Congenital Kyphosis–Its natural history and treatment as observed in a study of one hundred thirty patients. *J Bone Joint Surg Am*;55:223–56.

INTECH



CT Scanning - Techniques and Applications

Edited by Dr. Karupppasamy Subburaj

ISBN 978-953-307-943-1

Hard cover, 348 pages

Publisher InTech

Published online 30, September, 2011

Published in print edition September, 2011

Since its introduction in 1972, X-ray computed tomography (CT) has evolved into an essential diagnostic imaging tool for a continually increasing variety of clinical applications. The goal of this book was not simply to summarize currently available CT imaging techniques but also to provide clinical perspectives, advances in hybrid technologies, new applications other than medicine and an outlook on future developments. Major experts in this growing field contributed to this book, which is geared to radiologists, orthopedic surgeons, engineers, and clinical and basic researchers. We believe that CT scanning is an effective and essential tools in treatment planning, basic understanding of physiology, and and tackling the ever-increasing challenge of diagnosis in our society.

How to reference

In order to correctly reference this scholarly work, feel free to copy and paste the following:

Shiro Imagama, Noriaki Kawakami and Naoki Ishiguro (2011). Three-Dimensional CT Analysis of Congenital Scoliosis and Kyphosis: A New Classification, *CT Scanning - Techniques and Applications*, Dr. Karupppasamy Subburaj (Ed.), ISBN: 978-953-307-943-1, InTech, Available from: <http://www.intechopen.com/books/ct-scanning-techniques-and-applications/three-dimensional-ct-analysis-of-congenital-scoliosis-and-kyphosis-a-new-classification>

INTECH

open science | open minds

InTech Europe

University Campus STeP Ri
Slavka Krautzeka 83/A
51000 Rijeka, Croatia
Phone: +385 (51) 770 447
Fax: +385 (51) 686 166
www.intechopen.com

InTech China

Unit 405, Office Block, Hotel Equatorial Shanghai
No.65, Yan An Road (West), Shanghai, 200040, China
中国上海市延安西路65号上海国际贵都大饭店办公楼405单元
Phone: +86-21-62489820
Fax: +86-21-62489821