

# CASE REPORT

Nagoya J. Med. Sci. **80**. 605–609, 2018  
doi:10.18999/nagjms.80.4.605

## **A case of delayed hydrocephalus from cerebrospinal fluid leak after resection of a cervical spinal schwannoma**

Kazuyoshi Kobayashi, Kei Ando, Kenyu Ito, Mikito Tsushima, Masayoshi Morozumi, Satoshi Tanaka, Masaaki Machino, Kyotaro Ota, Naoki Ishiguro, and Shiro Imagama

*Department of Orthopedic Surgery, Nagoya University Graduate School of Medicine, Nagoya, Japan*

### ABSTRACT

A 39-year old man underwent surgery for recurrence of a cervical schwannoma. At 6 months postoperatively, severe headache appeared and head CT showed marked ventricular dilation that was diagnosed as delayed hydrocephalus. Dural repair surgery using a fascia patch of the tensor fasciae latae muscle was performed after VP shunt. This case shows the importance of awareness of the possibility of delayed hydrocephalus in a patient with severe headache.

**Keywords:** Cerebrospinal fluid leakage, delayed hydrocephalus, cervical cord tumor, ventriculoperitoneal (VP) shunt

This is an Open Access article distributed under the Creative Commons Attribution-NonCommercial-NoDerivatives 4.0 International License. To view the details of this license, please visit (<http://creativecommons.org/licenses/by-nc-nd/4.0/>).

### INTRODUCTION

Cerebrospinal fluid (CSF) leakage is a common complication after spinal tumor resection that resolves naturally in many cases.<sup>1)</sup> However, reliable repair of the dura is needed to prevent the risk of meningitis and surgical site infection (SSI).<sup>2-3)</sup> In contrast, hydrocephalus with CSF leakage as a complication after spinal surgery is rare. Here, we report a rare case of delayed hydrocephalus due to CSF leakage after cervical cord tumor surgery. Reoperation was performed with dural occlusion using a patch after ventriculoperitoneal (VP) shunt. The patient gave consent for publication of the details of the case.

### REPORT OF THE CASE

A 22-year-old male with gait disturbance and numbness in both hands underwent cervical cord tumor resection at another hospital 17 years ago. In surgery, after dural incision with C1-2 partial laminectomy, tumor resection was performed. The tumor was benign pathologically and was diagnosed as schwannoma. Postoperatively, gait disturbance improved and there was no

---

Received: January 22, 2018; accepted: April 17, 2018

Corresponding Author: Shiro Imagama, MD

Department of Orthopedic Surgery, Nagoya University Graduate School of Medicine,  
65 Tsurumai-cho, Showa-ku, Nagoya, 466-8560, Japan

Tel: +81-52-741-2111, Fax: +81-52-744-2260, E-mail: [imagama@med.nagoya-u.ac.jp](mailto:imagama@med.nagoya-u.ac.jp)

recurrence for a long period.

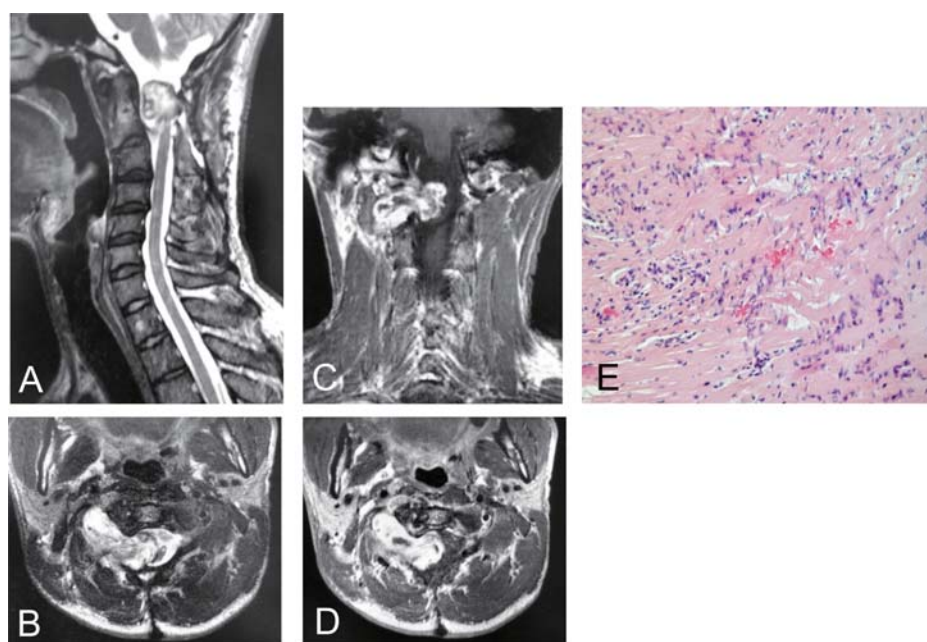
Seventeen years after the initial surgery, the patient developed cervical myelopathy with gait disturbance, and consulted with our institution. Tumor regrowth with a dumbbell shape was detected on T2-weighted magnetic resonance imaging (MRI) of the cervical cord. This imaging showed an isointense and iso- to hyperintense intradural tumor with a dumbbell shape at the C1-2 level, and T1 gadolinium-enhanced imaging revealed heterogenous enhancement with spinal cord compression (Figures 1A–D).

Tumor resection was performed with the patient in a prone position under general anesthesia. After complete tumor removal with dura mater, artificial dura mater (Goretex®) was used for closure due to a defect of the primary dura mater. A combination of polyglactin acid (PGA) sheets (Neoveil®, Gunze Ltd., Osaka, Japan) and fibrin glue (Beriplast P®, CSL Behring, Tokyo, Japan) was applied, and suture of muscle, fascia, and skin was performed in a watertight layer-by-layer fashion. A subfascial closed suction drain and an intradural lumbar CSF catheter were then placed. Postoperatively, pathological findings showed proliferation of spindle cells of mixed Antoni A and B types (Figure 1E). The pathological diagnosis was schwannoma.

The subfascial closed suction drain was removed 2 days after surgery and the intradural lumbar CSF catheter was removed 5 days after surgery. Wound closure was good and the patient recovered without fever or increased inflammatory reaction. At 10 days postoperatively, MRI indicated tumor resection in sagittal T2-weighted (Figure 2A) and axial T1 gadolinium-enhanced (Figure 2B) images, and gait disturbance and upper limb numbness improved.

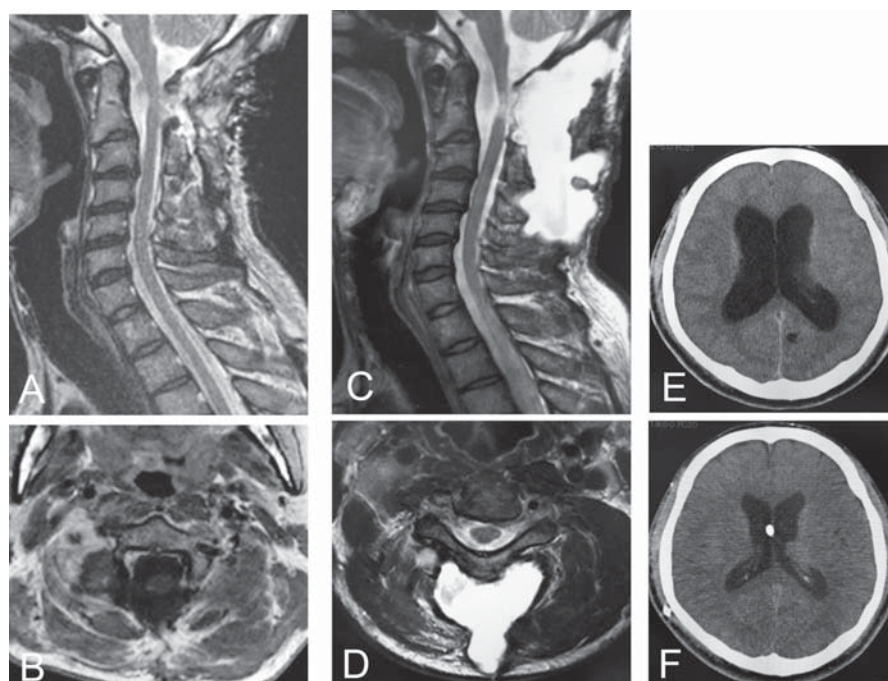
At 2 months postoperatively, MRI showed CSF leakage (Figures 2C, D), but the wound condition was good and there was no worsening of obvious symptoms. At 6 months postoperatively, severe headache developed and head CT showed marked ventricular dilation (Figure 2E) that was diagnosed as hydrocephalus. A CSF culture test did not detect bacteria, glucose and protein levels in CSF were normal, the cell number was within the normal range, and mononuclear cells dominated. CSF analysis showed 428 cells/mm<sup>3</sup> (normal range, <8 cells/mm<sup>3</sup>) with 42% polymorphonuclear and 58% mononuclear, glucose 42.3 mg/dl (normal range, 25–44 mg/dl), chloride 114.2 mmol/L (normal range, 120–130 mmol/L), and protein 1.6 mg/dl (normal range, 1.5–4.5 mg/dl). The results were negative for bacterial meningitis; however, the findings were consistent with aseptic meningitis. VP shunt was performed by a neurosurgeon for treatment of hydrocephalus with shunt-valve pressure first set to 150 mmHg, after which headache disappeared and cerebral ventricle shrinkage was immediately apparent (Figure 2F). However, subcutaneous CSF leakage did not improve in MRI.

At 2 months after VP shunt, CSF leakage had still not improved. Therefore, we finally performed dural repair surgery using a fascia patch. In surgery, when the skin incision was made, a large amount of subcutaneous spinal fluid was discharged and a defect from the subcutaneous to the dural cavity was observed (Figure 3A). The fascia patch was excised from the tensor fasciae latae muscle (Figure 3B) and resutured tightly and closed at the same site (Figure 3C). A combination of PGA sheets and fibrin glue was applied, and tight suture of muscle, fascia, and skin was performed in a watertight layer-by-layer fashion for closure of dead space. A subfascial closed suction drain was placed for 2 days, and an intradural lumbar CSF catheter was placed for 5 days after surgery. Postoperatively, a soft collar was used for 2 months. At 3 months after the reoperation, a decrease in CSF leakage was observed in sagittal T2-weighted MRI (Figure 3D), and since then no CSF leakage has occurred.



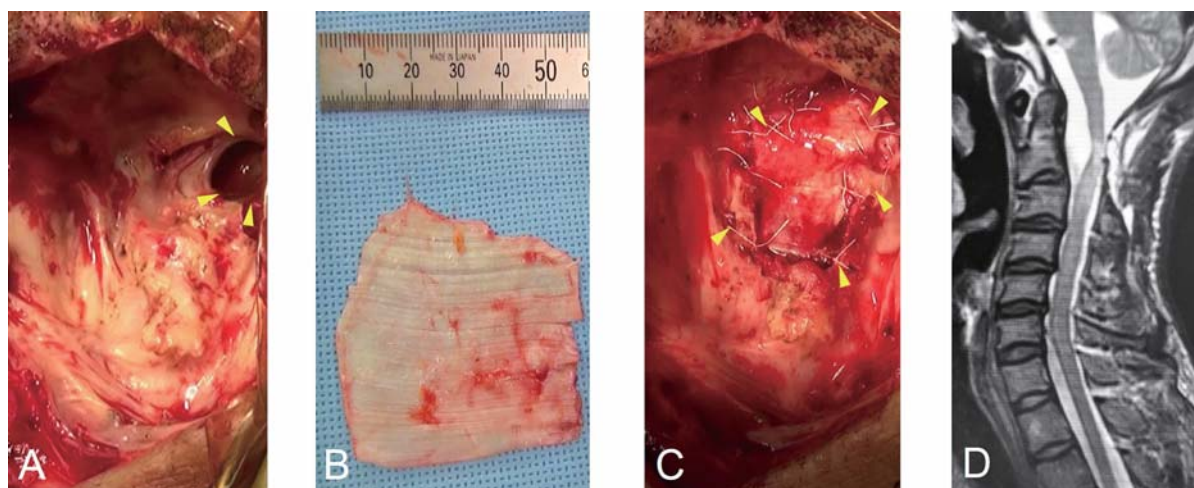
**Fig. 1** Postoperative course 1

Sagittal (A) and axial (B) T2-weighted MRI of the cervical cord revealed an isointense and iso-to-hyperintense intradural tumor with a dumbbell shape at the C1-2 level at initial consultation. Coronal (C) and axial (D) T1-postgadolinium imaging at this time showed heterogenous enhancement. (E) Pathological findings showed proliferation of spindle cells of mixed Antoni A types, resulting in diagnosis of schwannoma.



**Fig. 2** Postoperative course 2

At 10 days postoperatively, sagittal T2-weighted (A) and axial T1 gadolinium-enhanced imaging (B) confirmed tumor resection. After 2 months, sagittal (C) and axial (D) T2-weighted imaging confirmed CSF leakage with no increase in tumor size. (E) At 6 months after surgery, CT showed lateral ventricle dilatation, which was diagnosed as hydrocephalus. (F) Cerebral ventricle shrinkage was apparent immediately after VP shunt surgery.



**Fig. 3** Postoperative course 3

CSF leakage did not improve after 2 months postoperatively, and dural repair using a fascia patch was performed. In surgery, skin incision resulted in discharge of a large amount of subcutaneous spinal fluid, and there was a defect from the subcutaneous to the dural cavity (yellow arrowhead) (A). A fascia patch was excised from the tensor fasciae latae muscle (B) and resutured and closed at the same site (yellow arrowhead) (C). At 3 months after the reoperation, sagittal T2-weighted MRI showed a decrease in CSF leakage (D).

## DISCUSSION

The course of postoperative CSF leakage requires a long time for spontaneous cure.<sup>4-5)</sup> Many cases are treated conservatively with antibiotics, but sometimes direct dural repair is needed.<sup>2)</sup> A fascia patch,<sup>6)</sup> autologous fat transplants,<sup>3)</sup> a combination of PGA sheet and fibrin glue,<sup>7-9)</sup> and strong compression<sup>1)</sup> have been used to prevent CSF leakage. In general, CSF leakage improves in several days, and severe cases are relatively rare. In our case, artificial dura mater was used after a reoperation for tumor regrowth, but a large defect of the dura mater and soft tissue caused prolonged CSF leakage.

Hydrocephalus is a state in which abnormal dilation of the ventricle occurs due to a circulatory or absorptive disorder of the CSF.<sup>10)</sup> Hydrocephalus due to CSF leakage is a rare complication after spinal surgery. A relationship between hydrocephalus and meningitis has been proposed,<sup>4,5)</sup> with Uehara *et al.* suggesting that bacteria causing meningitis may cause exudative inflammation and infiltration of many neutrophils in the arachnoid space in 2 months after resection of a cervical cord tumor.<sup>4)</sup> Kumai *et al.* reported that a fibrinous component also develops, which spreads to the brain surface or subarachnoid space and causes adhesion, which impairs CSF circulation and finally leads to hydrocephalus in 5 months after cervical laminoplasty.<sup>5)</sup> There are also several reports of a relationship between meningitis and CSF leakage,<sup>1,6)</sup> with incidences of meningitis after CSF leakage of 3%<sup>1)</sup> and 13%.<sup>6)</sup> In our case, CSF findings indicated an absence of bacteria, normal glucose and protein, and dominant mononuclear cells, which did not prove septic meningitis. However, inflammation may have been caused by aseptic meningitis, and microhemorrhage and fibrinogenic components might have been causes of CSF circulation disorder and absorption disorder in the subarachnoid space. This situation may have then led to delayed hydrocephalus.

In our case, CSF leakage occurred for a long period postoperatively. This is a rare case in which hydrocephalus developed some time after CSF leakage following spine tumor surgery. Subcutaneous CSF leakage can cause SSI, meningitis, hydrocephalus, and severe headache, and



can be fatal. High fever and loss of consciousness, which are characteristics of septic meningitis, did not occur in our case. However, hydrocephalus caused severe headache, and aseptic meningitis occurred. Treatment with VP shunt for hydrocephalus and reoperation with a fascia patch for CSF leakage resulted in recovery without sequelae. We used a fascia patch with a tight resuture, which is more invasive than artificial dura, but is less likely to cause CSF leakage due to adhesion. This approach was effective for closure of dead space and tight suture of muscle, fascia and skin in a watertight layer-by-layer fashion. Subsequent use of a cervical collar contributed to stabilization of soft tissue through cervical immobilization.

Typically, postoperative CSF leakage could be expected for spontaneous cure; thus, surgical closure with dural repair is not necessarily performed if there is no infection. However, in our case, CSF leakage did not improve, even more than 6 months after surgery, and the patient complicated with hydrocephalus and aseptic meningitis at 6 months. VP shunt improved hydrocephalus, but did not improve CSF leakage. Improvement of CSF leakage required dural repair surgery using a fascia patch. The occurrence of hydrocephalus due to postoperative CSF leakage suggests that we should have performed dural repair surgery first and introduced an intradural lumbar CSF catheter before performance of VP shunt.

## CONCLUSION

This case shows the need for prevention of CSF leakage after spinal tumor surgery, and indicates that delayed hydrocephalus can occur in a patient with severe headache.

## CONFLICTS OF INTEREST

None of the authors have a conflict of interest with regard to the work in the study.

## REFERENCES

- 1) Ohtani K. Natural course of postoperative cerebrospinal fluid fistula. *Rinsho-Seikei Geka Zasshi*, 1997; 32: 413–8. (in Japanese)
- 2) Eismont FJ, Wiesel SW, Rothman RH. Treatment of dural tears associated with spinal surgery. *J Bone Joint Surg Am*, 1981; 63: 1132–1136.
- 3) Mayfield FH. Autologous fat transplants for the protection and repair of the spinal dura. *Clin Neurosurg*, 1980; 27: 349–361.
- 4) Uehara M, Yara T, Arakaki K, *et al.* Hydrocephalus following resection of cervical cord tumor: a case report. *Seikeigeka to Saigaijeka*, 2001; 50: 703–7. (in Japanese)
- 5) Kumaki S, Hirabayashi K, Katsuragawa Y, Miyamoto Y, Saito A, Yamamoto T. Late hydrocephalus treated conservatively secondary to liquorrhea after cervical laminoplasty: a case report. *J Spine Res*, 2017; 8: 1314–1316.
- 6) Tokuhashi Y, Matsuzaki H, Okawa A, *et al.* Drainage for postoperative cerebrospinal fluid leakage. *Nihon Sekituijekkagakkai-Zasshi*, 1998; 9: 418–424. (in Japanese)
- 7) Black P. Cerebrospinal fluid leaks following spinal surgery: use of fat grafts for prevention and repair. Technical note. *J Neurosurg*, 2002; 96: 250–252.
- 8) Epstein NE. Hemostasis and other benefits of fibrin sealants/glues in spine surgery beyond cerebrospinal fluid leak repairs. *Epstein Surg Neurol Int*, 2014; 5: S304–314.
- 9) Takeno K, Uchida K, Nakajima H. Usefulness of polyglactin acid sheet and fibrin glue with dural defect during spinal surgery. *Chubuseisaishi*, 2012; 55: 279–80. (in Japanese)
- 10) McComb JG. Cerebrospinal fluid physiology of the developing fetus. *AJNR Am J Neuroradiol*, 1992; 13: 595–599.