

# SEGI'S CAP: GROUP FORMATION OF GUT ENDOCRINE CELLS AT THE TIP OF THE VILLI IN HUMAN EMBRYONAL INTESTINE

SHIGERU KOBAYASHI and SATOSHI IINO

*Department of Anatomy, Nagoya University School of Medicine, Nagoya, Japan*

## ABSTRACT

Large groups of basal-granulated (entero-endocrine) cells occur on the top of villi in the duodenum and upper jejunum of the human fetus older than five months of gestation. This structure was discovered and described by Segi(1935), hence named Segi's cap. By the immunocytochemical technique, somatostatin-, gastrin- and motilin-producing cells were demonstrated. By electron microscopy, EC, D and S cells were identified in the cap. There were autonomic nerves in the lamina propria adjacent to Segi's cap. No intraepithelial lymphocytes were found in the villi with Segi's cap.

## INTRODUCTION

The gut endocrine cells are usually disseminated among other epithelial cells such as parietal and chief cells of the gastric gland and enterocytes and goblet cells of the small intestine.<sup>1-3)</sup> Group formation of the gut endocrine cells is believed never to occur, with some exceptions such as those seen in the lamina propria mucosae of the processus vermiformis.<sup>1,2)</sup> However, restricted to a short perinatal period of human life (later than five months of gestation, and shortly after birth), gut endocrine cells form a large aggregation on the very top of the intestinal villi.<sup>4,5)</sup> This unique structure was first described by Segi (1935)<sup>4)</sup> (Fig. 1,2); however, as his paper was written in Japanese with only a short German abstract, his work was not noticed in the West until recently. Kobayashi, et al. (1980)<sup>6)</sup> found Segi's old paper and confirmed that there are aggregations of gut endocrine cells containing various gut hormones (neuropeptides) in the human fetal gut.<sup>7)</sup> They proposed the term Segi's cap to name this cellular structure.<sup>6)</sup> In the present article the current status of the natural history and cell biology of Segi's cap will be presented.

## PROFESSOR M. SEGI

Professor M. Segi was born in 1908 in Nagoya and graduated from the Tokyo Imperial University Medical School in 1932. He conducted an embryological and histological study of the "granule-containing cells" in the Anatomy Department of the Tokyo Imperial University from 1932 to 1935. The subject of the study was suggested by Professor M. Inoue (1879-1959) for Segi's doctoral thesis. In those days, basal-granulated cells in the intestinal epithelium were considered to be a single kind of "enterochromaffin cell" which shows a positive chromaffin reaction when treated with potassium dichromate-containing fixative.

After completing his doctoral thesis in the Anatomy Department, Segi was trained in obstetrics and gynecology and became the Director of Maternal and Child Hygiene in the Japanese

---

Correspondence: Dr. S.Kobayashi, Department of Anatomy, Nagoya University School of Medicine, Tsuruma-cho, Showa-ku, Nagoya 466, Japan

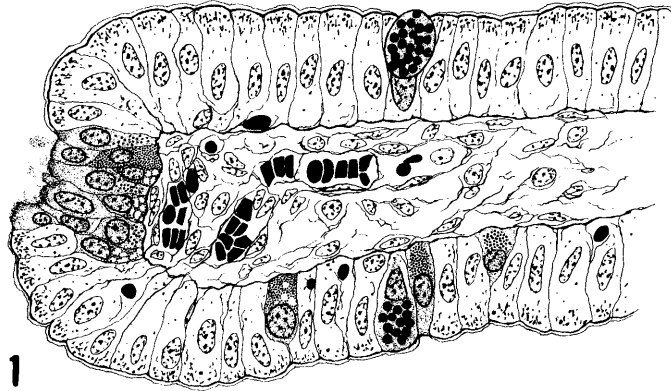


Fig. 1. Segi's cap on the top of the villus.

From the mid-duodenum of a fetus (crown-rump length: 146 mm. 18 weeks and 4 days of the last mensus. Male). Fixed in dichromate-formol, and stained by azan method. Although Segi (1935, 1936)<sup>4,5)</sup> did not describe nervous and immune systems of the villus, he clearly distinguished several kinds of connective tissue cells such as subepithelial reticular cells. Segi found erythrocytes in blood capillary and in the intercellular space of the epithelial layer.

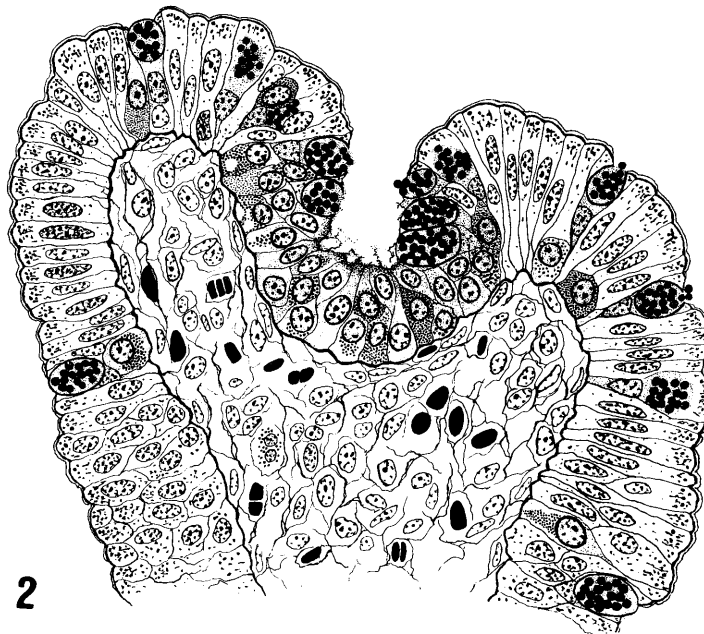


Fig. 2. Segi's cap with 27 nuclei of entero-endocrine cells.

From the duodenum next to the stomach of a fetus (crown-rump length: 230 mm. 31 weeks and 4 days after the last mensus. Female ).<sup>5)</sup> Stained by azan. Goblet cells show a tendency to gather along the fringe of the dent of Segi's cap.

## SEGI'S CAP:

Ministry of Health and Welfare in 1940. In 1950 he became a Professor of Public Health at the Tohoku University Medical School in Sendai, where he spent two decades mostly engaged in the study of cancer epidemiology. He and his co-workers published five volumes of cancer mortality statistics including data on 24 countries for the years 1950 to 1965.

Segi retired in 1971 from the post of professor at the Tohoku University and became the President of the Mizuho Junior College in Nagoya. He continued his study of cancer epidemiology as a research associate at the Aichi Cancer Research Institute in Nagoya and founded the Segi Institute of Cancer Epidemiology. Segi died of a heart attack on May 8, 1982.

## REDISCOVERY OF SEGI'S CAP

Segi's papers on the peculiar colony of basal-granulated cells were published in the 8th and 9th volumes of the *Kaibogaku-Zasshi* (*Acta Anatomica Nipponica*) in Tokyo in June 1935<sup>4)</sup> and December 1936,<sup>5)</sup> respectively. These two Japanese-written papers were accompanied by a German summary and ample illustrations. However, neither Japanese nor foreign researchers seemed to pay particular attention to his achievements. Thus the discovery of Segi was destined to be forgotten by later researchers for 45 years until it was confirmed in 1979.<sup>6)</sup>

Segi's discovery was forgotten for many reasons. First, the main circulation of the *Kaibogaku-Zasshi* was limited even in Japan, and The Japanese text of Segi's papers was impossible for people in the West to understand. Second, World War II started in 1939 and wartime distress hindered the progress of research in basic medicine such as areas like the morphology of the intestinal epithelium. Third, the nature and function of basal-granulated cells were unknown in the 1930s, causing both morphologists and physiologists to have little interest in them. Fourth, Segi himself moved to the Department of Obstetrics and Gynecology in 1935 and his scientific interest changed from anatomy to maternal and child health and then to cancer epidemiology.

It was in 1965 that Italian pathologists, Solcia and his co-workers, proposed that gastrin is a product of G cells in the antro-pyloric mucosa of the stomach.<sup>8, 9)</sup> Later, Swiss (Forssmann, et al., 1969),<sup>10)</sup> British (Pearse, et al., 1970)<sup>11)</sup> and Japanese endocrine morphologists (Kobayashi, et al., 1970)<sup>12)</sup> confirmed that not only gastrin but also other gut hormones are a product of the basal-granulated cells. All these authors are in agreement on the point that one of the most characteristic features of the basal-granulated cells is that they are disseminated among other epithelial cells, thus they form no cellular group.

In 1975, Kobayashi at the Anatomy Department of the Niigata University Medical School, encountered Segi's papers. The illustrations shown in these papers were striking to contemporary endocrine morphologists who had believed that basal-granulated cells never formed a cell nest. Thus the reinvestigation of this unique structure described by Segi was started utilizing techniques of modern morphologies (Fig. 3-6)

It is certain that Segi examined excellently fixed specimens stained with azan, and clearly distinguished several types of basal-granulated cells with differently colored granules. This observation of Segi was outstanding for those days because in the 1930s the basal-granulated cells were supposed to belong to one and the same "enterochromaffin cell system" (Clara, 1933).<sup>13)</sup> Regrettably, Segi (1935, 1936)<sup>4, 5)</sup> had the idea that the basal-granulated cells with differently tinged granule population represented various functional stages of a single kind of enterochromaffin cell. Therefore, he did not notice that the colony of basal-granulated cells at the tip of the intestinal villus consisted of plural populations of basal-granulated cells secreting different gut hormones.

Light microscopic studies of Iwanaga *et al.* (1980)<sup>7)</sup> have shown that the greater part of the grouped basal-granulated cells in Segi's cap were argyrophil. About half the argyrophil cells were argentaffin, indicating that they contained serotonin. By the immunocytochemical technique using specific antisera against various gut hormones, somatostatin-, gastrin- and motilin-immunoreactive cells were identified in Segi's cap. It was also demonstrated that CCK-PZ, secretin- and pancreatic peptide-immunoreactive cells were dispersed in the intestinal epithelium, but they did not show a tendency to gather on the top of the villi. VIP-, substance P- and insulin-immunoreactive cells were not found in the fetal intestinal epithelium.

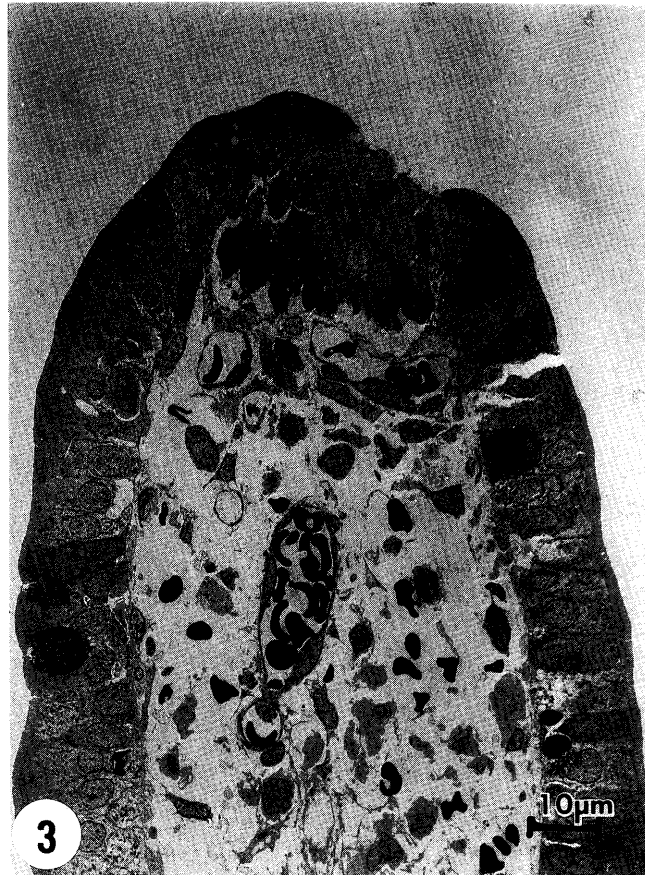


Fig. 3. A low magnification electron micrograph of Segi's cap. From the duodenum of a human fetus (6 months of gestation). Notice that there are no intraepithelial lymphocytes in the villus. There are several erythrocytes in the tissue space of the lamina propria mucosae. It is unknown whether they represent physiological state or artefactual bleeding during specimen preparation.

## SEGI'S CAP:

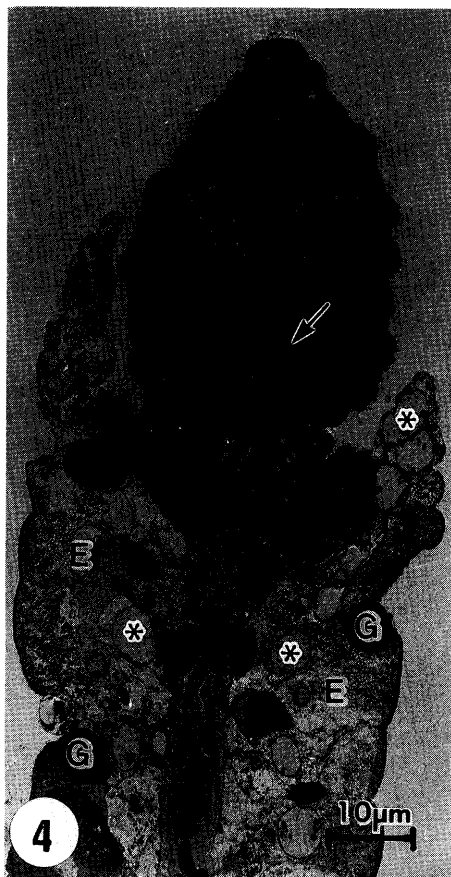


Fig. 4. A polyethylene-glycol induced cap on the top of the villus.<sup>21)</sup>  
 This cap contains many goblet cells and a few entero-endocrine cells (arrow, usually difficult to identify).  
 Degenerated enterocytes appear pale (E). Their nuclei still can be seen (asterisks). G indicates isolated goblet cells.

The ultrastructure of the grouped basal-granulated cells in the Segi's cap in the human fetus was similar to that of the isolated basal-granulated cells of the adult.<sup>7)</sup> EC, D and S cells were identified (Fig. 5,6). However, many basal-granulated cells in Segi's cap were unclassifiable because of an atypical appearance of their secretory granules.

Ultrastructural features characteristic of those basal-granulated cells in Segi's cap are summarized as follows:

1) The apical pole of the basal-granulated cells in Segi's cap was provided with various cytoplasmic projections. Regularly arranged microvilli were rare, whereas club- or finger-shaped projections were frequently seen.

2) Many polymorphous lysosomes were dispersed in the cytoplasm of some basal-granulated cells.

3) Bundles of cytoplasmic microfilaments were abundantly interspersed among the secretory granules and mitochondria.

4) Large, rounded bodies of moderate electron opacity measuring up to 1  $\mu\text{m}$  in diameter

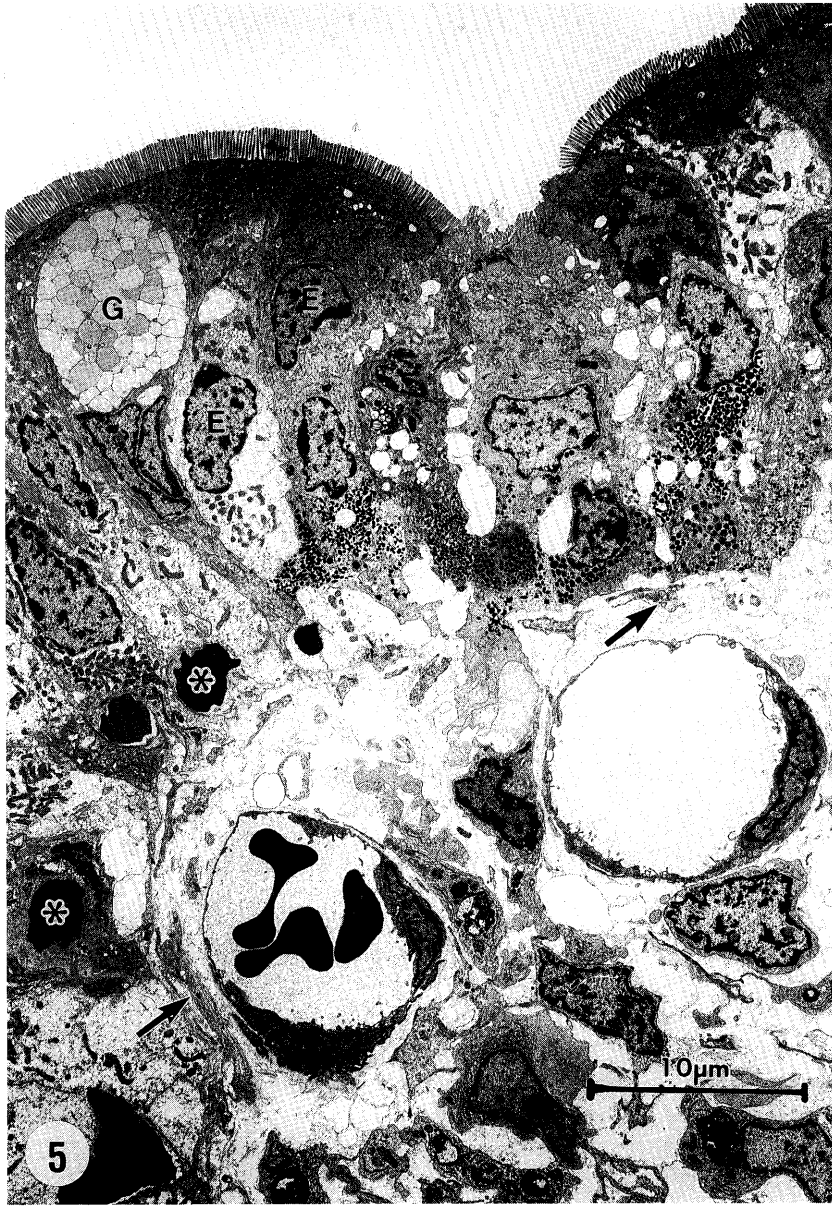


Fig. 5. A transmission electron micrograph of the top of the villus with Segi's cap. From the duodenum of a human fetus (6 months of gestation) E: enterocyte. G: goblet cell. Asterisks indicate erythrocytes in the intercellular space in the epithelial layer. Arrows indicate autonomic nerve fiber bundles.

## SEGI'S CAP:

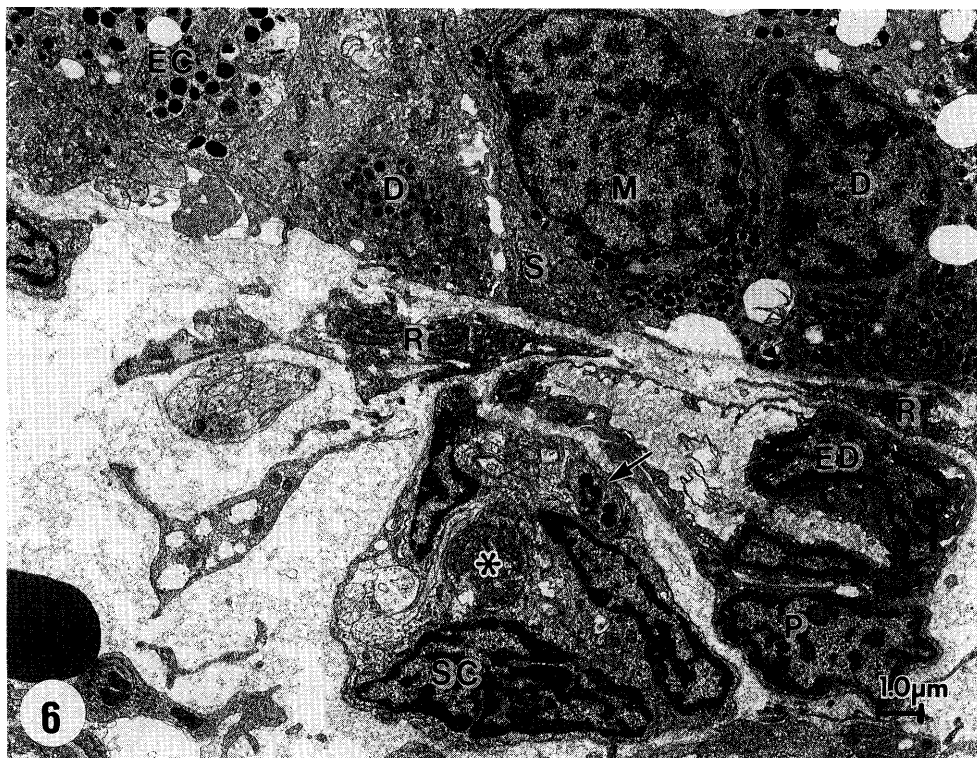

Fig. 6. A transmission electron micrograph showing a basal portion of a Segi's cap. D(D), EC(EC) and S(S) cells are identified based on the morphology of the secretory granules. Endocrine cell marked by M is unknown in cell type. In the lamina propria mucosae beneath the Segi's cap, there are profiles of subepithelial reticular cells (R), capillary endothelial cells (ED) and capillary pericyte (P). The nerve of the lower half of this picture appears unique; 1) the neuronal terminal in the center contains many mitochondria (asterisk); 2) there are three profiles of Schwann (glial) cells (SC); and 3) the neuronal terminal indicated by the arrow contains many lysosome-like bodies.

occurred in the basal cytoplasm. These vacuoles are similar to the precursor-type secretory granules in the precursor and transitional cells in the intestine of human fetus described by Moxey and Trier.<sup>14)</sup>

Segi<sup>4, 5)</sup> in his original light microscopic study, clearly illustrated the difference between types of basal-granulated cells concerning the size, shape and staining property of their secretory granules, though he did not notice that this difference in light microscopic features was due to different gut hormones. The cells that showed strong chromaffin reaction in Segi's preparations probably correspond to EC cells in electron microscopy, whereas those with rounded blue granules that he recognized in his dichromate-fixed and azan-stained sections are probably D cells. The other basal-granulated cells illustrated by Segi are still difficult to correlate with ultrastructural and immunocytological classifications. Basal-granulated cells illustrated in yellow or brown in Segi's original drawing do not necessarily correspond to EC cells, because the yellow to brown of the azan-stained specimen used by Segi is not due to dichromate but due to orange G of the staining solution.

## SEGI'S CAP IN EXPERIMENTAL ANIMALS

Segi performed his studies in the human fetus only.<sup>4,5)</sup> He found characteristic aggregations of gut endocrine cells in the duodenum and upper jejunum. Thus it has remained unknown whether or not Segi's cap was present in the fetuses of other mammals.

Yamada and co-workers investigated the occurrence of Segi's cap in cattle and pig fetuses.<sup>15,16)</sup> They showed that Segi's cap also occurs in both of these species of animal fetuses. Segi's cap in these domestic animals consists mainly of argyrophil basal-granulated cells. By immunocytochemistry, gastrin-, somatostatin-, motilin-, and secretin-containing cells were demonstrated. It is interesting that Yamada *et al.* found no argentaffin cells (serotonin-secreting EC cells) in the Segi's cap of cattle and pig fetuses.

Kobayashi and Segi (1984)<sup>17)</sup> examined monkey fetuses. Segi's cap is present in monkey fetuses at a later stage of pregnancy. The aggregation of basal-granulated cells mixed with goblet cells occurs not only in the duodenum and jejunum but also in the ileum and colon. Gastrin-, CCK-, somatostatin and motilin-immunoreactive cells were demonstrated in the Segi's cap of the monkey intestine.

Comparative studies of Segi's cap in various experimental animals facilitate the analysis of its function and significance in the human fetus.

## CELL BIOLOGICAL MECHANISM OF THE FORMATION OF SEGI'S CAP

Segi<sup>5)</sup> discussed the possibilities that the top of the intestinal villi was a generative spot for the basal-granulated cells. He suggested that the basal-granulated cells are produced in the tops of the villi. However, it has been established in several animal species that the lower portion of the crypts represents the cell proliferation site and that the epithelial cells with the exception of the Paneth cells move from the crypt toward the villus top.<sup>18-20)</sup> Therefore, it is unlikely that Segi's cap is formed by the division of the basal-granulated cells in the villus and plays the role of support-center of the basal-granulated cells during the prenatal life.

It is possible to make Segi's cap-like structure by experimentation. Clarke and Kobayashi<sup>21)</sup> infused isosmotic (16.9% w/v) polyethylene glycol 4000 solution (PEG) into an isolated sac of rat upper jejunum. Between 6 and 72 hr after the PEG administration, the villi in the sac became shorter and a unique cellular cap was formed at their top (Fig. 4). This cellular cap was composed of many goblet cells and a few basal-granulated cells. Therefore, it was suggested that PEG infusion into the isolated intestinal sac in the rat resulted in severe damage to the enterocytes, whereas goblet cells and basal-granulated cells remained relatively intact. The PEG-induced formation of the peculiar cellular cap can be explained by the disturbance of the healthy dynamics of the epithelial cells of the intestine. Under normal condition the continuous escalator movements of the three kinds of intestinal epithelial cells terminate, and the cell loss takes place at the tip of the intestinal villi. However, if the life span of the enterocytes is greatly reduced as compared with that of the basal-granulated and goblet cells, only goblet and basal-granulated cells might be able to reach the top of the villi. As a result, the goblet and basal-granulated cells are assembled at the villus head and form a peculiar cellular cap.

An analogy between Segi's cap in the human fetus and the PEG-induced cellular cap in the isolated sac of rat small intestine may be possible.<sup>17)</sup> It is probable that Segi's cap is closely related to the development of basal-granulated cells and other types of epithelial cells in the gut, and especially to the peculiarity of their cell cycle in the prenatal period.<sup>20)</sup> Studies on the kinetics of the intestinal epithelial cells of the human fetus are necessary.



## SEGI'S CAP:

## FUNCTION OF SEGI'S CAP

The functional meaning of the occurrence of Segi's cap in the human fetus remains to be solved. It is fascinating to speculate that the basal-granulated cells in Segi's cap play a significant role in the physiology of the human fetus in the later half of pregnancy and in the perinatal period. In this sense the timing of the disappearance of Segi's cap should be studied. It may be possible that the timing of the disappearance of Segi's cap is related to lactation. During the intra-uterine life, fetal intestine produces and stores meconium. On the other hand, after birth the intestine starts to digest and absorb the mother's milk. Segi's cap may produce a set of hormones needed for the fetal intestine to adjust to the sudden and great change of the luminal content which must occur in the perinatal period.

The localization of Segi's cap at the very top of the villi seems most favorable for the perception of information in the intestinal lumen. Segi's cap may be receptor-endocrine organ specific to the later half of pregnancy and perinatal life and function as a monitor of the fetal environment. The fact that basal-granulated cells in Segi's cap are open in type and possess an apical process that reaches the epithelial surface may provide support for this idea. Segi's cap, as a fetal sensory organ, receives information from the external environment (i.e., chemical and physical changes of the intestinal lumen and in turn the amniotic fluid), and transmits it to the target organs such as nerves in the lamina propria mucosae in the form of gut hormones. Studies on the functional significance of the fetal intestine in the sanitation of the amniotic environment are required. The localization of Segi's cap on the very top of the villus seems most convenient for it to control the intestinal epithelium in the absorption of amniotic fluid, if this function really takes place.

Segi<sup>4,5)</sup> focused his attention on the endocrine cells in the epithelial tissue, hence his description of the histological structure of the connective tissue was not in detail. It is not clear whether Segi investigated nerves and lymphocytes of the area adjacent to Segi's cap. We have recently performed an electron microscope study of the lamina propria mucosae of the intestine in the human fetus. We found numerous autonomic nerves consisting of glial cells and neuronal projections (Fig. 5,6). These nerves formed a network that was entangled with blood vessels of the core of the villi. However, we found no significant number of lymphocytes, if any, in the lamina propria mucosae. We found no intraepithelial lymphocytes in the villi that possessed Segi's cap (Fig. 3,6). Further studies are needed to reveal the significance of the fact that, among the defensive systems of the intestinal villi, cells of the nervous and endocrine systems develop before those of the immune system. Thus, Segi's cap may provide unique material for the investigation of the developmental mechanisms of the defensive systems of the human body.

## REFERENCES

- 1) Grube, D.: Die endokrinen Zellen des Magendarmepithels und der Stoffwechsel der biogenen Amine im Magendarmtrakt. *Progr. Histochem. Cytochem.*, 8, 1–128 (1976).
- 2) Sundler, F. and Håkanson, R.: Peptide hormone-producing endocrine/paracrine cells in the gastro-entero-pancreatic region. In *The Peripheral Nervous System*, edited by Bjöklund, A., Hökfelt, T. and Owman, C.: *Handb. Chem. Neuroanat.*, 6, pp. 219–295 (1988), Elsevier, Amsterdam.
- 3) Fujita, T., Kanno, T. and Kobayashi, S.: The paraneuron. pp. 165–184 (1988), Springer-Verlag, Tokyo.
- 4) Segi, M.: Über eine aus Chromaffine-Darmzellen bestehende Struktur auf den Zotten von Menschenembryo. *Acta Anat. Nippon.*, 8, 276–280 (1935).
- 5) Segi, M.: Über die Entwicklung der verschiedenen Granulazellen im Darmepithel des Menschenembryo. *Acta Anat. Nippon.*, 9, 850–937 (1936).
- 6) Kobayashi, S., Iwanaga, T., Fujita, T.: Segi's cap: huge aggregation of basal-granulated cells discovered by

- Segi (1935) on the intestinal villi of the human fetus. *Arch. Histol. Jap.*, 43, 79–83 (1980).
- 7) Iwanaga, T., Kobayashi, S., Fujita, T. and Yanaihara, N.: Immunohistochemistry and ultrastructure of Segi's cap. *Biomed. Res.*, 1, 117–129 (1980).
  - 8) Solcia, E. and Sampietro, R.: Cytologic observations on the pancreatic islets with reference to some endocrine-like cells of the gastrointestinal mucosa. *Z. Zellforsch.*, 68, 689–698 (1965).
  - 9) Solcia, E., Vassallo, G. and Sampietro, R.: Endocrine cells in the antro-pyloric mucosa of the stomach. *Z. Zellforsch.*, 81, 474–486 (1967).
  - 10) Forssmann, W.G., Orci, L., Pictet, R., Renold, A.E. and Rouiller, C.: The endocrine cells in the epithelium of the gastrointestinal mucosa of the rat. An electron microscope study. *J. Cell Biol.*, 40, 692–715 (1969).
  - 11) Pearse, A.G.E., Coulling, I., Weavers, B. and Friesen, S.: The endocrine polypeptide cells of the human stomach, duodenum, and jejunum. *Gut*, 11; 649–658, 1970.
  - 12) Kobayashi, S., Fujita, T. and Sasagawa, T.: The endocrine cells of human duodenal mucosa. An electron microscope study. *Arch. Histol. Jap.*, 31, 477–494 (1970).
  - 13) Clara, M.: Die basalgekörnten Zellen im Darmepithel der Wirbeltiere. *Ergeb. Anat. Entw.*, 30, 240–340 (1933).
  - 14) Moxey, P.C. and Trier, J.S.: Endocrine cells in the human fetal small intestine. *Cell Tiss. Res.*, 183, 33–50 (1977).
  - 15) Yamada, J., Kuramoto, H., Iwanaga, T., Yamashita, T., Misu, M. and Yanaihara, N.: Segi's cap, a large aggregation of endocrine cells on the intestinal villi, occurs also in cattle and pig fetuses. *Arch. Histol. Jap.*, 44, 193–197 (1981).
  - 16) Ito, H., Yamada, J., Kitamura, N., Yamashita, T. and Yanaihara, N.: Histological and immunohistochemical studies of the Segi's cap, a large aggregation of endocrine cells on the intestinal villi of porcine fetuses and neonates. *Arch. Histol. Jap.*, 48, 399–409 (1985).
  - 17) Kobayashi, S. and Segi, M.: Gut paraneurons and Segi's cap. In *Ultrastructure of endocrine cells and tissues*. edited by Motta, P., pp. 127–135 (1984), Martinus Nijhoff Publ., Boston.
  - 18) Leblond, C.P.: The life history of cells in renewing systems. *Amer. J. Anat.*, 160, 114–158 (1981).
  - 19) De Bruine, A.P., Dinjens, W.N.M., Zijlema, J.H.L., Lenders M.H. and Bosman, F.T.: Renewal of enterochromaffin cells in the rat caecum. *Anat. Rec.*, 233, 75–82 (1992).
  - 20) Lehy, T., Grès, L. and Ferreira de Castro, E.: Quantitation of gastrin and somatostatin cell populations in the antral mucosa of the rat. Comparative distribution and evolution through different life stages. *Cell Tiss. Res.*, 198, 325–333 (1979).
  - 21) Clarke, R.M. and Kobayashi, S.: The cytological effects of infusion of luminal polyethylene glycol on the rat small intestinal mucosa. *Arch. Histol. Jap.*, 38, 133–150 (1975).