

DIGITAL RADIOLOGY AND PACS

TAKEO ISHIGAKI¹, MITSURU IKEDA², KAZUHIRO SHIMAMOTO¹, HIDEKI HIROTA¹,
and NAOKI MAKINO¹

¹Department of Radiology and ²Department of Medical Information and Medical Records, Nagoya University School of Medicine, Nagoya, Japan

ABSTRACT

Future hospital information systems should permit the systematic storage of all information generalized within the hospital, including medical diagnostic images. For such a system to be realized, implementation of a picture archiving and communication system (PACS) is needed. The development of computed radiography with an imaging plate (CR) has made it possible for digitalization of all kinds of projection radiographs, and thus for PACS to be realized. In this paper the clinical usefulness of CR and many factors required to realize PACS are described.

Key Words: Computed Radiography, CR, Picture archiving and communication system, PACS

INTRODUCTION

Advances in modern imaging technologies have produced huge amounts of image data to be managed in the radiology department (Table 1). To manage these large volumes of data, a system for the storage and control of medical images including a picture archiving and communication system (PACS) is needed. Recent digital diagnostic imaging techniques have made it

Table 1. Digital image data in Nagoya Univ. Hospital in near future.

MODALITY	NO. OF PATIENTS/DAY	NO. OF IMAGES /PATIENT	NO. OF IMAGE BYTES/DAY
XCT			
BODY (512X512)	12	25	157.3 MB
HEAD (320X320)	18	12	44.2 MB
NM			
STATIC(256X256)	13	2	2.6 MB
DYNAMIC(128X128)	2	5	0.3 MB
US (512X512)	10	10	26.2 MB
DSA (512X512)	3	8	6.3 MB
CR (2000X2000)			
CHEST	120	1.5	720.0 MB
OTHERS	135	2	1080.0 MB
MRI (512X512)			
HEAD	6	45	106.2 MB
OTHERS	7	60	165.2 MB
PET (256X256)	3	14	5.5 MB
TOTAL	324		2.3 GB

Correspondence: Dr. Takeo Ishigaki, Department of Radiology, Nagoya University School of Medicine, Showa-Ku, Nagoya 466, Japan.

possible to transfer, store, retrieve, and display various kinds of images under optimal image processing conditions. Conventional projection radiographs with a screen-film system also can be digitized using a specially designed digitizer. However, projection radiographs can be digitized directly using computed radiography with imaging plate. The development of the concept of computed radiography has made it possible for PACS to become a reality.

COMPUTED RADIOGRAPHY (CR)

Computed radiography with imaging plate was developed in Japan in 1980.¹⁾ The basic components of the system are the image sensor, called the imaging plate, which temporarily stores the X-ray energy pattern; the image reader, which converts the latent image on the imaging plate into analogue and subsequently into digital time-series signals; the image processor, which manipulates the image digitally; and the image recorder, which records the processed signals on film¹⁾ (Fig.1). The imaging plate is a flexible plate less than 1 mm thick that is coated with minute crystals of photostimulable phosphor in an organic binder. It can be employed as a substitute for the screen-film system in the conventional medical X-ray imaging system. Photostimulable phosphor is capable of storing the energy absorbed in quasi stable states when excited by X-rays, electrons, ultraviolet rays, etc., and of emitting luminescence radiation corresponding to the absorbed energy when stimulated by visible or infrared radiation. This phenomenon is called photostimulable luminescence (PSL). The imaging plate can be used repeatedly to store X-ray images simply by flooding it with light to erase the residual energy it contains. After the X-ray image is stored on the imaging plate, it is scanned with a 633 nanometer helium-neon laser beam to produce PSL radiation corresponding to the absorbed X-ray energy, and this is then converted to time-series signals by a photodetector. The signal output from the detector is an analogue signal identified as a function of time, and the output from the analogue to digital converter is the time-series digital signal that is being processed. The image signals that are sent

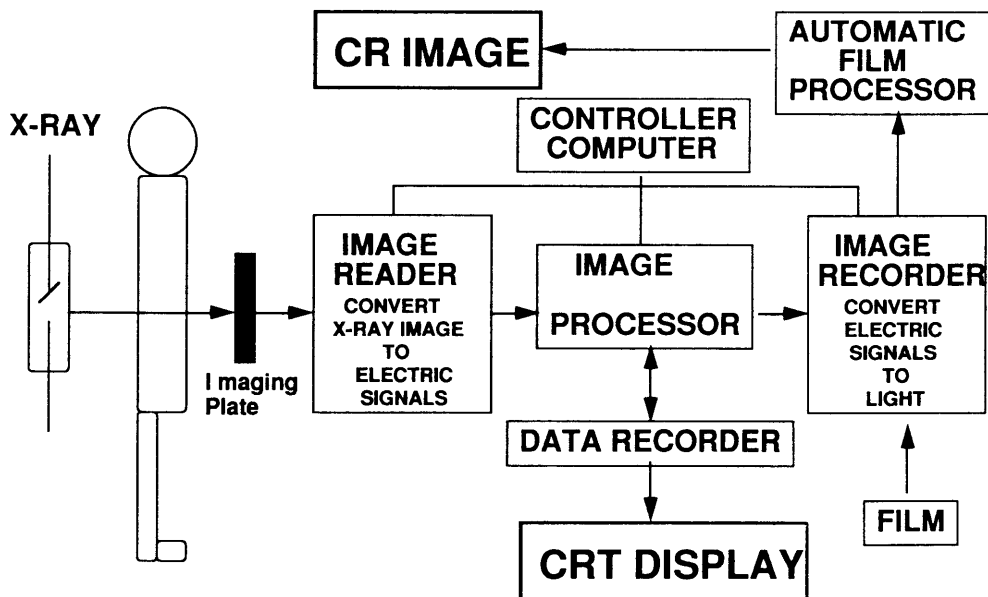


Fig. 1. Block diagram of CR system.

into the image processor are processed digitally. Then the image recorder converts the processed digital signals back into analogue signals.

The advantages of the CR system compared with the conventional film-screen system are as follows:

First, the dependence of the amount of light emission from the imaging plate on the irradiation dose of X-rays shows a good linearity over a wide range of over $1:10^4$ from a low to a high dose, and a constant optimum density can be attained whenever any quantity of X-ray exposures are being made.

Second, the CR system improves image quality by image processing, such as zooming, reversal mode procedure, contrast enhancement, spatial frequency enhancement, and subtraction procedures (Fig.2). The potential disadvantages of CR include the reduced spatial resolution. However, several authors have reported that CR images were diagnostically comparable to or sometimes superior to the screen-film images on chest image and other X-ray images, and the usefulness of the CR system compared with the conventional film-screen system has been reported.^{2,3,4,5} One possible explanation for these results is that the greater contrast sensitivity obtained from various image processing techniques may compensate for the lesser spatial clarity. The special image procedure in the CR system is the dual-energy subtraction technique. There are two approaches to energy subtraction: a single X-ray exposure (one-shot dual energy)⁶ and double X-ray exposures.⁷ The one-shot dual-energy subtraction method is simpler than the double-exposure method because it does not require switching the X-ray tube voltage with a specially designed apparatus. In the one-shot dual-energy subtraction method a copper filter is placed between two imaging plates in one cassette to separate the effective energy of the X-ray spectrum between the X-rays absorbed in both imaging plates. Thus, low- and high-energy images can be obtained simultaneously (Fig.3). The subtracted image was made from two original images multiplied by weighting factors. Any kind of conventional radiographic imaging apparatus is available for one-shot dual-energy subtraction in the CR system. Another advantage of the

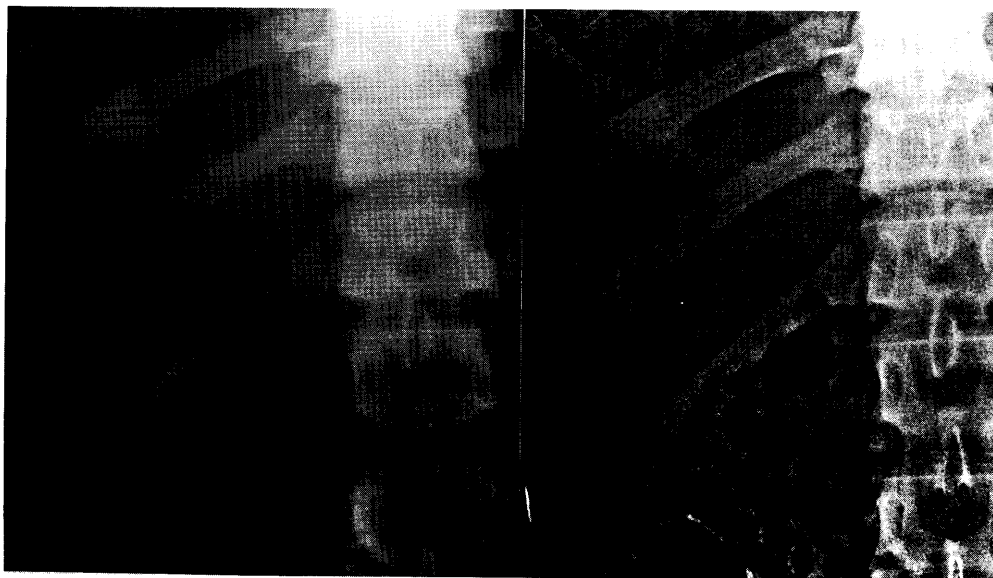

Fig. 2-a

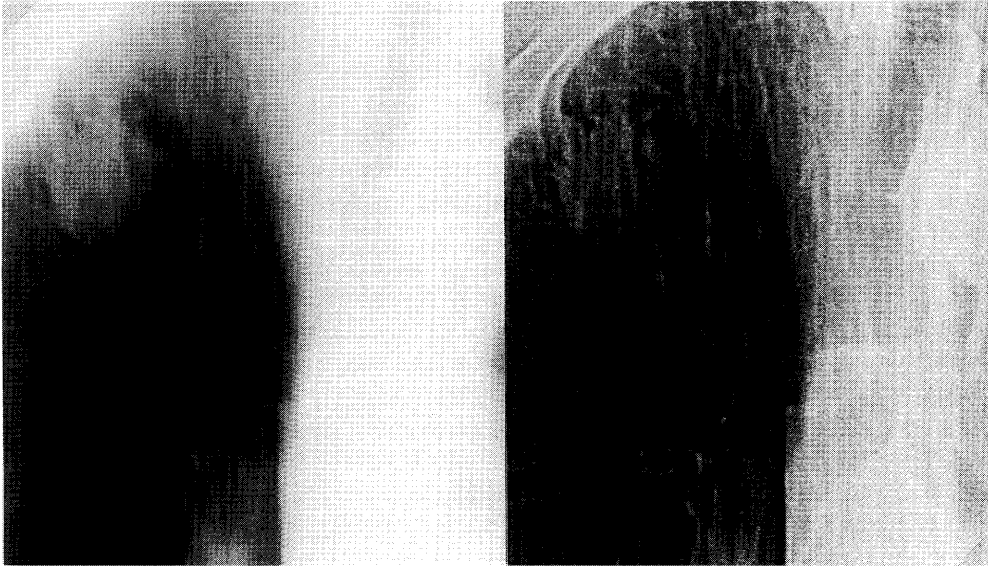


Fig. 2-b

Fig. 2. Plain CR images of abdomen (a), and CR chest tomogram (b).

Left images are processed with an algorithm simulating conventional radiography, and right images are processed with an algorithms enhancing contrast and spatial frequency in 2-a and 2-b.

2-a: Lipoma in the liver. Low density lesion (arrow) is more clearly seen on the right-side processed image.

2-b: Lung cancer. Processed images on the right side visualize tumor and mediastinal structures more clearly.

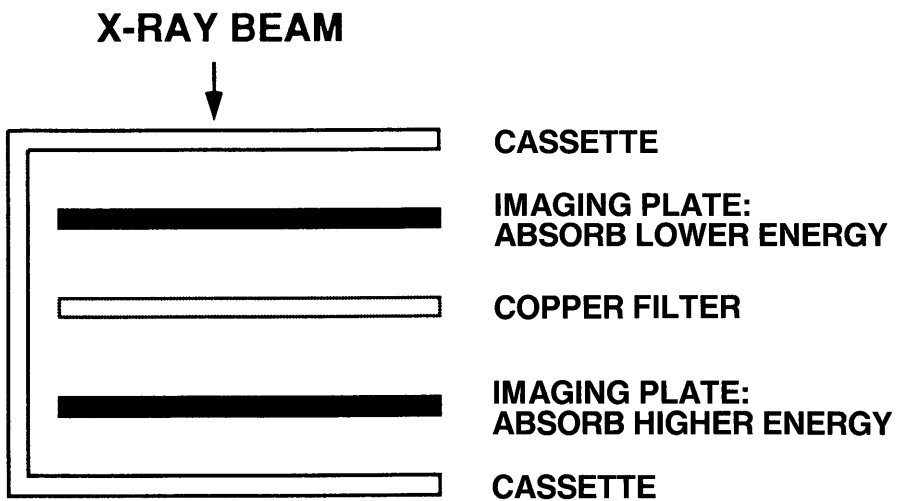


Fig. 3. One-shot dual-energy subtraction.

A copper filter is placed between the two imaging plates in the cassette. The first imaging plate absorbs the lower-energy x-ray photons. The higher-energy x-ray photons, filtered by a copper filter and the first imaging plate, are absorbed in the second imaging plate.

one-shot method is less misregistration caused by motion artefact. In analyses of chest images of 140 patients, new information, not detected on the original plain CR images, was obtained on subtraction images in 21 patients (15%)⁸. Receiver operation characteristic curve (ROC) studies also verified the superiority of CR subtraction over the original plain CR images for the detection of pulmonary nodules, especially nodules hidden under the ribs, calcification in a nodule, and rib lesions⁸ (Fig.4, 5).

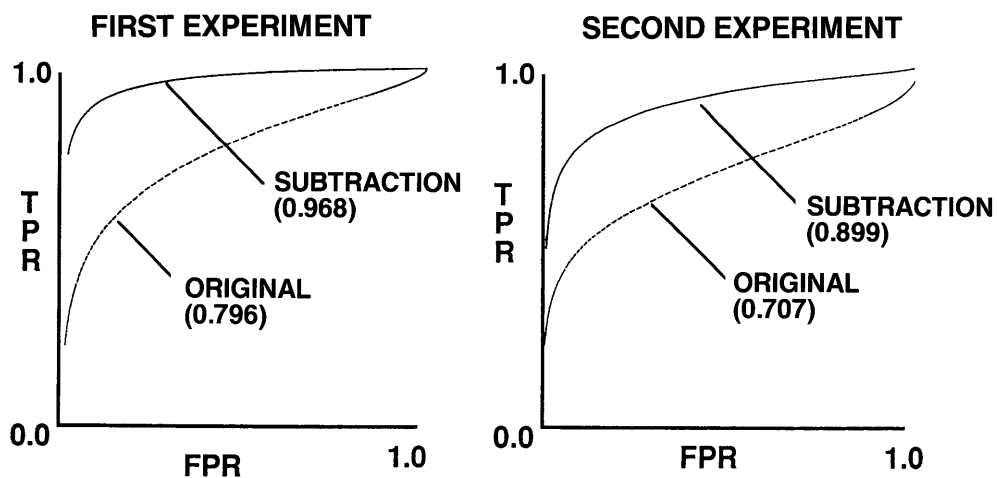


Fig. 4. ROC curves in two different studies show the superiority of CR subtraction over the original plain chest CR imaging in detecting pulmonary nodules, rib lesions and abnormal calcification. Number in parentheses shows area under the ROC curve.

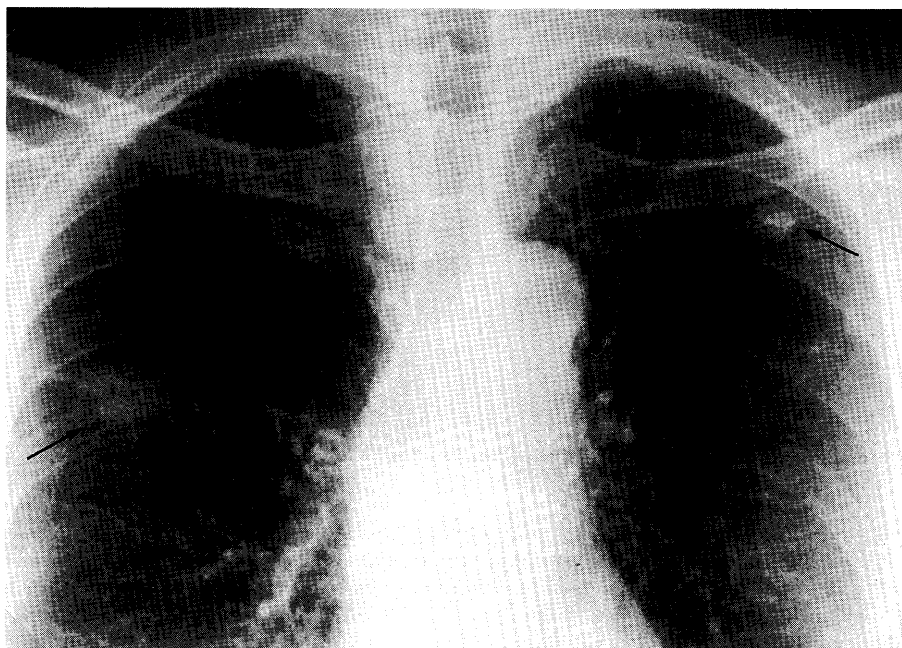


Fig. 5-a

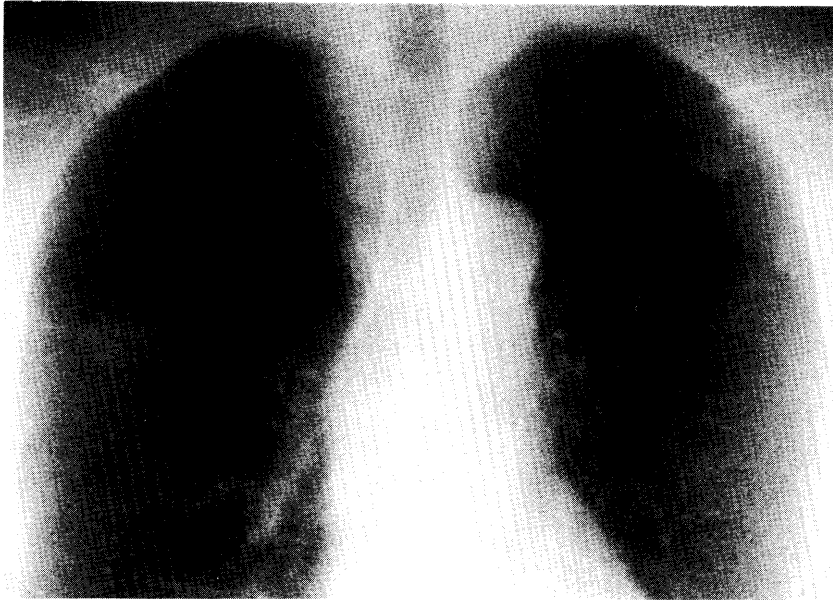


Fig. 5-b

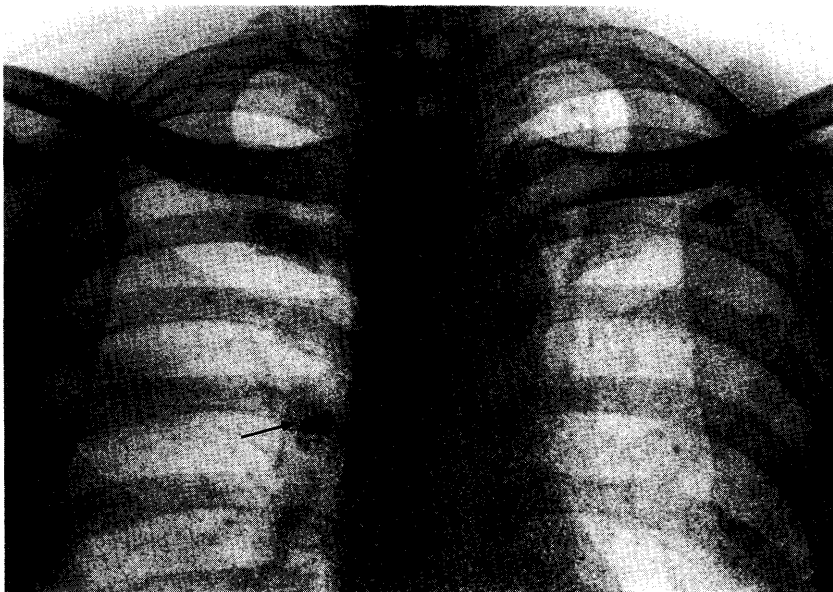


Fig. 5-c

Fig. 5. Plain chest CR image (a) shows two nodules (arrows) in right and left upper lobes. Both nodules are clearly visualized on the bone-subtracted image (b). On the soft-tissue subtracted image (c), however, the nodule located in the right upper lobe is not visualized because it does not contain any calcification, and the left one is visualized, showing calcium-containing nodule. Calcified lymphnode in right hilum (arrow), which is not identified on a plain CR image (a), became visualized.

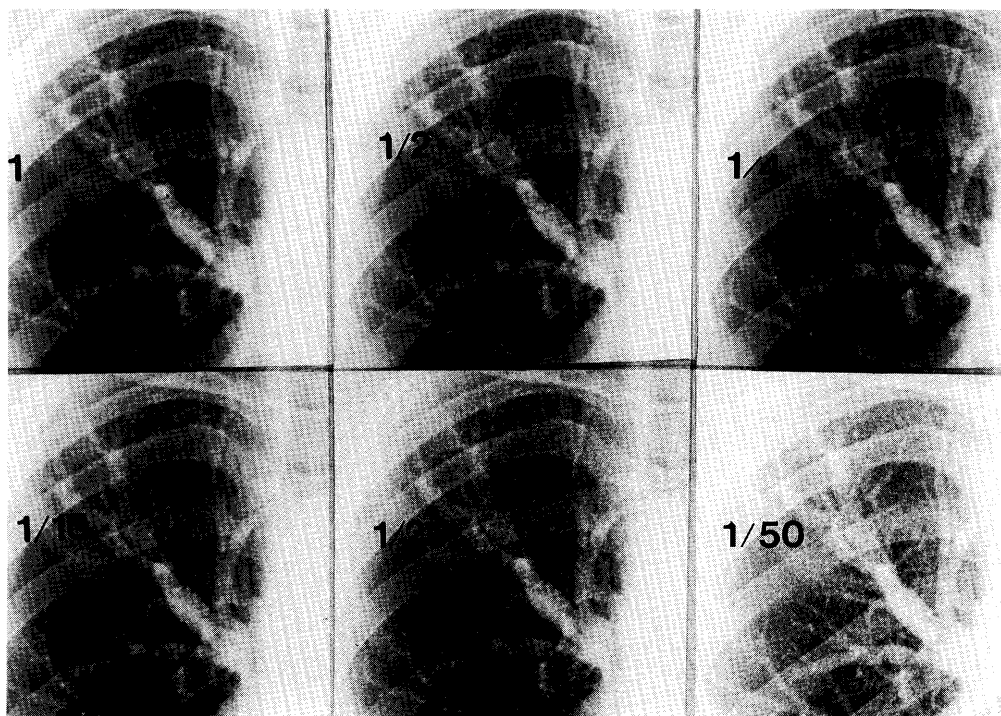


Fig. 6. CR chest phantom images taken under various kinds of exposure doses. The number in each image shows the reduction ratio of exposure dose. With a reduction of exposure dose, images become noisier.

Third, several authors have reported the possibility of dose reduction with the CR system⁵⁾ (Fig.6). In the field of chest radiography, Yamada documented that radiography with CR was possible at an X-ray dose equivalent to 1/20 of the conventional dose level. He also documented a radiation dose reduction to 1/20 in barium examination of the upper GI tract. Nishitani et al. claimed CR provided imaging of the same quality at half the X-ray dose compared with the conventional rare-earth intensifying film-screen system.

Fourth, CR is a suitable and important digital technique for implementation of PACS because plain radiographs and other projection radiographs are the most frequently obtained images in the diagnostic radiology department.

CATHODE RAY TUBE (CRT) DIAGNOSIS

One of the major requirements for implementation of PACS is that the information of CR must be equal to or better than that of the existing film images. The images must be displayed on CRT without loss of information. We have previously reported the possibility of CRT diagnosis using an image data processing unit (TD1S-File 500B, Toshiba, Tokyo). This system has 1600 MB of image storage and 96 MB of image memory with 20-inch 1635-line monitors. A CRT has a spatial resolution of 1024×1536 and a gray level resolution of 8 bits. There was no significant difference between CR film images and CR CRT images in observer performance study in detecting the abnormalities on chest radiographs⁹⁾ (Fig.7). On four-fold direct magnifi-

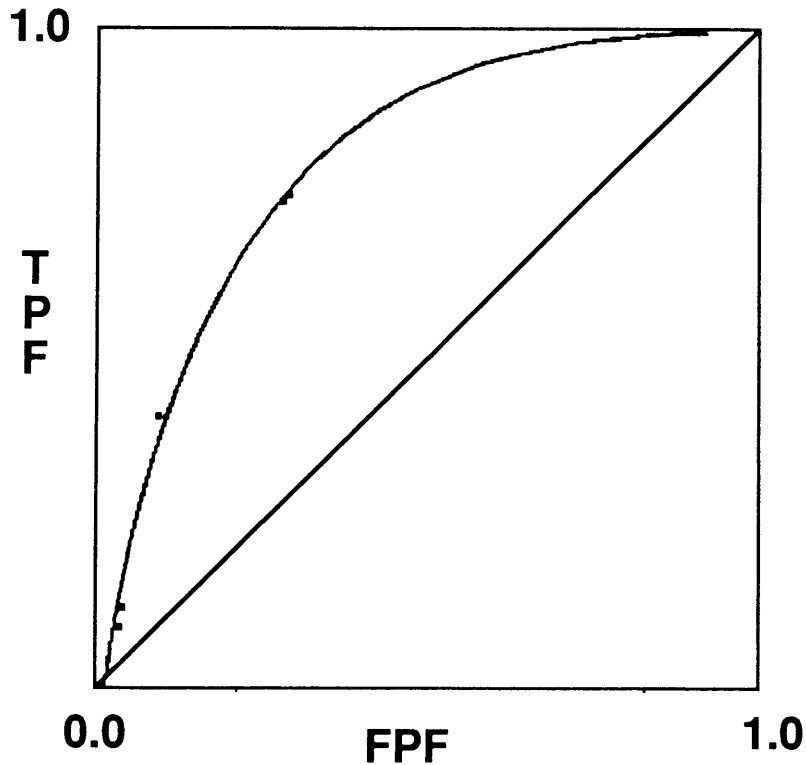


Fig. 7. ROC study in detecting pulmonary abnormalities by 24 observers: Chest images on CRT vs. film. No difference was found between the two images. Both ROC curves overlapped each other. Area under the ROC curve : CRT = 0.823, film = 0.826

cation sialograms, there was no significant difference of image quality between CR film images and conventional screen-film images. CR CRT-images surpassed conventional screen-film images and sometimes CR film images as well.¹⁰⁾ On lymphangiograms, CR film images were not necessarily superior to conventional screen-film images. However, CR film images sometimes surpassed conventional screen-film images when the lymphnodes were located over the spine. CR CRT images were equal or sometimes superior to conventional film-screen images; two thirds of CR CRT images were superior when the lymphnodes were located over the spine. CR CRT images surpassed CR film images. On the CRT the desired images can be displayed in various formats. As CR system images are originally digital, the CRT display has more advantages than the film display for the interpretation of images. Various kinds of image processing can be done as desired. With the availability of interactive control of CRT setting, optimal images can be obtained on a CRT. When a CR image is displayed on film, efficient use of the special qualities of digital images cannot be made. CRT display of CR images with capability of an appropriate image-processing technique can make the global diagnosis less dependent on those distinctive features that require high spatial resolution.

EVALUATION OF EXPERIMENTAL PACS

In April of 1989 an experimental PACS was installed in the Nagoya University Hospital. The system consisted of three TDIS FILES, and two high-resolution CRTs were connected to each TDIS- FILE. These units were connected to each other, making it possible to transfer image and information data. Two of the three TDIS-FILES were installed in the central clinic of radiology (central workstation), which collected various kinds of images originating from X-ray computed tomography (CT), computed radiography (CR), isotopic imaging including SPECT, ultrasonography, and film digitizer. Another TDIS-FILE was installed in the conference room of the radiology department, which is located one floor below and 300 m away from the central workstation. In the outpatient clinic of radiology, one console was installed that is connected to the TDIS-FILE in the central workstation.

Performance studies of the experimental PACS were carried out for the evaluation of the system. CR images were transmitted directly to the workstation in the radiology outpatient clinic a few minutes after the examination. The time interval between the ordering of chest image and the viewing of images was about 30 min shorter as compared with the CR film system. This means that the time interval from when the examination was completed until when a radiologist viewed the image became shorter with this system than with the CR film system, in which it took about 30 min to process CR images and to carry the images from the central radiology department to the radiology outpatient clinic. In the experiment of CT reading as a routine daily task, the average time required to interpret one CT image on CRT was longer than with the average time on film reading (Tables 2 and 3).¹²⁾ Prolongation of reading time was more evident in the body CT examination series than in the head CT series, because as the mean number of CT images in the study was 14 in the head CT series and 35 in the body CT series, simultaneous display of multiple CT images was not possible on only two CRT workstation monitors. On the other hand, simultaneous display of multiple CT images including the contrast enhancement series was easily done with the use of film on the view box. The prototype CRT workstation lacked the capability of rapid visual comparison for multiple CT images. The prolongation of the reading time was also affected by the time required to retrieve and arrange the multiple CT images on the CRT and the amount of manipulation required to achieve the desired display of the image. The average time required to interpret CT images was influenced by the room illuminance.¹²⁾ The time was longer under room illuminance of 50 lux than under 170 lux. The room illuminance also influences the detectability of low contrast details on plain CR chest images. In ROC study in the detection of pulmonary small nodules measuring between 3 and 10 mm in diameter under three kinds of room illuminance, 70, 170, and 480 lux, all observers

Table 2. Average times to read one image (head CT).

The number in parentheses shows time (m) required to read one case (average: 14 images)

Reader	Time (m) / 1 Image	
	Film	CRT
A	0.18 (2.5)	0.39 (5.5)
B	0.44 (6.1)	0.64 (8.9)
C	0.34 (4.8)	0.48 (6.8)
D	0.75 (10.4)	0.88 (12.3)
E	0.51 (7.1)	0.87 (12.2)

Table 3. Average times to read one image (body CT).
The number in parentheses shows time (m) required to read one case (average: 14 images)

Reader	Time (m) / 1 Image	
	Film	CRT
F	0.38 (13.3)	0.93 (32.7)
G	0.26 (9.1)	0.60 (21.0)
H	0.30 (10.5)	0.49 (17.1)
I	0.41 (14.3)	1.11 (38.8)

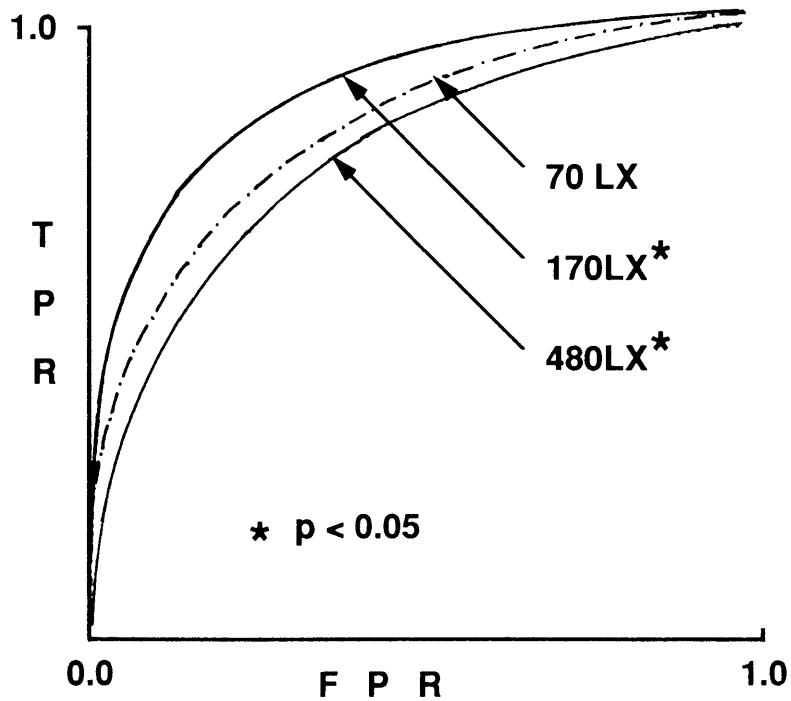


Fig. 8. ROC curves show a statistical significance ($p < 0.05$) between illuminance at 170 lux and 480 lux. Under illuminance of 170 lux observers can detect pulmonary nodules more precisely.

DIGITAL RADIOLOGY AND PACS

performed better at an illuminance of 170 lux than at 480 lux. Average ROC curves also showed a statistical significance ($p < 0.05$) between illuminance at 170 lux and 480 lux (Fig.8).¹²⁾ The ambient light level should be taken into consideration and be kept at a lower level of about 170 lux, although it must be adapted to the individual visual performance.

NEWLY DESIGNED PACS

Based on the results of our experimental PACS, in April of 1992 a newly designed PACS was installed in the Nagoya University Hospital (Fig.9). The main purpose of the new PACS is to minimize the operator key board entry, to improve the flow of information by predicting image retrieval characteristics, to design an image data base analogous to pulling film jackets and storing films in the conventional film library, and to integrate the PACS and the hospital information system with the micro-mainframe-link architecture. CRT workstations, consisting of three or six CRT monitors, were installed in the conference room of the radiology department, in the outpatient clinic of radiology, and in the intensive care unit (Fig.10). The performance studies of the renewed PACS are on-going.

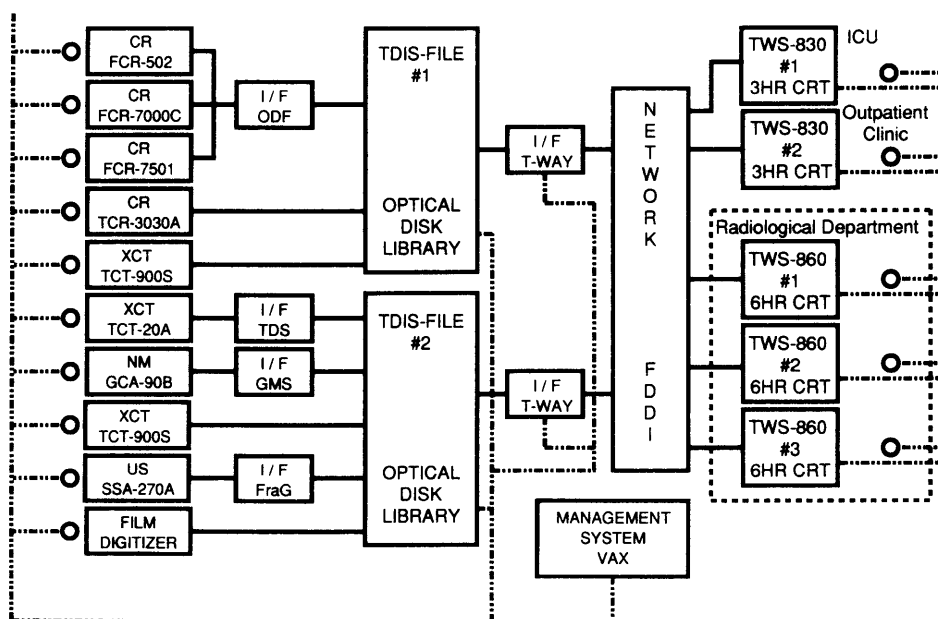


Fig. 9. Block diagram of newly developed PACS in Nagoya University Hospital.

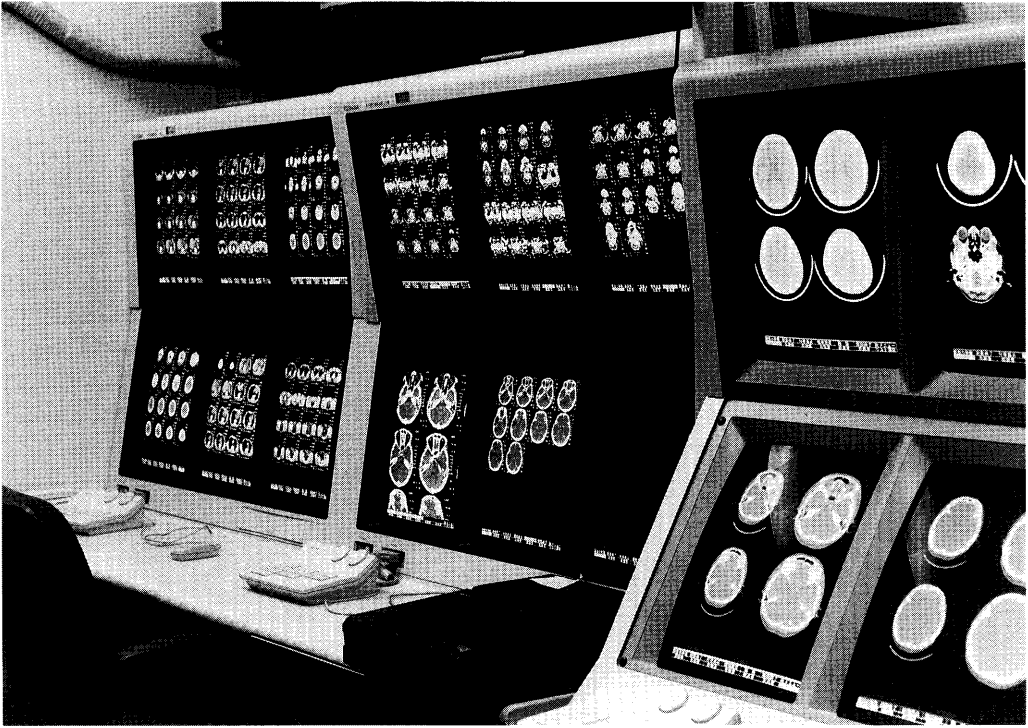


Fig. 10. Newly developed CRT workstations with six CRT monitors.

RADIOLOGY INTELLIGENT INFORMATION SYSTEM

PACS must be an integral part of the total hospital information system to store, display, retrieve, and transmit clinical imaging because clinical diagnostic images make up a large proportion of the information within a hospital. In the near future, the concept of Hospital Intelligent Information System (HIIS) must be established and realized. The objective of HIIS is the functional integration of all hospital information and the efficient management and use of this information to improve the quality of patient care and hospital services. With the construction of HIIS, data will be available on a real-time basis, the quality of diagnosis will be checked independently, and patients will not have to wait in each department for a long time. In implementing this total HIIS we are going to design and construct a diagnostic and therapeutic radiology system, named "Radiology Intelligent Information System (RIIS)". RIIS is composed of a radiation oncology information system and a diagnostic radiology information system (Fig.11). The latter is named "Imaging Diagnosis Intelligent Information System (IDIIS)". IDIIS consists of three parts: (a) PACS, (b) Report Generation Support System for Imaging Diagnosis (RGSS-ID), and (c) Imaging Diagnosis Management System (IDMS). RGSS-ID is currently being developed, in which artificial intelligence (AI) methods are applied to the radiological reporting system. IDMS includes ordering, scheduling, and image management to deliver images and the corresponding radiological reports to terminal workstations. AI is also applied to ordering and scheduling. In the ordering system AI is used to support the selection of radiological examination to be performed. The first step is entering diagnostic hypotheses, symptoms and signs of a patient. Then, the system suggests various imaging examinations which need to be performed to

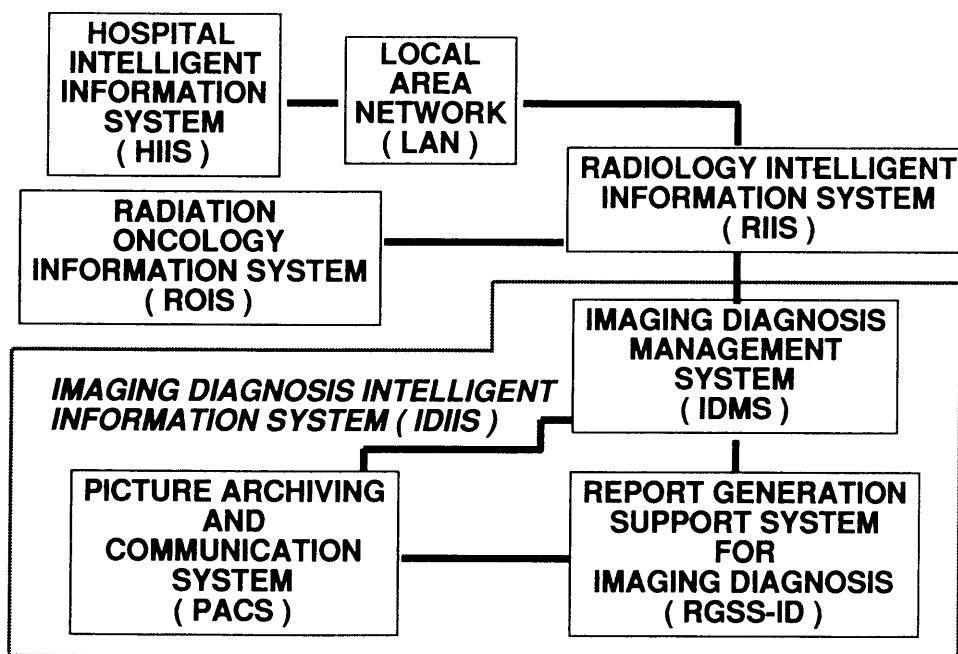


Fig. 11. The concept of Radiology Intelligent Information System (RIIS).

arrive at a definite diagnosis, or provides a diagnostic list consistent with the clinical features. In the scheduling system AI is used to optimize the scheduling of imaging examinations. In this process, proposals for the order in which patients are scheduled for radiological examinations are offered on the basis of diagnostic hypothesis, symptoms and signs of the patient. Furthermore, the system offers a schedule of the order of the multiple imaging modalities; for examples, XCT of the abdomen should not be scheduled within a few days after a barium study of the upper GI tract.

IDMS will be linked with the Host Computer of HIIS and will manage the images with their corresponding report, transferring them to each terminal workstation according to need for clinicians to look at them. Images sent to IDMS are not the originals but are processed, compressed and recreated at the PACS workstation. With regard to compression ratio, plain CR chest images with a compression ratio of 10:1 are quite acceptable and the upper-limit compression ratio is 20:1 at the greatest.¹¹⁾ ROC studies showed that a compression ratio of 25:1 is not acceptable (Fig.12). Although there are many unresolved questions regarding the linkage between HIIS and RIIS, the use of data from HIIS is indispensable for the proper management of IDIIS database. Furthermore, IDIIS has an important role to play in improving the quality of patient care and medical education as well as in image management and is an essential component for the implementation of HIIS.

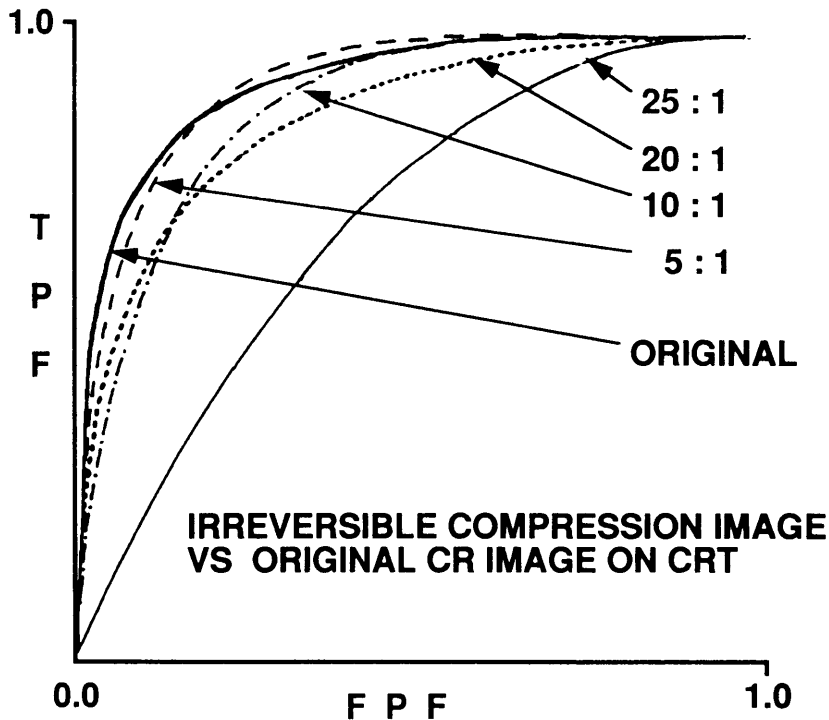


Fig. 12. ROC studies in detecting pulmonary abnormalities on CR CRT chest images compressed at various compression ratios. A compression ratio of 25:1 is not acceptable in clinical use.

REFERENCES

- 1) Sonoda, M., Takano, M., Miyahara, J., and Kato, H.: Computed radiography utilizing scanning laser stimulated luminescence. *Radiology*, 148, 883–838(1983).
- 2) Nakano, Y., Togashi, K., Nishimura, K., Itoh, K., Fujisawa, I., Asato, R., Adachi, H., Itoh, H., and Torizuka, K.: Stomach and duodenum: Radiographic magnification using computed radiography (CR). *Radiology*, 160, 383–387(1986).
- 3) Fajardo, L.L., Hillman, B.J., Hunter, T.B., Claypool, H.R., Westerman, B.R., and Mockbee, B.: Excretory urography using computed radiography. *Radiography*, 162, 345–351(1987).
- 4) Nakano, Y., Hiraoka, T., Togashi, K., Nishimura, K., Itoh, K., Fujisawa, I., Sagoh, T., Minami, S., Itoh, H., Torizuka, K.: Direct radiographic magnification with computed radiography. *AJR*, 148, 569–573(1987).
- 5) Tateno, Y., Inuma, T., and Takano, M.: *Computed Radiography*. pp.7–30(1987) Springer-Verlag, Tokyo.
- 6) Ishigaki, T., Sakuma, S., Horikawa, Y., Ikeda, M., and Yamaguchi, H.: One-shot dual-energy subtraction imaging. *Radiology*, 161, 271–273(1986).
- 7) Nishitani, H., Umezumi, Y., Ogawa, K., Yuzuriha, H., Tanaka, H., and Matsuura, K.: Dual-energy projection radiography using condenser X-ray generator and digital radiography apparatus. *Radiology*, 161, 533–535(1986).
- 8) Ishigaki, T., Sakuma, S., and Ikeda, M.: One-shot dual-energy subtraction chest imaging with computed radiography: Clinical evaluation of film images. *Radiology*, 168, 67–72(1988).
- 9) Itoh, Y., Ishigaki, T., and Sakuma, S.: The evaluation of digital X-ray images on CRT monitor display. *Nippon Act. Radiol.*, 48, 1024–1031(1988).
- 10) Ishigaki, T., Sakuma, S., Maruyama, K., Yamakawa, K., Ikeda, M., and Mashita, S.: CRT images of projection radiographs: Comparison with film images. *Med. Imag. Technol.*, 7, 334–343(1989).

DIGITAL RADIOLOGY AND PACS

- 11) Ishigaki, T., Sakuma, S., Ikeda, M., Itoh, Y., Suzuki, M. and Iwai, S.: Clinical evaluation of irreversible image compression: Analysis of chest imaging with computed radiography. *Radiology*, 175, 739–743(1990).
- 12) Itoh, Y., Ishigaki, T., Sakuma, S., Hirose, M., Fukatsu, H., Itoh, S., Horikawa, Y., Shimamoto, K., Tadokoro, T., Ikeda, M., and Itoh, K.: Influence of CRT workstation on observer's performance. *Comp. Methods. Progr. Biomed.*, 37, 253–258(1992).