

MORPHOLOGICAL STUDIES ON MIDDLE EAR BAROTRAUMA IN GUINEA PIGS

SHIGENORI SATO, HISASHI YOKOI, SHIGEJI FUKUTA,
MAKOTO KOZUKA and NORIYUKI YANAGITA

Department of Otorhinolaryngology, Nagoya University, School of Medicine, Nagoya, Japan

ABSTRACT

Experimental middle ear barotrauma was studied morphologically. White guinea pigs were placed in an experimental hyperbaric chamber, and middle ear barotrauma was created by increasing the pressure in the hyperbaric chamber from 1 atmosphere absolute (ATA) to 2 ATA using pure oxygen, maintaining the pressure at 2 ATA for 10 minutes, then again reducing the pressure to 1 ATA. Selected experimental animals were decapitated immediately after, one day after, one week after, or two weeks after pressure loading, and their middle ears were examined by a light microscope (LM), a scanning electron microscope (SEM) and a transmission electron microscope (TEM). Hemorrhaging in the tympanic cavity immediately after pressure exposure was apparent even macroscopically. LM also revealed evidence of submucous hemorrhage. Submucous edema was seen in the "one week after" cases. SEM showed a minor loss of cilia in some ciliated cells just after the experiment. In nonciliated cells, the terminal web was somewhat indistinct in the "one week after" cases. TEM also indicated a minor loss of cilia in some ciliated cells in "one day after" cases as well as apparent vacuoles within the cells. These findings suggest that although trauma during compression is more marked than during decompression, recovery from this damage progressed with time.

Key Words: Barotrauma, Middle ear, Submucous hemorrhage, Submucous edema, Loss of cilia

INTRODUCTION

The authors have already reported results of inner ear barotrauma experiments in guinea pigs,¹⁻⁷⁾ but organized reports with respect to middle ear lesions have yet to be done. Middle ear barotrauma is often seen in clinical practice. It is also closely related to sports divers, airline employees and passengers, and results in otitis media. This paper describes morphological observations regarding the lesions associated with this middle ear injury, to testify about the healing process of experimental middle ear barotrauma and to clarify whether this damage is more severe during compression or decompression.

MATERIALS AND METHODS

A total of 192 white guinea pigs (with body weights between 180 and 250g) with normal Preyer's reflex were used. Middle ear barotrauma was created using an experimental hyperbaric chamber. The inside pressure was elevated with pure oxygen from 1 atmosphere absolute

Correspondence address: Toyota Memorial Hospital, 1-1, Heiwa-cho, Toyota, Aichi 471, Japan

TEL: (0565)28-0100

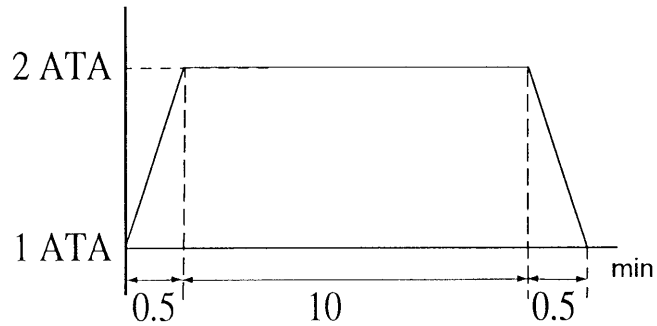
FAX: (0565)24-7170

(ATA) to 2 ATA, maintained at 2 ATA for 10 minutes, then returned to 1 ATA. The guinea pigs were divided into three groups in which compression and decompression were performed with the following variations in time course (Fig. 1):

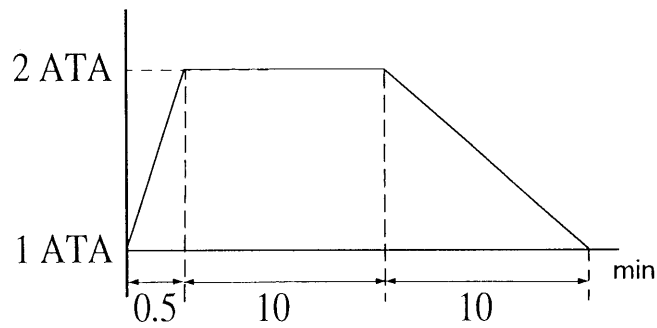
Group 1: pressure was increased over 30 seconds and decreased over 30 seconds.

Group 2: pressure was increased over 30 seconds and decreased over 10 minutes.

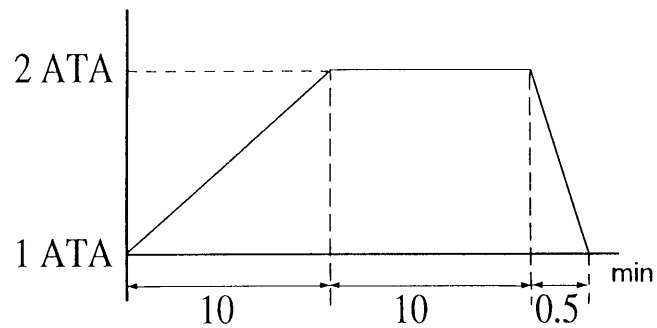
Group 3: pressure was increased over 10 minutes and decreased over 30 seconds.



Group 1



Group 2



Group 3

Fig. 1 Profile of atmospheric pressure change

MIDDLE EAR BAROTRAUMA IN GUINEA PIGS

Eight animals in each group were decapitated either immediately after, one day after, one week after, or two weeks after the pressure loading, where upon the tympanic mucous membrane and epithelium of the Eustachian tube were examined with a light microscope (LM). Furthermore, in Group 1 cases only, the surface structure of the mucous membrane was examined with a scanning electron microscope (SEM) and the microstructure of the mucocytes was examined using a transmission electron microscope (TEM).

Specimens for LM were prepared by excising the tympanic bullas then fixing them with 10% formalin through small holes made in the bullas. Specimens were decalcified with 10% EDTA and dehydrated with alcohol. The alcohol was then removed using xylol and the specimens were embedded in paraffin. Serial sections were prepared and stained using hematoxylin and eosin. Specimens for SEM were made by local irrigation with a phosphate-buffered 2.5% glutaraldehyde through small holes made in the bullas, followed by fixing with the same solution used for LM along with 2% tannic acid and phosphate-buffered 2% osmium acid. Thereafter specimens were dehydrated in ascending grades of alcohol (50 to 100%), transferred to isoamyl acetate, subjected to critical point drying (Hitachi HCP-2) and gold metallization by an ion coater (Eiko IB-3). Ciliated and nonciliated cells were then examined by SEM (Jeol JSM-5300). To obtain specimens for TEM, the tympanic bullas were irrigated with a phosphate-buffered 2.5% glutaraldehyde and 2% paraformaldehyde. Fixing was then accomplished using the same solution with phosphate-buffered 2% osmium acid. After this procedure, specimens were dehydrated in a series of alcohols and embedded in Epon 812 according to standard laboratory procedures. After thin sections had been prepared and stained twice with uranyl acetate and lead citrate, the specimens were then examined by TEM (Hitachi H-300).

Table 1 Macroscopic and light microscopic findings (in each group)

Hemorrhage in the tympanic cavity (n = 8)

	immediately after	one day after	one week after	two weeks after
Group 1	8	8	8	2
Group 2	8	8	8	1
Group 3	8	8	3	0

Submucous hemorrhage (n = 8)

	immediately after	one day after	one week after	two weeks after
Group 1	8	8	8	6
Group 2	7	7	7	5
Group 3	5	5	4	3

Submucous edema (n = 8)

	immediately after	one day after	one week after	two weeks after
Group 1	0	0	7	7
Group 2	0	0	7	7
Group 3	0	0	4	3

RESULTS

In Group 1, the macroscopic feature was tympanic cavity hemorrhage (Fig. 2) immediately after pressure stress in all cases; coagulation was also observed in some animals. In the "one week after" cases, these findings had diminished. In the "two weeks after" cases, six of eight cases did not show any damage. In Group 2, tympanic cavity hemorrhage was apparent and coagulation similar to that seen in Group 1 was also seen in some specimens. In the "one week after" cases, tympanic cavity hemorrhage had diminished. In the "two weeks after" cases, seven of eight did not show any abnormalities. In Group 3, hemorrhaging was apparent immediately after the experimental trial, although the extent was minor. There was no coagulation noted. In the "one week after" cases, five of eight did not show any hemorrhage. In the "two weeks after" cases, no hemorrhage was visible in any specimen. Although there were some animals in each of the three groups that exhibited partial or total loss of Preyer's reflex immediately after the pressure change, tympanic cavity damage did not differ from those with a favorable Preyer's reflex response. Perforation of the tympanic membrane was not seen.

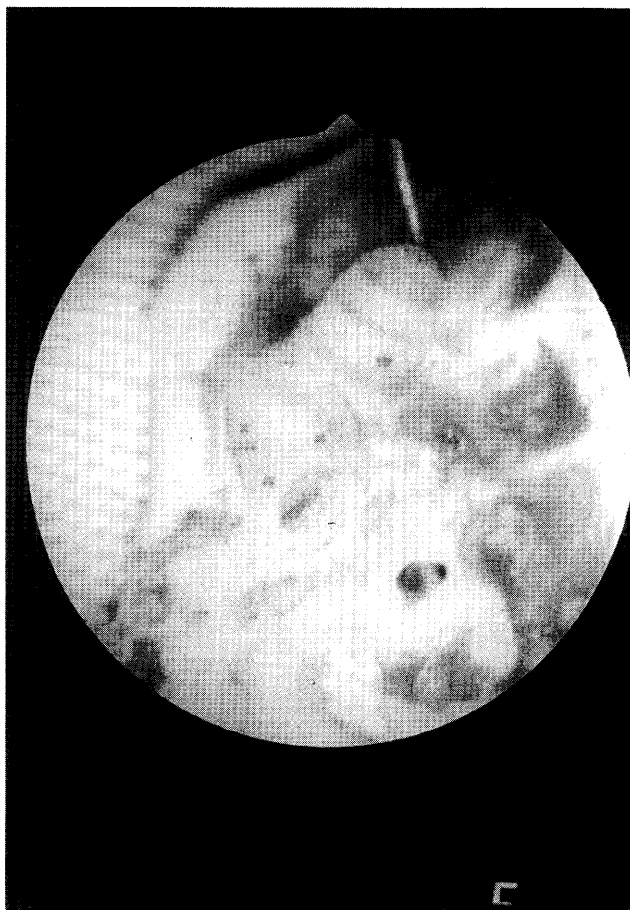


Fig. 2 Hemorrhage in the tympanic cavity immediately after pressure loading

MIDDLE EAR BAROTRAUMA IN GUINEA PIGS



Fig. 3 Submucous hemorrhage immediately after pressure load



Fig. 4 . Submucous edema one week after pressure change

LM revealed a submucous hemorrhage (Fig. 3) immediately after pressure load in all eight animals in Group 1, in seven of eight in Group 2, and in five of eight in Group 3. In the “one week after” cases, this injury had diminished but submucous edema existed (Fig. 4). Edema occurred in seven of the eight specimens in Groups 1 and 2, and in four of the eight specimens in Group 3. All cases in Groups 1 and 2, as well as seven of the eight in Group 3, showed elevated erythrocyte counts in the tympanic cavity immediately after the experiment, but these levels decreased gradually. There was no significant change on the epithelium of the Eustachian tube in any one of these groups during the whole two weeks period (Fig. 5) (Table 1).

SEM showed ciliated and nonciliated cells⁸⁻⁹⁾ in Group 1. Some ciliated cells lost cilia to a slight degree immediately after hyperbaric exposure (Fig. 6). One week after exposure, slight cilia loss was noted in some ciliated cells. Two weeks after exposure, the ciliated cells regained

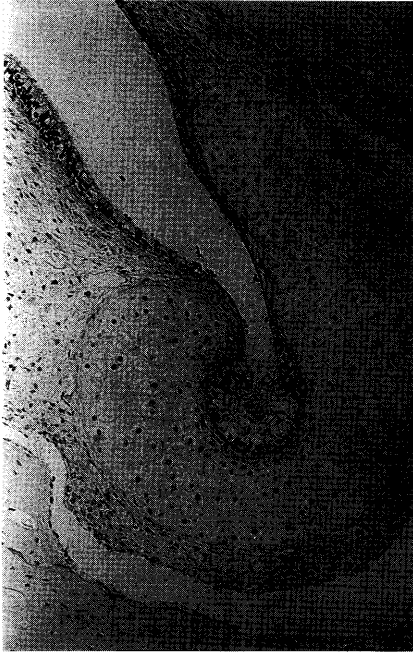

Fig. 5 There were no significant changes in the epithelium of the Eustachian tube

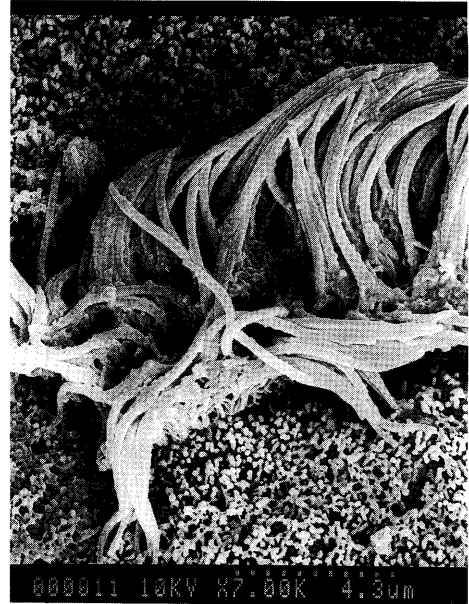

Fig. 6 Some ciliated cells lost cilia to a slight degree immediately after hyperbaric exposure

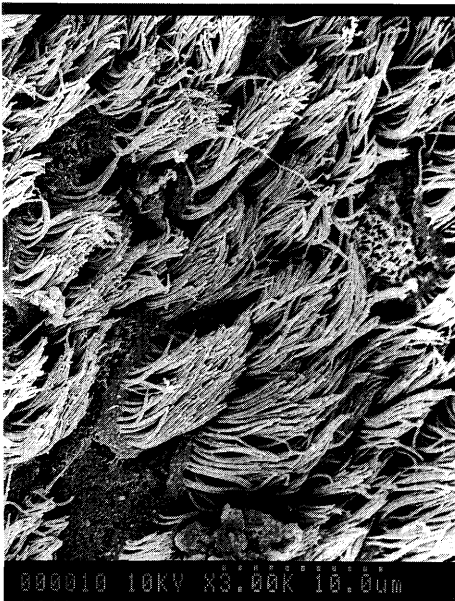

Fig. 7 Two weeks after, ciliated cells regained lost cilia

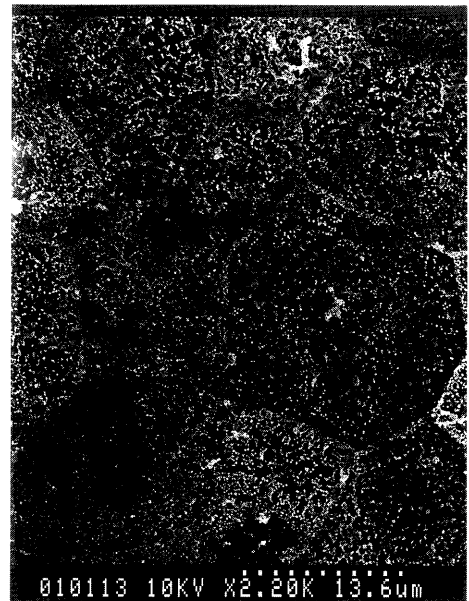


Fig. 8 The terminal web for nonciliated cells was somewhat indistinct one week after the experiment

MIDDLE EAR BAROTRAUMA IN GUINEA PIGS

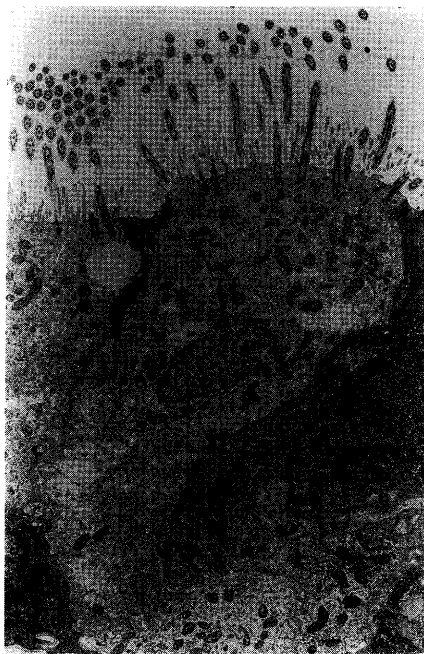

Fig. 9 Some ciliated cells showed a slight loss of cilia one day after pressure exposure

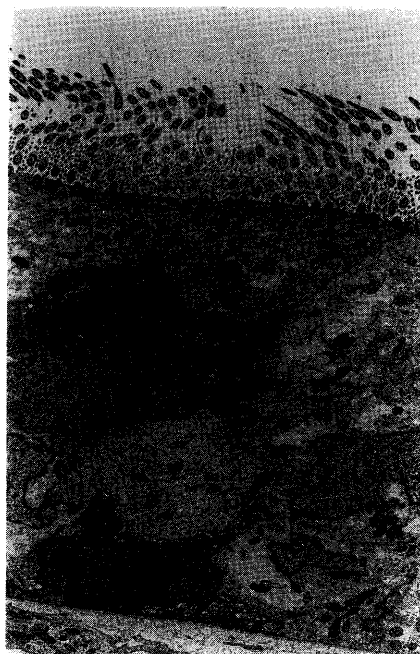


Fig. 10 Vacuoles were apparent within the ciliated cells one day after pressure stress

their lost cilia (Fig. 7). The terminal web for nonciliated cells was somewhat indistinct one week after exposure (Fig. 8) but had returned to normal after two weeks. There were no abnormalities in the goblet cells during the course of morphological study.

TEM also indicated ciliated and nonciliated cells in Group 1. Some ciliated cells showed a slight loss of cilia (Fig. 9) and apparent vacuoles in the ciliated cells (Fig. 10) one day after pressure exposure. One week after, the numbers of cilia among ciliated cells had almost all recovered and there were no vacuoles within the ciliated cells. There were no significant changes in the goblet cells.

DISCUSSION

The process of barotrauma in the middle ear may be summarized as follows: when subjected to high pressure, a relatively negative pressure is produced in the tympanic cavity compared with the external acoustic meatus and the inner ear; if the pressure-adjusting mechanism of the Eustachian tube is not functioning adequately, negative pressure within the tympanic cavity persists, and severe damage may result. Bayliss¹⁰⁾ reported that the diving records for 106 divers who experienced barotrauma indicate that abnormality in the ears was noted during compression in 84.6% of these divers and during decompression in 9.4%. In studies using guinea pigs, Wanibuchi¹¹⁾ reported that middle ear damage was more marked during compression than decompression. Lamkin et al.¹²⁾ reported that middle ear damage was enhanced more significantly by negative pressure within the tympanic cavity than by positive pressure. In the present study, there was more severe damage in the tympanic cavity in Groups 1 and 2 than in Group 3. These

findings support the reports of Bayliss, Wanibuchi, and Lamkin *et al.*¹⁰⁻¹²⁾ According to our studies, there was more remarkable tissue damage in the middle ear during compression than decompression, if the required time to change the pressure for one atmosphere was the same. Furthermore, Hando *et al.*¹⁾ reported that tympanic cavity damage was more evident and the incidence of damage was increased due to a sudden change of pressure. They also reported that middle ear barotrauma did not occur when the eardrums were already perforated. Middle ear barotrauma may occur even during decompression because positive pressure within the tympanic cavity exerts many effects upon surrounding tissues, but it is thought to be more likely to occur during compression. Conversely, regarding the relationship between the middle ear and inner ear barotrauma, Haines¹³⁾ and Taylor¹⁴⁾ reported that even when middle ear barotrauma occurs during diving, there was no damage in the inner ear. Yanagita *et al.*¹⁵⁾ reported the same results in cases of hyperbaric oxygen therapy for sudden deafness. Hando *et al.*¹⁾ stated that there may be a high degree of impairment in cochlear sensory hair even when middle ear damage is minor, and it is thought that the extent of inner ear barotrauma does not necessarily correspond precisely to middle ear injury. Although macroscopic hemorrhage in the tympanic cavity was noted, the chief pathological manifestation is believed to be submucous hemorrhage due to ruptured blood vessels. There was no hemorrhage in the Eustachian tube. This situation was thought to be caused because the epithelium of the tube, a pseudostratified columnar epithelium, is covered with enough cilia to protect it from strong barotrauma. No perforation of the eardrum was seen under the conditions of the present study. SEM and TEM demonstrated that some ciliated cells showed a slight loss of cilia immediately after the experimental trial, but this damage was repaired in about two weeks. In morphological studies of the middle ear and Eustachian tube after experimental constriction of the tube, Harada *et al.*¹⁶⁾ and Yamashita¹⁷⁾ reported that some cilia were lost after three weeks, but in these cases, effusion was found within the tympanic cavity. The present study found no obvious effusion within it. This fact suggests that the sudden negative pressure occurring within tympanic cavity contributed to a loss of cilia during middle ear barotrauma. Damaged mucous membrane epithelium repaired itself in about two weeks, a finding which is consistent with the reports of Lim *et al.*¹⁸⁾ and Kawabata¹⁹⁾ that regeneration of ciliated cells requires from one to several weeks. Submucous edema was also seen after one week, but this disappeared eventually. In view of these findings, middle ear barotrauma appears to be reversible.

CONCLUSIONS

1. Middle ear barotrauma was induced by subjecting guinea pigs to sudden atmospheric pressure changes in an experimental hyperbaric chamber, and the ensuing damage was histologically examined.
2. Concomitant damage in middle ear barotrauma was more marked in cases of compression than decompression.
3. The chief pathological manifestation of middle ear barotrauma appeared to be submucous hemorrhage due to ruptured blood vessels beneath the mucous membrane.
4. Although some cilia loss occurred in ciliated cells due to middle ear barotrauma, the cells fully recovered in time. Therefore, middle ear barotrauma appears to be reversible.

MIDDLE EAR BAROTRAUMA IN GUINEA PIGS

REFERENCES

- 1) Hando, M., Yanagita, N. and Yokoi, H.: Scanning electron microscopic studies on inner ear barotrauma. Mainly on the damage cochlear sensory hairs. *Jpn. J. Otol.*, 85, 941–950 (1982).
- 2) Yanagita, N.: Inner ear barotrauma: clinical and experimental studies. *Pract. Otol.*, 79, suppl. 3, 20–32 (1986).
- 3) Fukuta, S., Yokoi, H. and Yanagita, N.: Electron microscopic study on inner ear barotrauma with emphasis on the cochlear damage. *Jpn. J. Otol.*, 94, 970–979 (1991).
- 4) Yanagita, N., Fukuta, S., Yokoi, H., Ishida, K. and Nakashima, T.: Inner ear disorders caused by barotrauma in guinea pigs. *Auris. Nasus. Larynx.*, 19, suppl. S., 1–11 (1992).
- 5) Yamamuro, Y., Nakashima, T. and Yanagita, N.: Effects of repeated changes in atmospheric pressure on inner ear of guinea pigs. *Auris. Nasus. Larynx.*, 19, suppl. S., 13–24 (1992).
- 6) Kozuka, M., Ishida, K., Tago, C. and Yanagita, N.: Scanning electron microscopic study on inner ear barotrauma in the guinea pig with one eustachian tube occluded. *Jpn. J. Otol.*, 96, 1878–1888 (1993).
- 7) Ishida, K., Kozuka, M., Fukuta, S. and Yanagita, N.: Vestibular changes due to barotrauma. *Jpn. J. Otol.*, 96, 2017–2023 (1993).
- 8) Lim, D.J., Paparella, M.M. and Kimura, R.S.: Ultrastructure of the Eustachian tube and middle ear mucosa in the guinea pig. *Acta. Otolaryng.*, 63, 425–444 (1967).
- 9) Maeda, S.: Fine structure of the epithelium in developing rat middle ear. *Jpn. J. Otol.*, 79, 568–577 (1976).
- 10) Bayliss, G.J.A.: Aural barotrauma in naval divers. *Arch. Otolaryng.*, 88, 141–147 (1968).
- 11) Wanibuchi, G.: Experiment study in hyper pressure. *Jpn. J. Otol.*, 30, 31–59 (1924) (in Japanese).
- 12) Lamkin, R., Axelsson, A., McPherson, D. and Miller, J.: Experimental aural barotrauma. Electrophysiological and morphological findings. *Acta. Otolaryng.*, suppl. 335, 1–24 (1975).
- 13) Haines, H.L.: Aerotitis media in submariners. *Ann. Otol.*, 55, 347–371 (1946).
- 14) Taylor, G.D.: The otolaryngologic aspects of skin and scuba diving. *Laryngoscope*, 69, 809–858 (1959).
- 15) Yanagita, N. and Miyake, H.: Treatment of sudden deafness. With a special reference to hyperbaric oxygen therapy. *Otologia*, 24, 28–42 (1978).
- 16) Harada, Y. and Yamashita, M.: The pathological changes of eustachian tube epithelium after tubal obstruction. *Otologia*, 23, 618–622. (1977).
- 17) Yamashita, M.: Eustachian tube mucous membrane damage due to mechanical obstruction. *Pract. Otol.*, 78, 1113–1123 (1985).
- 18) Lim, D.J. and Hussen, B.: Tympanic mucosa after tubal obstruction. An ultrastructural observation. *Arch. Otolaryngo.*, 91, 585–593 (1970).
- 19) Kawabata, I.: The changes of mucous-membrane epithelium in tympanic cavity. Study of a scanning electron microscopy. *Otologia*, 23, 609–617 (1977).