

## CASE REPORT

Nagoya J. Med. Sci. 60. 139 ~ 143, 1997

### CONSERVATIVE HANDLING OF THE UTERUS IN A 10-WEEK CERVICAL PREGNANCY CASE

SEIYA YOSHIDA<sup>1</sup>, MADOKA FURUHASHI<sup>1,2</sup>, ATSUO ITAKURA<sup>1</sup>,  
YOSHIHITO FURUHASHI<sup>3</sup> and NOBUHIKO SUGANUMA<sup>1</sup>

<sup>1</sup>Department of Obstetrics and Gynecology, Nagoya University School of Medicine, Nagoya  
and <sup>3</sup>Department of Obstetrics and Gynecology, Okazaki City Hospital, Okazaki, Japan

#### ABSTRACT

A patient with a living 10-week old cervical pregnancy who desired to preserve fertility was successfully treated with methotrexate, intraamniotic KCl injection and endocervical curettage. In the case of a living cervical pregnancy even after 10 weeks, conservative treatment remains an option, although intensive management and care should be given.

Key Words: cervical pregnancy, conservative treatment, methotrexate

#### INTRODUCTION

Cervical pregnancy is a very rare type of ectopic pregnancy. Its frequency is estimated as one in 1,000 to 8,000 pregnancies.<sup>1)</sup> Through the recent development of diagnostic techniques such as ultrasonography, most of these pregnancies can be diagnosed between 8 and 10 weeks of gestation. However, delayed diagnosis may cause major hemorrhage and, subsequently, a hysterectomy should be chosen as the final treatment for emergent cases.

To the best of our knowledge regarding living cervical pregnancies over 10 weeks old, only three cases have been successfully managed with the conservative method in the past; uterine artery embolization was chosen in two cases<sup>2,3)</sup> and actinomycin-D administration in one case.<sup>4)</sup> In the present study, a woman who bore a living 10-week old cervical pregnancy and desired to maintain fertility was successfully treated conservatively with methotrexate chemotherapy, intraamniotic KCl injection and endocervical curettage.

#### CASE REPORT

A 35-year-old woman (gravida 1, para 1) was seen at Okazaki City Hospital (Okazaki, Japan), and was diagnosed with a 10-week old cervical pregnancy for which hysterectomy was recommended. As she hoped to preserve her fertility, she was referred to Nagoya University Hospital (Nagoya, Japan) for further consultation.

<sup>2</sup>Present address: Department of Obstetrics and Gynecology, Handa City Hospital, Handa, Japan

Corresponding author: Nobuhiko Suganuma, Department of Obstetrics and Gynecology, Nagoya University School of Medicine, 65 Tsurumai-cho, Showa-ku, Nagoya 466, Japan

Tel: 052-744-2267

Fax: as above

At the time of her admission, she had been asymptomatic other than amenorrhea for 10 weeks and 4 days. Pelvic examination by a physician revealed an enlarged uterine cervix. Ultrasonotomography demonstrated that the chorion frondosum and the entire gestational sac containing a live fetus were located caudal to the uterine internal os with a crown-rump length of 36 mm which corresponded to exactly 11 weeks of gestation. At the time, the serum  $\beta$ -hCG level rose to greater than 16,000 IU/L (Fig. 1).

After obtaining informed consent, a transvaginal ultrasound-guided injection of 2 ml of 4 mEq KCl into the fetus was performed on the second hospital day. Fetal cardiac arrest occurred immediately after this injection. An 18-gauge needle was inserted into the gestational sac to aspirate 5.5 ml of amniotic fluid, followed by an injection of 20 mg methotrexate/1 ml normal saline. These treatments were performed under sedation with intravenous administration of 10 mg of diazepam and 15 mg of pentazocine. On the 2nd, 5th, and 7th days after the initial injection, a transvaginal ultrasound-guided injection of 20 mg of methotrexate was administered the gestational sac. After these treatments, the serum  $\beta$ -hCG level declined to 3,200 IU/L (Fig. 1).

On the 9th day, the gestational sac became undetectable. The intramuscular injection of 20 mg methotrexate was performed daily for 4 consecutive days beginning on the 19th and 30th days. Following these treatments, the serum  $\beta$ -hCG level fell to 28 IU/L (Fig. 1).

Because the size of the uterine cervix remained enlarged ( $77.8 \times 68.6$  mm as measured by ultrasonotomography) on the 63rd day, an endocervical curettage was performed to remove the degenerated necrotic villi which were examined histologically (Fig. 2). Since the serum  $\beta$ -hCG level continued to be greater than 5 IU/L after the curettage, a third chemotherapy of intramuscular methotrexate was performed for 4 consecutive days beginning on the 96th day. Thereafter,

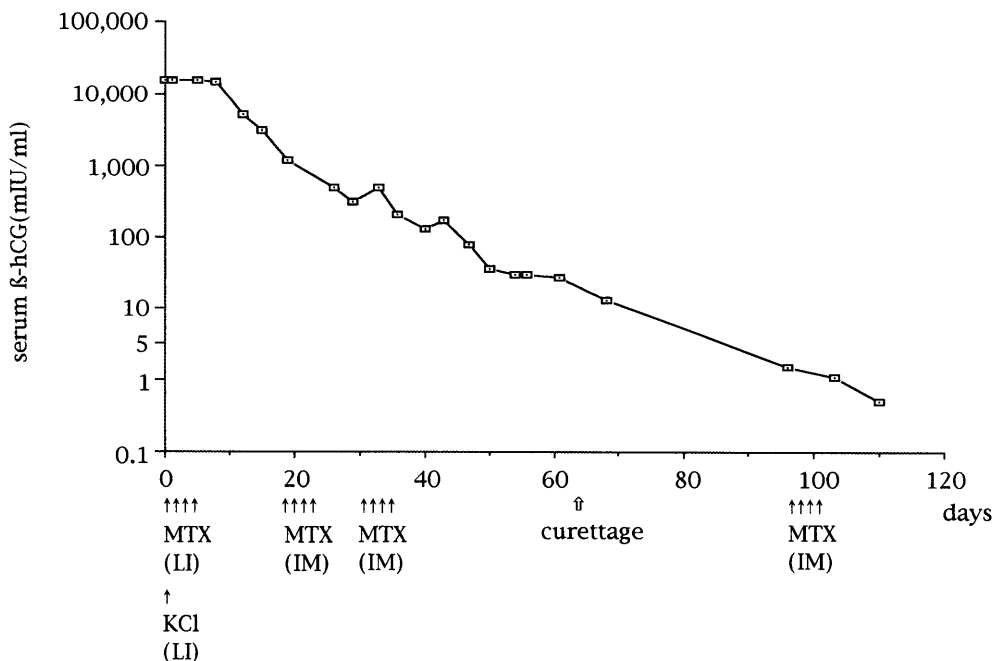


Fig. 1. Serum  $\beta$ -hCG levels during the course of treatment. LI and IM denote local and intramuscular injections, respectively.

## TREATMENT FOR CERVICAL PREGNANCY

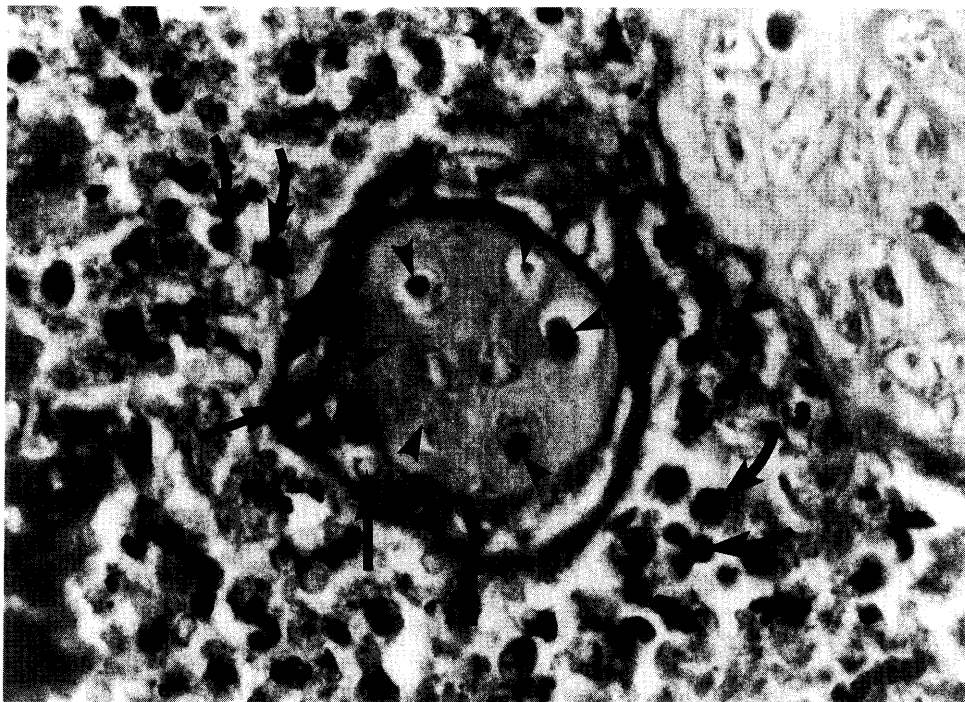


Fig. 2. Histological findings of the tissues obtained by curettage. Chorionic interstitium (arrowheads) and trophoblasts (arrows) are shown. It is impossible to distinguish the syncytiotrophoblasts from cytotrophoblasts because of necrosis and degeneration. The infiltration of white blood cells (curved arrows) are also shown around the villi.

the serum  $\beta$ -hCG level declined lower than 5 IU/L, and the size and shape of the uterine cervix returned to a normal range gradually.

During the course of the treatments, transaminasemia was noted. The highest values of aspartate and alanine aminotransferases were 170 KU and 207 KU (normal values are 10–38 and 5–35) respectively, and their values returned to the normal level without any treatment. However, there were no other drug side effects such as oral inflammation or myelosuppression. The patient developed an infectious episode for which intravenous antibiotics were administered. The causative agents were *Escherichia coli* and *Enterococcus faecalis*. After the second intramuscular administration of methotrexate (around the 40th day), the patient became febrile (38.5°C). At that time, thrombocytopenia (97,000/L) and elevated fibrin degradation products (16.0  $\mu$ g/mL) were noted. Her illness was diagnosed as a disseminated intravascular coagulation (DIC). Anti-DIC treatment with gabexate mesilate and dopamin was given. Although she was dyspneic with PaO<sub>2</sub> of 78.2 mmHg and SaO<sub>2</sub> of 93.9%, the dyspnea improved and arterial blood gas analysis returned to normal after treatment. Profuse genital bleeding (> 1,000 g) occurred during the first (day 90) and second (day 117) menstrual periods. The bleeding stopped spontaneously without a blood transfusion. After the third menstrual period, no excessive bleeding occurred.

## DISCUSSION

Usually, 50% of cervical pregnancy cases require hysterectomies because of a profuse, life-threatening hemorrhage.<sup>5)</sup> To preserve fertility, treatment of a cervical pregnancy can be approached conservatively using methotrexate<sup>6)</sup> or actinomycin-D<sup>4)</sup> chemotherapy, uterine artery embolization,<sup>2)</sup> or oral etoposide.<sup>7)</sup> However, in these previous studies, conservative treatment was restricted to those patients with a gestational period of less than 8 weeks or with a serum  $\beta$ -hCG level lower than 10,000 IU/L.<sup>8,9)</sup> In the present case, we were able to treat a patient of 10 weeks' gestation with conservative therapy.

Of great importance is the selection of the appropriate therapeutic modality for conservative treatment. Uterine artery embolization is more invasive than drug administration because of the potential risk of distal ischemia due to inadvertent embolization of the distal vessels. Alopecia is one of the major side effects of etoposide,<sup>7)</sup> which can cause significant psychological effects particularly on young women, albeit temporary. Also, it is unknown how etoposide affects the offspring, although methotrexate and actinomycin-D have been reported to be non-teratogenic.<sup>10)</sup> Skin and subcutaneous necrosis takes place when actinomycin-D leaks from vessels, and it should be dangerous to inject actinomycin-D directly into gestational sac. Moreover, Feldman *et al.*<sup>11)</sup> reported that methotrexate administration in high doses had no adverse effect on ovarian function. Methotrexate may cause liver dysfunction; however, the severity is related to the dose of methotrexate,<sup>12)</sup> and the side effects are not severe in most cases as long as the standard dosage is used. Thus, we chose methotrexate administration for the treatment of cervical pregnancy in the present case.

Several clinical issues need to be discussed. First, it took as many as 130 days to recover a normal sized cervix. The patient required careful management and substantial hospitalization. Second, the patient suffered from infectious disease repeatedly. The source might have been the degenerated necrotic cervical content caused by methotrexate injection because no further infection occurred after the evacuation of these infectious materials. Third, a critical DIC episode occurred in the patient, followed by a severe infection. Alternatively, tissue thromboplastin from the necrotic tissues might have leaked into the capillary flow, resulting in the DIC. The finding of dyspnea occurring during the DIC supports this speculation, namely that the release of tissue thromboplastin might have caused pulmonary embolization instantly, resulting in the dyspnea.<sup>13)</sup>

The etiology of the patient's hemorrhagic genital bleeding after recovering her menstrual cycle is unidentified. Ultrasonographic examination indicated that the size of the cervix remained enlarged when the profuse bleeding occurred. Thus, it is likely that the blood vessels in the cervix were enriched and broken during menstruation. In fact, no extensive bleeding occurred after the third menstruation when the cervix normalized in size.

Our case showed that it is possible to conservatively treat a living cervical pregnancy at 10 weeks' gestation with careful management. Also, our case demonstrates that informed consent is vital whenever high risk therapy is undertaken.

## REFERENCES

- 1) Bayless, R.B.: Nontubal ectopic pregnancy. *Clin. Obstet. Gynecol.*, 30, 191–199 (1987).
- 2) Saliken, J.C., Normore, W.J., Pattinson H.A. and Wood, S.: Embolization of the uterine arteries before termination of a 15-week cervical pregnancy. *Can. Assoc. Radiol. J.*, 45, 399–401 (1994).
- 3) Gilbert, W.M., Moore, T.R., Resnik, R., Doemeny, J., Chin, H. and Bookstein, J.J.: Angiographic embolization in the management of hemorrhagic complications of pregnancy. *Am. J. Obstet. Gynecol.*, 166, 493–497 (1992).

## TREATMENT FOR CERVICAL PREGNANCY

- 4) Brand, E., Gibbs, R.S. and Davidson, S.A.: Advanced cervical pregnancy treated with actinomycin-D. *Br. J. Obstet. Gynecol.*, 100, 491–492 (1993).
- 5) Yankowitz, J., Leake, J., Huggins, G., Gazaway, P. and Gates, E.: Cervical ectopic pregnancy: review of the literature and report of a case treated by single-dose methotrexate therapy. *Obstet. Gynecol. Surv.*, 45, 405–414 (1990).
- 6) Timor-Tritsch, I.E., Monteagudo A., Mandeville, E.O., Peisner, D.B., Anaya, G.P. and Pirrone, E.C.: Successful management of viable cervical pregnancy by local injection of methotrexate guided by transvaginal ultrasonography. *Am. J. Obstet. Gynecol.*, 170, 737–739 (1994).
- 7) Segna, R.A., Mitchell, D.R. and Misas, J.E.: Successful treatment of cervical pregnancy with oral etoposide. *Obstet. Gynecol.*, 76, 945–947 (1990).
- 8) Steven, J.O., Alelei, L.V., Peter, K.S. and Ralph, K.T.: Conservative treatment of ectopic pregnancy with methotrexate. *Am. J. Obstet. Gynecol.*, 154, 1299–1306 (1986).
- 9) Paliti, Z.B., Rosenn, B., Goshen, R., Ben-Chitrit, A. and Yagel, S.: Successful treatment of a viable cervical pregnancy with methotrexate. *Am. J. Obstet. Gynecol.*, 161, 1147–1148 (1989).
- 10) Suzuki, I., Goto, S., Yamada, A. and Tomoda, Y.: Pregnancy after chemotherapy for trophoblastic diseases and psychosomatic development in the progeny. *Asia-Oceania J. Obstet. Gynecol.*, 19, 407–415 (1993).
- 11) Feldman, J.E.: Ovarian failure and cancer treatment: Incidence and interventions for the premenopausal woman. *Oncology Nursing Forum*, 16, 651–657 (1989).
- 12) Banerjee, A.K., Lakhani, S., Vincent, M. and Selby, P.: Dose-dependent acute hepatitis associated with administration of high dose methotrexate. *Human Toxicol.*, 7, 561–562 (1988).
- 13) Rashid, A.M., Moir, C.L. and Butt, J.C.: Sudden death following cesarean section for placenta previa and accreta. *Am. J. Forensic. Med. Pathol.*, 15(1), 32–35 (1994).