

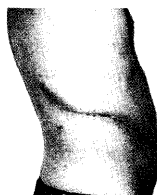
## THE PRESENT STATUS OF ENDOUROLOGIC SURGERY

SHINICHI OHSHIMA and YOSHINARI ONO

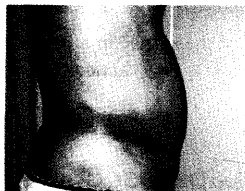*Department of Urology, Nagoya University School of Medicine*

**Key Words:** endourologic surgery, laparoscopic nephrectomy, laparoscopic adrenalectomy, endopyeloureterotomy

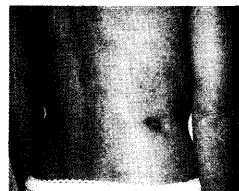
Over the last two decades we have witnessed several revolutions in which new treatment modalities replaced traditional, open surgery. First, transurethral resection of the prostate replaced open prostatectomy as the gold standard in the treatment of bladder outlet obstructions. Second, extracorporeal shock wave lithotripsy became the first choice in the surgical treatment of urinary calculi. Third, endourologic surgery, which includes endoscopic and laparoscopic procedures, offers patients with various urologic diseases a number of advantages over traditional, open procedures. The most important difference is that endourological surgery does not require the long skin and muscle incisions and sometimes even rib resections of open surgery (see Fig. 1). These incisions result in long-term dysfunction of the muscles and sometimes muscle atrophy as well as much pain in the early post-operative period (Fig. 2, 3, 4). The main advantages of endoscopic surgery for the patient are less post-operative pain, an earlier recovery, and an earlier return to normal activity. The shorter hospital stay and earlier convalescence reduce not only the direct medical cost but also the economic loss from long-term morbidity. For these reasons,



Open surgery



Laparoscopic  
surgery



Endopyelo-  
ureterotomy

Figure 1 Operative wound in patients undergoing open pyeloplasty (left), laparoscopic pyeloplasty (middle), and percutaneous endopyeloureterotomy (right).

Correspondence: Yoshinari Ono, MD, PhD, Department of Urology, Nagoya University School of Medicine, 65 Tsurumai, Showa-ku, Nagoya 466-8550, Japan

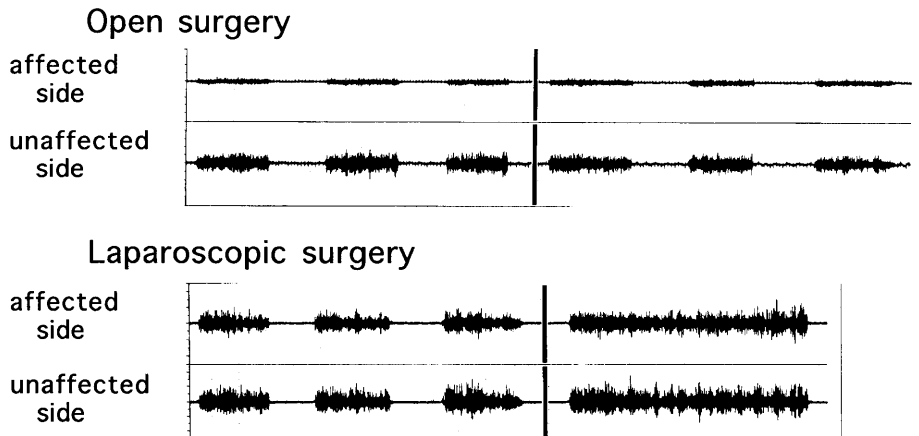


Figure 2 Electromyography of the rectus muscle in a patient who underwent open, radical nephrectomy 6 months earlier (upper two lines) and in a patient who underwent laparoscopic radical nephrectomy 6 months earlier (lower two lines).

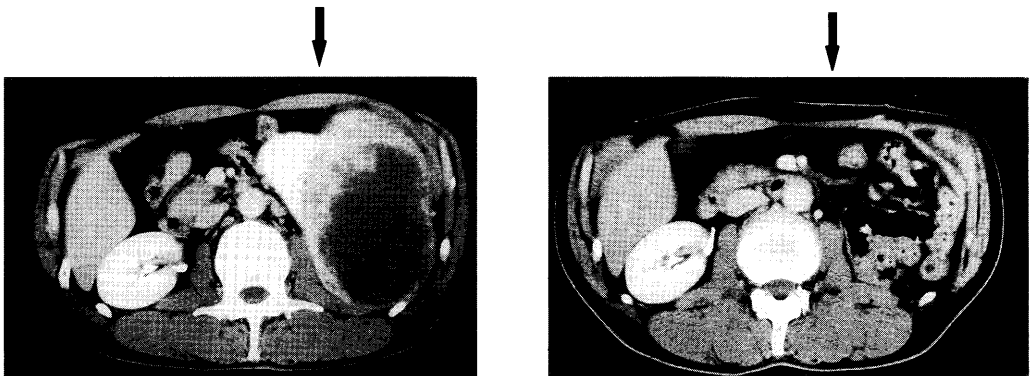


Figure 3 Computed tomography at the level of the kidney in a patient who underwent left, open, radical nephrectomy 3 years earlier. The rectus muscle is very thin on the left side, which indicates muscle atrophy.

	Laparoscopic surgery		Open surgery	
McDougall et al	N=12	24mg*	N=12	40mg* 15mg**
Ono et al	N=27	32mg***	N=25	63mg***

\*morphine, \*\*ketorolac, \*\*\*pentazocine

Figure 4 Doses of analgesics in the early post-operative period, (37) and (38).

endourological surgery has become a generally accepted procedure that will further develop and replace more open procedures in the future.

We describe the present status of endourologic surgery.

### **1. Endoscopic Surgery for The Upper Urinary Tract**

In the traditional reconstructive surgery for the upper urinary tract, pyeloplasty and renal descent with pyelo-ureterostomy or uretero-ureterostomy were used to relieve ureteropelvic junction obstructions and the upper ureteral strictures, while Boari bladder flaps and psoas bladder hitches with vesicoureteral anastomosis were used to relieve lower ureteral strictures. Auto-transplantation and ileal substitution were also used in patients with extensive ureteral stenoses. These procedures were carried out through a 20 to 40 cm-long flank incision. Endoscopic surgery, on the other hand, does not require any large incision.

#### *Ureteropelvic Junction Obstruction and Upper Ureteral Stricture*

In endoscopic surgery for these two impediments, there are two access routes: the percutaneous and the transurethral approach. Percutaneous endopyeloureterotomy was derived from percutaneous nephrolithotripsy, which had been named "percutaneous pyelolysis"; it was first performed by Wickman and associates in the early 1980s (1). They made a full-thickness incision in the upper ureter and ureteropelvic junction using a 21 F endoscopic urethrotome, which was passed through a percutaneous nephrostomy tract. The splint tube and diverting proximal nephrostomy drain remained in place for 1 month. They successfully treated 5 of 7 patients. Smith and Badlani in the United States, Korth in Germany, and Van Cangh in Belgium followed them. Motala and Smith recently reported the results of 212 endopyelotomies on 208 consecutive patients. After a followed-up 0.5 to 8 years they reported a 86% overall success rate and concluded that percutaneous endopyelotomy was a sensible alternative to open pyeloplasty for primary ureteropelvic junction obstruction (2). Kuenkel and Korth reported an overall success rate of 77% in 143 patients and described the procedure as safe while achieving similar long-term results as open pyeloplasty, and being preferable overall (3). Van Cangh and associates reported an overall, long-term success rate of 73% in 102 consecutive patients followed-up for 1 to 10 years. They warned of high failure and/or recurrence rates in high-grade hydronephrosis patients who had a vessel crossing the ureteropelvic junction.

In Japan, Tajima and associates initiated endopyelotomy in 1986 (4). In 1988, we developed a new endopyelotomy technique, which was endopyeloureterotomy via the transpelvic extra-ureteral approach (Fig. 5). It allows an incision of sufficient depth and length to be made in the stenotic segment of the ureter, while an incision of the renal pelvic wall will facilitate the reconstruction of a funnel-shaped ureteropelvic junction (5). We recently reported an overall, long-term success rate of 89% in 152 patients and recommended our technique for patients with ureteropelvic junction obstruction as well as upper ureteral stricture and even patients with a more than 2 cm-long stenotic segment (6).

Only a few studies have focused on percutaneous endopyelotomy in children. Maeda and associates reported a success rate was 83% in 12 children, aged from 1 to 14 years, with ureteropelvic junction obstruction (7). Kavoussi and associates reported a success rate of 100% in 4 children aged from 2 months to 5 years (8). Both groups concluded that percutaneous endopyelotomy can be used in children.

Transurethral ureteronephroscopic endopyelotomy for ureteropelvic junction obstruction was first performed by Inglis and Tolley in 1986 (9). They successfully treated two patients. The procedure has not been performed in a large patient (Tab. 2). Clayman and associates reported a success rate of 90% in 10 patients (10). They found that the procedure was less invasive than

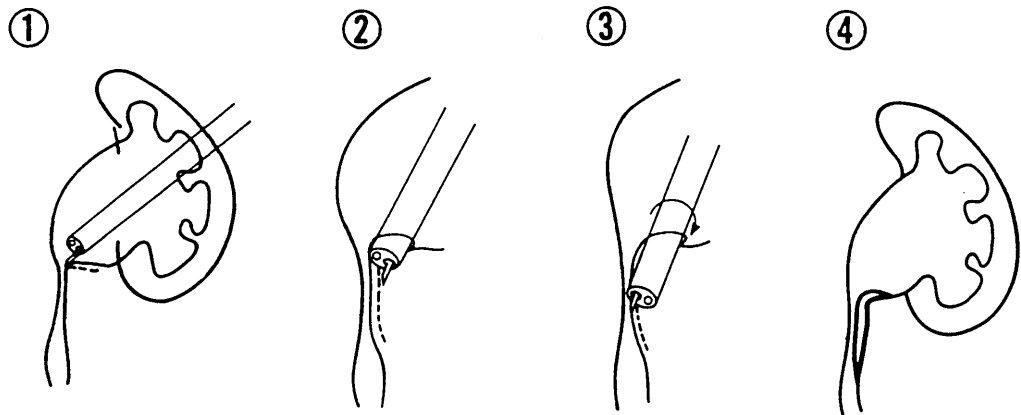


Figure 5 Operative procedure of endopyelouretotomy via transpelvic extraureteral approach (5).

Table 1 Results of endopyelouretotomy

	No. Pts.	Success Rate	Followup (years)
Motola et al. 1993	208	86%	0.5–8
Kuenkel et al. 1990	143	81%* <sup>1</sup> 73%* <sup>2</sup>	–3.6
Van Cangh et al. 1994	102	73%	1–10
Ono et al. 1997	152	90%* <sup>1</sup> 84%* <sup>2</sup>	0.5–9

\*1 primary disease, \*2 secondary disease

Table 2 Results of laparoscopic simple nephrectomy

	No. Pts.	Operating Time (hours)	Estimated Blood Loss (ml.)	Complications	No. With Conversion to Open Surgery	Hospital Stay (days)	Convalescence (wks.)
Fuchs et al. 1995	65 10* <sup>1</sup>	0.9–6 4.5–8	50–500	0 0	0 0	1–3 2–6	– –
Eraky et al. 1996	137* <sup>2</sup> 35* <sup>3</sup>	2.9 1.8	– –	15 2	10 2	2.9 2.4	– –
Ono et al. 1997	33* <sup>2</sup> 32* <sup>3</sup>	4.3 3.4	377 142	8 2	7 0	10 10	2.8 2.8

\*1 bilateral laparoscopic nephrectomy, \*2 transperitoneal approach, \*3 retroperitoneal approach

## THE PRESENT STATUS OF ENDOUROLOGIC SURGERY

percutaneous endopyelotomy; both techniques eliminated the need for long-term nephrostomy. Gallucci and associates reported a success rate of 82% in 11 patients with secondary ureteropelvic junction stenosis (11), and Chowdhury and Kenogbon reported a similar success rate of 86% in 14 patients (12).

In summary, percutaneous endopyeloureterotomy has become the first choice of treatment modality for ureteropelvic junction obstruction and upper ureteral stenosis except in infants. Transurethral ureteroscopic endopyelotomy is still not fully appreciated although it is less invasive. In ureteropelvic junction obstruction, it is controversial whether a vessel crossing the ureteropelvic junction is a risk to the success of endopyeloureterotomy or not. Most authors believe that only a few of the crossing vessels can in fact cause an obstruction.

#### *Lower Ureteral Stricture*

Ureteral stricture is still less common than ureteropelvic junction obstruction, but it has become a more important problem because of increases in extracorporeal shock wave lithotripsy and open or endoscopic surgery on the upper urinary tract.

In the early 1980s, some investigators used a balloon dilation technique to re-establish normal urinary drainage in patients with ureteral stricture. When this technique did not yield satisfactory long-term results, it was abandoned. Thereafter, transurethral ureteroscopic endoureterotomy has been used most often to relieve ureteral strictures. In 1987, Schuller and associates first reported the success of the procedure in 8 of 9 patients followed-up for a mean of 12 months. Meretyk and Clayman reported a success rate of 62% in 13 patients followed-up for 12 months or longer. They suggested that a full-thickness incision should be extended for 1–2 cm above and below the stricture to the point where the ureter reaches its normal lesion (13).

In Japan, Takeuchi and associates performed the procedure in 25 patients and reported a success rate of 80% (14). Yamada and Ono developed a procedure consisting of transurethral ureteroscopic balloon dilation of the stenosis followed by ureteroscopic ureterotomy. They performed it 20 times in 19 patients and reported a success rate of 85% after a mean follow-up of 18 months (15).

More recently, Chandhoke and Clayman developed a new dilating balloon catheter with a fine electrocautery cutting wire for the retrograde incision of the ureter under fluoroscopic control (16). In this procedure it is not necessary to establish a nephrostomy tract nor insert a ureteroscope. They reported a success rate of 85% in 28 patients followed-up for 3 to 9 months. This is a very attractive technique because it is minimally invasive and highly successful.

In summary, different modalities have been developed for relieving lower ureteral strictures; they all deserve further evaluation.

## **2. Laparoscopic Surgery for the Kidney and Adrenal Gland**

### *Laparoscopic Nephrectomy for Benign Disease*

Laparoscopic nephrectomy was first performed by Clayman and associates in June 1990 (17). This was the first time that a parenchymal organ was removed in a laparoscopic procedure. The kidney was dissected transperitoneally and entrapped in an impermeable nylon sack that was positioned in the working space. After it had been morcellated within the sack with a tissue morcellator, the sack was successfully removed through a port without any major incision. Since then, Kerbl and Kavoussi (18) and Fuchs (19) in the United States, Coptcoat in England (20), Rassweiler in Germany (21), Eraky in Egypt (22), Gaur in India (23), Katoh and Ono (24) and Matsuda and Terachi (25) in Japan have removed kidneys in this way.

To date, over 500 laparoscopic nephrectomies have been performed for all types of benign kidney disease necessitating its surgical removal. This has included small or non-inflamed

kidneys in patients with renovascular and renal hypertension and non-functioning, hydronephrotic kidneys with and without repeated pyelonephritis. However, in patients with xanthogranulomatous pyelonephritis, the laparoscopic procedure has often had to be converted to an open procedure because the renal hilum could not be dissected safely.

Several reports describe the results of laparoscopic simple nephrectomy for benign disease. Kerbl and Kavoussi compared their first 20 transperitoneal procedures with 23 open procedures (18). Laparoscopic surgery had a longer mean operative time than open surgery (5.9 vs. 2.7 hours), but a significantly shorter post-operative hospital stay (3.7 days vs. 1.8 months) and an earlier full recovery (7.3 days vs. 9.8 months). Katoh and Ono reported the results of 26 transperitoneal procedures (24). Their mean operative time was 4.4 hours, mean estimated blood loss was 454 ml, conversion to open surgery was necessary in 4 patients (16%), and mean time to full convalescence was 18 days. Rassweiler and associates also reported the results of 24 transperitoneal procedures (21). Their mean operative time was 4 hours, mean estimated blood loss was 225 ml, and conversion to open surgery was required in 4 patients (17%). Coptcoat and associates reported the results of another 24 transperitoneal procedures (20). Their mean operative time was 3.5 hours, conversion to open surgery was necessary in 2 patients (7%), and mean time to full convalescence was 1.7 weeks. An important improvement in laparoscopic nephrectomy was the development of the retroperitoneal approach by Gaur in 1992 (23). A retroperitoneal working space is established by dilating a balloon. This method facilitates the laparoscopic identification of the retroperitoneal structures and faster dissection. McDougall and Clayman compared 20 transperitoneal with 9 retroperitoneal procedures (26) and concluded that the two approaches were on a par. We also reported the results of 20 retroperitoneal procedures (27). Our mean operative time was 3.3 hours and mean estimated blood loss was 135 ml. We found the retroperitoneal approach to be superior to the transperitoneal approach in laparoscopic simple nephrectomy. The group of McDougall and Clayman as well as ours noted that the retroperitoneal approach should not be used in an obese patient.

In summary, laparoscopic simple nephrectomy has become the first choice of treatment modality for removing kidneys with benign disease except in patients with xanthogranulomatous pyelonephritis.

#### *Laparoscopic Adrenalectomy*

This type of laparoscopic surgery was first performed on a patient with primary aldosteronism by Go and Takeda in January 1992 (28). Since then, Gagner in Canada (29), Higashihara (30), Suzuki (31) and Terachi (32) in Japan, and Guazonni in Italy (33) have removed adrenal tumors in patients with primary aldosteronism, Cushing syndrome, and recently, pheochromocytoma. To date, over 600 laparoscopic adrenalectomies have been performed; recent data are shown in Table 3. Terachi and Matsuda reported their results of 100 transperitoneal procedures (32). Their mean operative time was 4 hours, mean estimated blood loss was 68 ml, and the rate of complications was 4%. They recommended the procedure for adrenal tumors of less than 6 cm in size. Suzuki and associates reported their results of 60 transperitoneal and retroperitoneal adrenalectomies (31). Mean time of return to normal activity was 1.5 weeks. Guazonni and associates performed transperitoneal adrenalectomy on 15 patients (33). Their mean operative time was 3 hours, mean estimated blood loss was 100 ml, and mean time to full convalescence was 1.4 weeks. Comparing this with 15 open adrenalectomies, they found that the laparoscopic procedure yielded shorter hospital stays and earlier convalescences.

In summary, laparoscopic adrenalectomy has become the first choice of treatment modality for removing benign adrenal tumors of less than 5–6 cm in diameter. Laparoscopic adrenalectomy for pheochromocytoma is still controversial.

## THE PRESENT STATUS OF ENDOUROLOGIC SURGERY

Table 3 Results of laparoscopic adrenalectomy

	No. Pts.	Operating Time (hours)	Estimated Blood Loss (ml.)	Convalescence (wks.)	Complications
Takeda et al. 1994	17	4.2	216	—	6%
Guazzoni et al. 1995	15	3	100	1.4	0%
Terachi et al. 1997	100	4	68	—	4%
Suzuki et al. 1997	60	—	—	1.5	10%
Ono et al. 1997	34	3.5	124	3	9%

*Laparoscopic Radical Nephrectomy for Renal Cell Carcinoma*

Radical nephrectomy has been the standard treatment modality for localized renal cell carcinoma since Robson introduced it in 1963. It includes the ligation of the renal vessels, the removal of the kidney and adrenal gland together with perirenal fatty tissue and Gerota's fascia, and the dissection of lymph nodes. We first performed this procedure laparoscopically in July 1992 (34, 35, 36); McDougall and Clayman started a laparoscopic radical nephrectomy program in August 1992 (37). In the laparoscopic procedure, the renal vessels are ligated after early identification of the ureter and cephalad dissection along the great vessels without the tumor being manipulated while the removal of the kidney in en bloc fashion posed no technical difficulty, laparoscopic lymph node dissection, particularly in right-sided cases, did in the early period. Laparoscopy was therefore available only for small renal cell carcinomas of less than 5 cm in diameter, which do not normally have lymph node involvement. A laparoscopic technique has recently been developed for the dissection of paraaortic lymph nodes in the right nephrectomy that includes the transection of the right lumbar vein and the medial retraction of the vena cava (38). Laparoscopy is now available for medium-sized, localized renal cell carcinomas of 5 to 8 cm in diameter.

McDougall and Clayman summarized their experience reporting on 17 patients who underwent laparoscopic radical nephrectomy and comparing them with 12 patients who underwent open radical nephrectomy (37). The laparoscopic procedure required significantly more operative time than the open procedure nephrectomy (6.9 vs. 2.2 hours), but it caused less post-operative pain, afforded an earlier discharge from the hospital (4.5 vs. 8.4 days), and an earlier full recovery (3.5 vs. 5.1 weeks). During the 4-year period from 1992 to 1996, there was no local recurrence or seeding at the port sites. They concluded that laparoscopic radical nephrectomy was a lengthy and demanding but beneficial procedure. We summarized our experience reporting on 25 patients who underwent laparoscopic radical nephrectomy, 11 of them via the transperitoneal and 14 via the retroperitoneal approach and comparing them with 17 patients who underwent open radical nephrectomy (38). Mean operative time for the laparoscopic procedures was 5.5 hours, 6 hours for the transperitoneal and 4.9 hours for the retroperitoneal approach, against only 3.6 hours for the open procedure. However, mean estimated blood loss was only 335 ml in the laparoscopic procedure, 397 ml in the transperitoneal and 285 ml in the retroperitoneal approach against 474 ml in the open procedure. Laparoscopic surgery had a

higher complication rate than open surgery (20% vs. 13%), but it afforded a shorter post-operative hospital stay (11 vs. 24 days) and an earlier full convalescence (3.3 vs. 9.1 weeks). During our 4-year follow-up period, there was no metastatic disease, no local recurrence and no seeding at the port sites. We concluded that laparoscopic radical nephrectomy was a recommendable procedure for removing small renal cell carcinomas. While the retroperitoneal approach should be taken when the patient has undergone previous, abdominal surgery or when the patient's condition makes a shorter operative time crucial. The transperitoneal approach is now been taken more often.

To date, over 200 laparoscopic radical nephrectomy have been performed worldwide, as shown in Table 4. Barrett and associates reported on 60 transperitoneal procedures (39). Their mean operative time was 2.5 hours, in 5 cases they converted to open surgery. Complications were minimal: 3 patients required transfusion another 3 had prolonged ileus, 1 patient had wound infection, and another 1 had a retraction injury. Mean post-operative hospital stay was only 4.4 days. There were no local recurrences, and only one patient had lung metastasis during up to 54 months of follow-up. Clayman and associates reported on a total of 47 procedures. Their mean operative time was 6 hours, mean estimated blood loss was 250 ml, in 3 cases they converted to open surgery, and the rate of complications was 10%. Mean post-operative hospital stay was also only 4.4 days, and mean time to full recovery was 3.5 weeks. There was no seeding at the port sites, no local recurrence, and only one patient had ureteral metastasis during up to 60 months of follow-up. We reported the long-term results of 62 procedures. There was no seeding at the port sites, no local recurrence, and only one patient had lung metastasis during up to 64 months of follow-up.

In summary, laparoscopic radical nephrectomy has numerous benefits to the patient with localized renal cell carcinoma. It provides a better long-term prognosis than open radical nephrectomy, but it is necessary to make a long-term prognosis for the original disease in the patient to ensure the efficacy of the procedure.

#### ACKNOWLEDGEMENT

We are very grateful to Professor Ralph V Clayman of the Washington University School of Medicine for his kind co-operation on this survey.

Table 4 Results of laparoscopic radical nephrectomy

	No. Pts.	Operating Time (hours)	Estimated Blood Loss (ml.)	Hospital Stay (days)	Convalescence (wks.)	Followup (mos.)	Prognosis (Dissemination/ Metastasis)
Taschda et al. 1995	18	4.6	—	8	—	—	(-/unknown)
Gill et al. 1995	11	5.5	471	—	—	—	(-/unknown)
Ono et al. 1997	60	5.4	325	10.4	3.3	1-64	(-/+*)
Clayman et al. 1997	47	6.0	105	4.5	3.5	1-63	(-/+**)
Barrett et al. 1997	60	2.5	—	4.4	—	1-54	(-/+*)

\* a case with lung metastasis, \*\* a case with ureteral metastasis



## REFERENCES

- 1) Wickman, J.E.A. and Kellet, M.J.: Percutaneous pyelolysis. *Eur. Urol.*, 9, 122–124 (1983).
- 2) Motola, J.A., Badlani, G.H. and Smith, A.D.: Results of 212 consecutive endopyelotomies.: An 8-years flow up. *J. Urol.*, 149, 453–456 (1993).
- 3) Kuenkel, M. and Korth, K.: Endopyelotomy: Long-term follow-up of 143 patients. *J. Endourol.*, 4, 109–116 (1990).
- 4) Tajima, A., Ueki, T., Moriyama, N., Kitamura, T., Aso, Y., Ohta, N., Suzuki, K. and Kawabe, K.: Clinical results of percutaneous pyeloplasty for congenital pelvic uretero junction stricture. *Jpn. J. Endourol. ESWL.*, 5, 60–62 (1992).
- 5) Ono, Y., Ohshima, S., Kinukawa, T., Sahashi, M. and Yamada, S.: Endopyeloureterotomy via a transpelvic extraureteral approach. *J. Urol.*, 147, 352–355 (1992).
- 6) Takeuchi, N., Ohshima, S., Ono, Y., Kinukawa, T., Katoh, N., Matsuura, O. and Yamada, S.: Endopyeloureterotomy via transpelvic extraureteral approach (abstract). *Min. Inv. Ther.*, 3, 22 (1994).
- 7) Maeda, S., Tamaki, M., Takeuchi, T., Sakai, S., Fujimoto, Y., Isogai, K., Yamamoto, N. and Kawada, Y.: Endoscopic and fluoroscopic pyeloureterotomy for ureteropelvic junction obstruction and ureteral stricture in children. *Jpn. J. Endourol. ESWL.*, 2, 182–184 (1993).
- 8) Kavoussi, L.R., Meretyk, S., Dierks, S.M., Bigg, S.W., Gup, D.I., Manley, C.B., Shapiro, E. and Clayman, R.V.: Endopyelotomy for secondary ureteropelvic junction obstruction in the pediatric population. *J. Urol.*, 145, 345–349 (1991).
- 9) Inglis, J.A. and Tolley, D.A.: Ureteroscopic pyelolysis for pelviureteric junction obstruction. *Br. J. Urol.*, 58, 250–252 (1986).
- 10) Clayman, R.V., Basler, J.W., Kavoussi, L. and Picus, D.D.: Uretero-nephroscopic endopyelotomy. *J. Urol.*, 144, 246–252 (1990).
- 11) Gallucci, M.G., Alpi, G., Ricciuti, G.P., Cassanell, A., Persechino, F. and Silverio, F.D.: Retrograde cold-knife endopyelotomy in secondary stenosis of the ureteropelvic junction. *J. Endourol.*, 5, 49–50 (1991).
- 12) Chowdhury, S.D. and Kenogbon, J.: Rigid ureteroscopic endopyelotomy without external drainage. *J. Endourol.*, 6, 357–360 (1992).
- 13) Meretyk, S., Albala, D.M., Clayman, R.V., Deratedt, J.D. and Kavoussi, L.R.: Endoureterotomy for treatment of ureteral strictures. *J. Urol.*, 147, 1502–1506 (1992).
- 14) Takeuchi, T., Nagatani, Y., Ishihara, S., Tada, K., Koide, T., Sugiyama, S., Sakai, S., Tamaki, M., Maeda, S., Nezasa, S., Kobayashi, S., Horie, M. and Kawada, Y.: Transurethral endoureteropyelotomy. *Jpn. J. Urol.*, 84, 873–878 (1993).
- 15) Yamada, S., Ono, Y., Ohshima, S. and Miyake, K.: Transurethral uretero-scopic ureterotomy assisted by a prior balloon dilation for relieving ureteral strictures. *J. Urol.*, 153, 1418–1421 (1995).
- 16) Chandhoke, P.S., Clayman, R.V., Stone, A.M., McDougall, E.M., Buelna, T., Hilal, N., Chang, M. and Stegwell, M.J.: Endopyelotomy and endoureterotomy with the acucise ureteral cutting balloon device: preliminary experience. *J. Endourol.*, 7, 45–51 (1993).
- 17) Clayman, R.V., Kavoussi, L.R., Soper, N.J., Dierks, S.M., Meretyk, S., Darcy, M.D., Roemer, F.D., Pingleton, E.D., Thomson, P.G. and Long, S.R.: Laparoscopic nephrectomy: initial case report. *J. Urol.*, 146, 278–282 (1991).
- 18) Kerbl, K., Clayman, R.V., McDougall, E.M., Gill, I.S., Wilson, B.S., Chandhoke, P.S., Albala, D.M. and Kavoussi, L.R.: Transperitoneal nephrectomy for benign disease of the kidney: a comparison of laparoscopic and open surgical techniques. *Urology*, 43, 607–613 (1994).
- 19) Fuchs, G.J., Gershman, A., Daird, R., Patel, A., Ehrlich, R. and Emthal, T.: Transabdominal uni- and bilateral laparoscopic nephrectomy. *J. Urol.*, 153, 356A (1995).
- 20) Coptcoat, M.J., Joyce, A.J., Popert, R., Eden, C. and Rassweiler, J.: Laparoscopic nephrectomy- the King's experience. *Min. Inv. Ther.*, suppl.1, 1, 67 (1992).
- 21) Rassweiler, J.J., Henkel, T.O., Stoch, C., Greschner, M., Becker, P., Preminger, G.M., Schulman, C.C., Fred, T. and Alken, P.: Retroperitoneal laparoscopic nephrectomy and other procedures in the upper retroperitoneum using a balloon dissection technique. *Eur. Urol.*, 25, 229–236 (1994).
- 22) Eraky, I., El-Kappany, H. and Ghoneim, A.: Laparoscopic nephrectomy: single center experience with 172 patients using transperitoneal and retroperitoneal approach. *J. Urol.*, 155, 661A (1996).
- 23) Gaur, D.D.: Laparoscopic operative retroperitoneoscopy: use of a new device. *J. Urol.*, 148, 1137–1139 (1992).
- 24) Katoh, N., Ono, Y., Yamada, S., Kinukawa, T., Sahashi, M., Matsuura, O., Hirabayashi, S., Hatano, Y., Sakakibara, T. and Ohshima, S.: Review of laparoscopic nephrectomy in 26 patients. *Jpn. J. Endourol. ESWL.*, 6, 129–132 (1993).

- 25) Terachi, T., Matsuda, T., Kawakita, M., Mikami, O., Horii, Y., Ogawa, K., Takeuchi, H., Komatsu, Y. and Yoshida, O.: Laparoscopic nephrectomy: A report of 13 cases. *Jpn. Endourol. ESWL.*, 6, 133–137 (1993).
- 26) McDougall, E.M., Clayman, R.V. and Fadden, P.T.: Retroperitoneoscopy: the Washington University Medical School experience. *Urology*, 43, 446–452 (1994).
- 27) Ono, Y., Katoh, N., Kinukawa, T., Matsuura, O. and Ohshima, S.: Laparoscopic nephrectomy via the retroperitoneal approach. *J. Urol.*, 156, 1101–1104 (1996).
- 28) Go, H., Takeda, M., Takahashi, H., Imai, T., Tsutsui, T., Mizusawa, T., Nishiyama, T., Morishita, H., Nakajima, Y. and Sato, S.: Laparoscopic adrenalectomy for primary aldosteronism: a new operative method. *J. Laparoendosc. Surg.*, 3, 455–459 (1993).
- 29) Gagner, M., Lacroix, A. and Bolte, E.: Laparoscopic adrenalectomy in Cushing's syndrome and pheochromocytoma. *New Engl. J. Med.*, 327, 1033 (1992).
- 30) Higashihara, E., Tanaka, Y., Horie, S., Aruga, S., Nutahara, K., Minowada, S. and Aso, Y.: Laparoscopic adrenalectomy: the initial 3 cases. *J. Urol.*, 149, 973–976 (1993).
- 31) Suzuki, K., Ushiyama, T., Kageyama, S., Ihara, H. and Fujita, K.: Complications of laparoscopic adrenalectomy in 60 patients treated by the same surgeon. *J. Urol. suppl*, 157, 211 (1997).
- 32) Terachi, T., Matsuda, T., Terai, A., Ogawa, O., Kakehi, Y., Kawakita, M., Shichiri, Y., Mikami, O., Takeuchi, H., Okada, Y. and Yoshida, O.: Transperitoneal laparoscopic adrenalectomy experience in 100 patients. *J. Endourol.*, 11, 361–365 (1997).
- 33) Guazzoni, G.A., Montorsi, F., Bocciardi, A., et al: Transperitoneal laparoscopic versus open adrenalectomy for benign hyperfunctioning adrenal tumors: a comparative study. *J. Urol.*, 153, 1597–1600 (1995).
- 34) Ono, Y., Sahashi, M., Yamada, S. and Ohshima, S.: Laparoscopic nephrectomy without morcellation for renal cell carcinoma: Report of initial 2 cases. *J. Urol.*, 150, 1222–1224 (1993).
- 35) Ono, Y., Katoh, N., Kinukawa, T., Sahashi, M. and Ohshima, S.: Laparoscopic nephrectomy, radical nephrectomy and adrenalectomy: Nagoya experience. *J. Urol.*, 152, 1962–1966 (1994).
- 36) Kinukawa, T., Hattori, R., Ono, Y., Katoh, N., Hirabayashi, S. and Ohshima, S.: Laparoscopic radical nephrectomy: analysis of 15 cases and preliminary report of the retroperitoneal approach. *Jpn. Endourol. ESWL.*, 8, 88–191 (1995).
- 37) McDougall, E.M., Clayman, R.V. and Elashry, O.M.: Laparoscopic radical nephrectomy for renal tumor: The Washington University experience. *J. Urol.*, 155, 1180–1185 (1996).
- 38) Ono, Y., Katoh, N., Kinukawa, T., Matsuura, O. and Ohshima, S.: Laparoscopic radical nephrectomy: The Nagoya experience. *J. Urol.*, 158, 719–723 (1997).
- 39) Barrett, P.H., Fentie, D.D. and Taranger, L.: Laparoscopic radical nephrectomy with morcellation. *J. Endourol.*, 11, S128 (1997).