

FOCAL MACULAR ELECTRORETINOGRAPHY

YOZO MIYAKE

Department of Ophthalmology, Nagoya University School of Medicine

ABSTRACT

Over the last two decades, many attempts have been made to record electroretinograms (ERG) of human macula by several investigators. However, previous ERG responses were not informative enough, because each ERG component could not be evaluated independently. However, we have developed a new system for recording focal macular ERG where we can evaluate all ERG components. This paper reviews what we have found using our system in terms of the macular physiology and pathogenesis in human eyes.

Key Words: macula, focal ERG, macular oscillatory potentials, macular physiology

INTRODUCTION

When light falls on the retina, an alteration in electrical potential occurs, the record of which is called an electroretinogram (ERG).¹⁾ The ERG consists of a cornea-negative a-wave, a cornea-positive b-wave, and under a photopic condition, a small d-wave or off-effect coincident with cessation of illumination.²⁾ Oscillatory potentials (OPS) are wavelets superimposed on the ascending slope of the ERG.³⁾ Since the origin of each component is different, the comparative measurement of these components indicates which layer of the retina is disturbed.

Although many studies have dealt with the physiological properties and clinical value of an ERG, until now they have been evaluated using an ERG that is recorded with full-field stimulus over the entire retina (full-field ERG). The macula is the most important small area of the retina in visual function. However, macular function cannot be evaluated by a full-field ERG. The total cone population in the human retina is approximately 6.8×10^6 ; the number of cones in the macula (central 10 degrees) is maximally 4.4×10^5 ; therefore the central macula contains at most 7% of the total retinal cone population. This fact could explain the inability of the full-field ERG system to detect abnormalities confined to the macula.

Many attempts have been made to record the focal macular ERG in the past with some success.⁴⁻⁹⁾ However, the previous responses were not informative enough, because it was technically difficult to record all components of the ERG from the human macula.

We have successfully recorded not only a-waves, b-waves, and, d-waves, but also OPS in human focal macular ERGs.¹⁰⁻¹²⁾ This paper reviews the method with which many new aspects of macular physiology^{11,13,14)} and pathophysiology¹⁵⁻²⁸⁾ were detected.

FOCAL MACULAR ERG UNDER FUNDUS MONITOR

One difficulty in recording the cone ERG of the small macula at the cornea is that scattered light from a focal test stimulus can evoke a response from many receptors outside the macula, and therefore the macular ERG cannot be seen in isolation. Furthermore, the macula contains as many rods as cones, and the macular rod ERG can thereby obscure the contribution from the macular cones.

To solve these problems and to get a focal macular cone ERG, one should use computer averaging with a small test stimulus, superimposed on a large background sufficient to eliminate the rod contribution and scattered light effect from extramacular area, as shown in Figure 1.

Another difficulty in recording the focal macular ERG is how to stimulate the exact location of the macula. Most patients with a macular problem have a central scotoma. If we ask the patient to see the stimulus light, they may see it with the extra macular area where the retina is intact. We found that monitoring the fundus during recording is essential to stimulate the exact locus of the macula. As shown in Figure 2, we have developed a focal macular ERG system under the fundus monitor, using an infrared television fundus camera. Figure 3 shows the ERG and Visual Evoked Response (VER) recorded simultaneously with focal stimulation of the macula and paramacular area in a normal subject (upper) and the percent amplitudes in variable areas from four normal subjects (lower). When the spot was on the macula, definite ERG and VER were recordable. As the spot deviated from the fovea, the amplitude of both the ERG and VER decreased, and when the spot was on the optic disc, no response was obtained. The subject did not see a stimulus spot when it was on the disc, indicating that responses obtained by macular and paramacular stimulation were due to focal excitation of the retina and not to stray light effects.

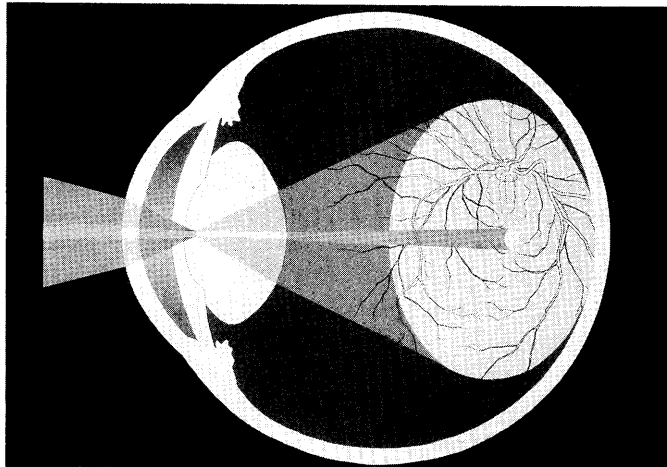


Figure 1. The schema of optical arrangement of focal macular ERG. A small test stimulus is superimposed on a large background illumination.

FOCAL MACULAR ELECTRORETINOGRAPHY

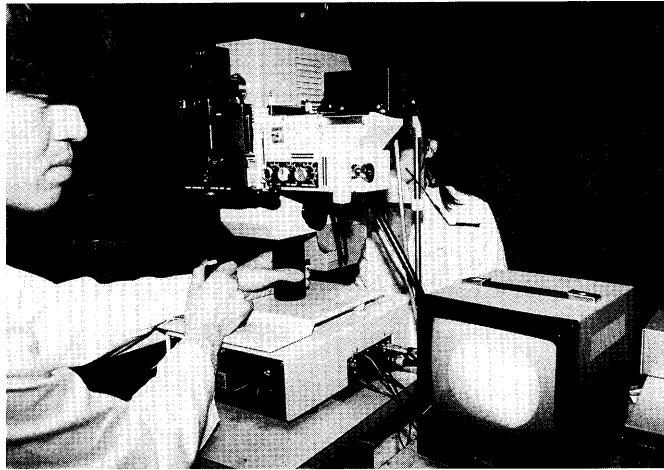


Figure 2. The recording system of focal macular ERG under the fundus monitor through the infrared television fundus camera.

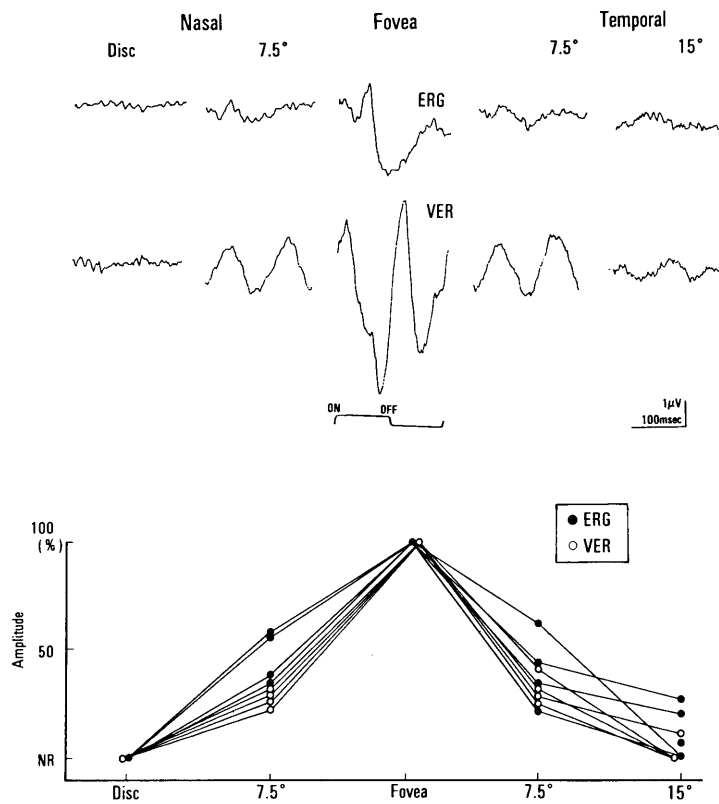


Figure 3. ERG and VER recorded simultaneously with focal stimulation of the macula and paramacular area in a normal subject (upper) and the percent amplitudes in variable areas from four normal subjects (lower).

RECORDING EACH COMPONENT OF ERG

By improving the signal-to-noise ratio of our previously reported system for recording a focal macular ERG, we have successfully recorded several components in the human macular region.^{10,11)} Figure 4 shows components of a focal macular ERG recorded with a 10 degree spot in a normal subject. The a-wave, b-wave, OPS and d (off)-wave were easily recorded.

Since the retinal origin is considered to be in the photoreceptors (a-wave),²⁹⁾ depolarizing bipolar cells and Muller cells (b-wave),³⁰⁾ amacrine cells and inhibitory feed back synaptic circuits (OPS),³¹⁾ and hyperpolarizing bipolar cells (d-wave),³²⁾ the comparative measurement of these components provides a layer-by-layer functional analysis of the macula.

MACULAR OSCILLATORY POTENTIALS

OPS are wavelets superimposed on the ascending slope of a conventional ERG. OPS are seen as a series of three or four rhythmic wavelets having almost equal amplitude and an inter-peak interval of about 6.5 msec in humans. OPS have clinical values in the assessment of retinal function. In the early stage of diabetic retinopathy for example, the a-wave and b-waves of an ERG may be of normal amplitude, whereas the OPS may be selectively abnormal.³³⁾ In one kind of X-linked congenital stationary night blindness, OPS are absent or have extremely reduced amplitude,³⁴⁾ and the female carrier may show a reduction in the amplitude of her OPS, while other components of her ERG remain normal.³⁵⁾ This selective abnormality of OPS is considered to be indirect evidence that OPS are generated independently from a-wave and b-waves. The site for OPS generation is not yet known, but experimental evidence indicates that OPS reflect the activity of amacrine cells and inhibitory feedback synaptic circuits within the retina.³¹⁾

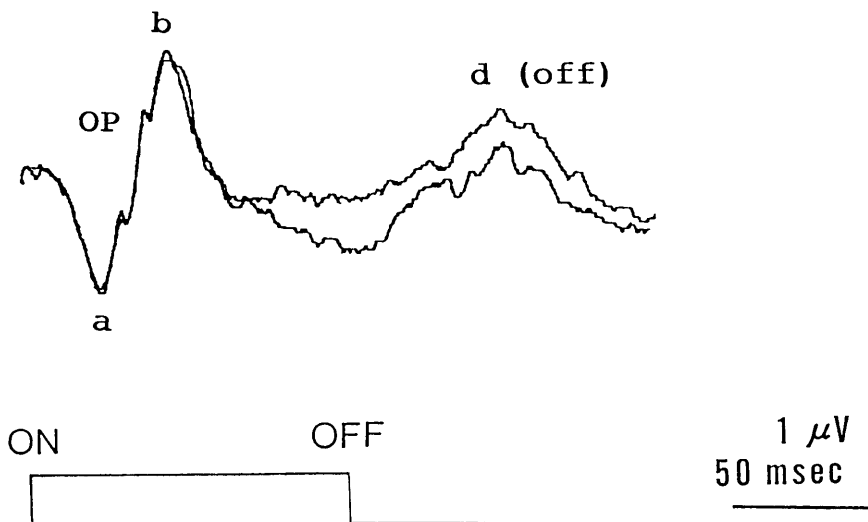


Figure 4. Focal macular ERG recorded with a 10 degree spot in a normal subject, showing a-wave, b-wave, oscillatory potentials (OPS) and d(off)-wave. A bottom tracing indicates a photocell response.

FOCAL MACULAR ELECTRORETINOGRAPHY

Until now, OPS in humans have been evaluated as components of a total ERG recorded with full-field stimulus over the entire retina and attempts to record OPS in the human macular region by using a focal stimulus light have not been reported. To our knowledge, these are the first recordings that isolate macular OPS from the total ERG.^{11,14)}

We studied the functional properties of macular OPS. Human macular OPS consist of 3 to 4 wavelets (mean peak interval, 6.5 msec).^{11,14)} The area density of each component is analyzed by comparing the amplitude and the stimulating size around the macular area. The distribution of OPS in relation to those in a-waves and b-waves is relatively sparse in the fovea, and becomes relatively more dense than those of a-waves and b-waves from the fovea toward the parafovea, and even more strikingly so toward the perifovea.^{11,14)} There was no statistical difference in the amplitude of both a-waves and b-waves between the nasal and temporal macular region.¹³⁾ However, the amplitude of OPS in the temporal macular region was significantly larger than that in the nasal macular region.¹³⁾

CLINICAL APPLICATIONS

During the past 15 years, we have recorded the focal macular ERGs of many patients with variable macular diseases, and found that the focal macular ERG is an extremely important tool for diagnosis,^{17,26)} analysis of pathogenesis,¹⁵⁻²⁵⁾ prediction of prognosis,^{27,28)} and evaluation of macular surgeries.^{27,28)}

In some macular diseases, such as diabetic maculopathy,¹⁴⁾ cystoid macular edema²⁴⁾ or the convalescent stage of idiopathic central serous chorioretinopathy,¹⁶⁾ the macular OPS were selectively reduced, leaving the a-wave and b-wave intact. We found that macular OPS can be a sensitive indicator of macular function in several macular diseases.

ACKNOWLEDGEMENTS

This work was supported by Grants-in-Aid Nos.62480362, 02670784, 04454440, 06454496, and 085457462 from the Japanese Ministry of Education, Science and Culture.

REFERENCES

- 1) Dewar, J.: The physiological action of light. *Nature*, 15, 433–435 (1877).
- 2) Granit, R.: The components of the retinal action potential in mammals and their relation to the discharge in the optic nerve. *J. Physiol. (Lond.)*, 77, 207–212 (1933).
- 3) Cobb, W.A. and Morton, H.B.: A new component of the human electroretinogram. *J. Physiol. (Lond.)*, 123, 36–37 (1954).
- 4) Biersdorf, W.R. and Diller, D.A.: Local electroretinogram in macular degeneration. *Am. J. Ophthalmol.*, 68, 296–303 (1969).
- 5) Sandberg, M.A., Effron, M.H. and Berson, E.L.: Foveal cone electroretinograms in retinitis pigmentosa with reduced penetrance. *Invest. Ophthalmol. Vis. Sci.*, 17, 1096–1101 (1978).
- 6) Aiba, T.S., Alpern, M. and Maaseidvaag, F.: The electroretinogram evoked by the excitation of human foveal cones. *J. Physiol.*, 189, 43–62 (1967).
- 7) Jacobson, J.H., Kawasaki, K. and Hirose, T.: The human electroretinogram and occipital potential in response to focal illumination of the retina. *Invest. Ophthalmol.*, 8, 545–556 (1969).
- 8) Nagata, M. and Honda, Y.: Studies on the local electric response of the human retina. 1. An instrument for stimulating local retinal areas in various photopic conditions. *Acta. Soc. Ophthalm. Jpn.*, 74, 388–394 (1970).

- 9) Hirose, T., Miyake, Y. and Hara, A.: Simultaneous recording of electroretinogram and visual evoked response. Focal stimulation under direct observation. *Arch. Ophthalmol.*, 95, 1205–1208 (1977).
- 10) Miyake, Y., Yanagida, K., Kondo, T., Yagasaki, K. and Ota, I.: Subjective scotometry and recording of local electroretinogram and visual evoked response. System with television monitor of the fundus. *Jpn. J. Ophthalmol.*, 25, 438–448 (1981).
- 11) Miyake, Y., Shiroyama, N., Ota, I. and Horiguchi, M.: Oscillatory potentials in electroretinograms of the human macular region. *Invest. Ophthalmol. Vis. Sci.*, 29, 1631–1635 (1988).
- 12) Miyake, Y.: Layer-by-layer analysis of macular diseases with objectively measured visual functions. *Jpn. J. Ophthalmol.*, 34, 225–238 (1990).
- 13) Miyake, Y., Shiroyama, N., Horiguchi, M. and Ota, I.: Asymmetry of focal ERG in human macular region. *Invest. Ophthalmol. Vis. Sci.*, 30, 1743–1749 (1989).
- 14) Miyake, Y.: Macular oscillatory potentials in humans. *Doc. Ophthalmol.*, 75, 111–124 (1990).
- 15) Miyake, Y. and Awaya, S.: Stimulus deprivation amblyopia. Simultaneous recording of local macular electroretinogram and visual evoked response. *Arch. Ophthalmol.*, 102, 998–1003 (1984).
- 16) Miyake, Y., Shiroyama, N., Ota, I. and Horiguchi, M.: Local macular electroretinographic responses in idiopathic central serous chorioretinopathy. *Am. J. Ophthalmol.*, 106, 546–550 (1988).
- 17) Miyake, Y., Ichikawa, K., Shiose, Y. and Kawase, Y.: Hereditary macular dystrophy without visible fundus abnormality. *Am. J. Ophthalmol.*, 108, 292–299 (1989).
- 18) Miyake, Y., Shiroyama, N., Horiguchi, M., Saito, A. and Yagasaki, K.: Bull's eye maculopathy and negative electroretinogram. *Retina*, 9, 210–215 (1989).
- 19) Weleber, R.G. and Miyake, Y.: Familial optic atrophy with negative electroretinogram. *Arch. Ophthalmol.*, 110, 640–645 (1992).
- 20) Horiguchi, M. and Miyake, Y.: Electroretinographic analysis of macular cone and rod systems in macular disease. *Chibret. Int. J. Ophthalmol.*, 9, 25–35 (1992).
- 21) Miyake, Y., Shiroyama, N., Ota, I. and Horiguchi, M.: Focal macular electroretinogram in X-linked congenital retinoschisis. *Invest. Ophthalmol. Vis. Sci.*, 34, 512–515 (1993).
- 22) Horiguchi, M., Miyake, Y., Nakamura, M. and Fujii, Y.: Focal electroretinogram and visual field defect in multiple evanescent white dot syndrome. *Br. J. Ophthalmol.*, 77, 452–455 (1993).
- 23) Miyake, Y., Awaya, S., Takahashi, H., Tomita, N. and Hirano, K.: Hyperbaric oxygen and acetazolamide improve visual acuity in patients with cystoid macular edema by different mechanisms. *Arch. Ophthalmol.*, 111, 1605–1606 (1993).
- 24) Miyake, Y., Miyake, K. and Shiroyama, N.: Classification of aphakic cystoid macular edema with focal macular electroretinograms. *Am. J. Ophthalmol.*, 116, 576–583 (1993).
- 25) Kondo, M., Miyake, Y., Horiguchi, M., Suzuki, S. and Tanikawa, A.: Clinical evaluation of multifocal electroretinogram. *Invest. Ophthalmol. Vis. Sci.*, 36, 2146–2150 (1995).
- 26) Miyake, Y., Horiguchi, M., Tomita, N., Kondo, M., Tanikawa, A., Takahashi, H., Suzuki, S. and Terasaki, H.: Occult macular dystrophy. *Am. J. Ophthalmol.*, 122, 644–653 (1996).
- 27) Terasaki, H., Miyake, Y., Kondo, M. and Tanikawa, A.: Focal macular electroretinogram before and after drainage of macular subretinal hemorrhage. *Am. J. Ophthalmol.*, 123, 207–211 (1997).
- 28) Terasaki, H., Miyake, Y., Tanikawa, A., Kondo, M., Ito, Y. and Horiguchi, M.: Focal macular electroretinograms before and after successful macular hole surgery. *Am. J. Ophthalmol.*, 125, 2074–213 (1998).
- 29) Brown, K.T.: The electroretinogram: Its components and their origin. *Vision Res.*, 8, 633–677 (1968).
- 30) Newman, E.A.: Current source density analysis of the b-wave of the frog retina. *Am. J. Neurophysiol.*, 43, 1335–1340 (1980).
- 31) Haynan, N., Wachtmeister, L. and van Norren, D.: Origin of the oscillatory potentials in the primate retina. *Vision Res.*, 10, 1365–1373 (1985).
- 32) Sieving, P.A.: Photopic on- and off-pathway abnormalities in retinal dystrophies. *Trans. Am. Ophthalmol. Soc.*, 91, 701–773 (1993).
- 33) Yonemura, D., Aoki, T. and Tsuzuki, K.: Electroretinogram in diabetic retinopathy. *Arch. Ophthalmol.*, 68, 19–24 (1962).
- 34) Miyake, Y., Yagasaki, K., Horiguchi, M., Kawase, Y. and Kanda, T.: Congenital stationary night blindness with negative electroretinogram: A new classification. *Arch. Ophthalmol.*, 104, 1013–1020 (1986).
- 35) Miyake, Y. and Kawase, Y.: Reduced amplitude of oscillatory potentials in female carriers of x-linked recessive congenital stationary night blindness. *Am. J. Ophthalmol.*, 98, 208–213 (1984).